



JOHN MOORE HERITAGE SERVICES

ARCHAEOLOGICAL INVESTIGATIONS

AT

ST MARY'S CHURCH, WARGRAVE,

BERKSHIRE

NGR SU 78280 78485

JULY 2019

PREPARED BY Stephanie N. Duensing & Ceridwen Boston
with contributions from Simona Denis Emily Edwards
and Rebecca Devaney

ILLUSTRATION BY Alessandro Guaggenti

EDITED BY John Moore

AUTHORISED BY John Moore

FIELDWORK DATE 19 January – 12 March 2018

REPORT ISSUED 18rd July 2019

ENQUIRES TO John Moore Heritage Services
Pasture Farmhouse
Boarstall
Aylesbury
HP18 9UR

Tel: 01865 358300
Email: info@jmheritageservices.co.uk

JMHS Project No: 3761
OASIS No: jm12345678
Site Code: WASR 17
Archive Location The archive currently is maintained by John Moore
Heritage Services and will be transferred to a suitable
repository when one is available

CONTENTS

	Page
SUMMARY	v
1 INTRODUCTION	1
1.1 Site Location	1
1.2 Planning Background	1
1.3 Archaeological Background	1
2 AIMS OF THE INVESTIGATION	5
3 STRATEGY	5
3.1 Research Design	5
3.2 Methodology	6
4 RESULTS	6
4.1 Fieldwork	6
5 FINDS	30
5.1 Human Remains	30
5.2 Coffins and Coffin Furniture	33
5.3 Personal Objects	34
5.4 The Pottery	36
5.5 The Flint	37
5.6 Miscellaneous	38
6 DISCUSSION	40
7 ARCHIVE	43
8 BIBLIOGRAPHY	44
APPENDIX 1: Skeleton Inventory	47
APPENDIX 2: Coffin Furniture Report	106
APPENDIX 3: Coffins Catalogue	119
APPENDIX 4: Osteological Catalogue	124

FIGURES, TABLES AND PLATES

Figure 1. Site Location	2
Figure 2. Foundation Pit, Phases 1-2	8
Figure 3. Foundation Pit 2, Phases 1-6	9
Figure 4. Foundation Pit 3, Phase 1-2	11
Figure 5. Foundation Pit 3, phases 3-5	12
Figure 6. Foundation Pit 3, Phase 6 and Foundation Pit 5	13
Figure 7. Sections 3.01, 4.01-4.02, 5.01 and 6.01-6.02	14
Figure 8. Foundation Pit 6, Phase 1-6	16

Figure 9. Foundation Pit 8, phase 1; (below) Foundation Pit 9, phases 1-4	17
Figure 10. Foundation Pit 10, Phases 1-4	19
Figure 11. Foundation Pit 10, Phases 5-8	20
Figure 12. Foundation Pit 11, phases 1-2	21
Figure 13. Foundation Pit 12. Phases 1-2	22
Figure 14. Foundation Pit 12. Phases 3-4	23
Figure 15. Soakaway (FP13), phases 1-3	25
Figure 16. Soakaway (FP13), phases 4-5	26
Figure 17. Soakaway (FP13), phases 6-7	27
Figure 18. Soakaway (FP13), phases 8-9	28
Figure 19. Distribution chart of burials and phasing by Test Pit	40
Figure 20. Burials recorded in the St Mary's Church records by decade	49
Figure 21. Number of male and of female burials in Wargrave parish by decade, calculated from burial registers of St Mary's Church, Wantage	54
Figure 22. Age and sex distribution of a representative sample of entries in the St Mary's Church burial register	56
Figure 23. Age and sex distribution of the Wargrave assemblage	64
Figure 24. True prevalence of Schmorl's nodes	97
Table 1. Personal objects occurrence by burial	35
Table 2. Prehistoric pottery occurrence by context and type	36
Table 3. Medieval and Post Medieval pottery occurrence by context and type	37
Table 4. Summary of flint by type and context	38
Table 5. Clay tobacco pipe occurrence by context	39
Table 6. Ceramic Building Material occurrence by context and type	39
Table 7. Number and ratio of males and females of all ages by century; calculated from the burial registers of St Mary's Church, Wargrave	54
Table 8. Proportion of infant burials to total burials in Wargrave by decade	55
Table 9. Age and sex distribution of burials in St Mary's churchyard in the 19 th century	56
Table 10. Age categories used in this study	59
Table 11. Preservation and completeness of St Mary's Wargrave assemblage	61
Table 12. Distribution of sex and coffin type.	62
Table 13. Age and sex distribution in the Wargrave skeletal assemblage	63
Table 14. : Comparative adult male and female stature estimates from later post-medieval skeletal assemblages in England	66
Table 15. True prevalence of non-metric traits and anatomical variants in the part of the Wargrave assemblage	67
Table 16. The true prevalence of dental disease in the permanent dentition of the St Mary's Church, Wargrave, assemblage and other skeletal assemblages;	72
Table 17. Fractures present in the Wargrave assemblage	77
Table 18. True prevalence of fractures in the Wargrave assemblage	77
Table 19. Periostitis in the Wargrave assemblage	83
Table 20. Pathological lesions that may be associated with healed scurvy in the Wargrave assemblage	90
Table 21. Extraspinous degenerative joint disease in the major joints and frequency of eburnation (osteoarthritis) in the Wargrave assemblage	96
Table 22. True prevalence of Schmorl's nodes	98
Table 23. Coffin remains by burial	115

Plate 1. External view of the North Aisle, St. Mary's Church, Wargrave	29
Plate 2. Interior view of St. Mary's Church, Wargrave	29
Plate 3. Anglo-Norman Baptismal Font, St. Mary's Church, Wargrave	30
Plate 4. Selected dental pathological lesions in the Wargrave assemblage	73
Plate 5. Selected traumatic lesions on skeletons of the Wargrave assemblage	81
Plate 6. Selected cases of infection in the Wargrave assemblage	85
Plate 7. Selected metabolic pathological lesions in the Wargrave assemblage	92
Plate 8. Selected joint disease in the Wargrave assemblage	96
Plate 9. Upholstery studs	112
Plate 10. Wargrave grips type WASR1 and WASR7	112
Plate 11. Wargrave grip type WASR4	113
Plate 12. Wargrave grip type WASR5	113
Plate 13. Pocket watch and seal	114
Plate 14. Tombac buttons	114

SUMMARY

John Moore Heritage Services carried out a programme of archaeological works for the foundation work to the north of St. Mary's church Wargrave, Wokingham, Berkshire (NGR SU 78280 78485). It resulted in the exhumation of a minimum of 89 articulated individual burials. These yielded a great deal of insight into the daily lives of the members of the church over a period of roughly 1,000 years. Positive dating was only possible on roughly 25% of the individual burials we encountered, the date range of occupation at this site spans from the prehistoric use of the area up to the 1980s. The phasing for the excavated human remains was able to be broadly identified to fall into three broad categories spanning c.1100-1900 AD. Architectural phasing from the rebuilding of the church after the 1914 fire was also recorded.

1 INTRODUCTION

1.1 Site Location (Figure 1)

St. Mary's Church is located on the south-western outskirts of the present village of Wargrave, at National Grid Reference (NGR) SU 78280 78485, in the Borough of Wokingham. The northern wall of the churchyard forms the boundary with Wargrave Court, while the southern wall runs to the rear of properties fronting onto Station Road. The drive leading to Herons Creek and Herons Court follows part of the western edge of the churchyard, while the lychgate in the east wall opens onto Mill Green. The proposed extension is on the northern side of the church within the churchyard.

St. Mary's is situated to the south of the Thames and to the east of the Loddon, some 500 metres from the confluence between the two rivers. The church occupies low lying ground in the valley bottom at approximately 35 metres above Ordnance Datum. Wargrave lies towards the western end of the London Basin which is infilled with a series of Palaeogene deposits, laid down between 65 and 23 million years before present (Sumbler 1996). These include the Reading Beds and the London Clay which outcrop to the east of the village (Monckton 1903: 44). St. Mary's is located on the Valley Gravel (Geological Survey of England and Wales Map Sheet 268). This is composed of a mixture of gravel and sands of fluvial origin, deposited during the Pleistocene epoch (1.64 million to 10,000 years before present).

1.2 Planning Background

Planning permission for erection of a single storey self-contained annexe at St Mary's Church, Wargrave was granted by Wokingham District Council (152323). Due to the archaeological and historical importance of the surrounding area a condition was attached to the permission:

9. No development shall take place within the site until the applicant, or their agents or their successors in title, has secured and implemented a programme of archaeological work (which may comprise more than one phase of work) in accordance with a written scheme of investigation, which has been submitted to and approved in writing by the Local Planning Authority. The development shall only take place in accordance with the detailed scheme approved pursuant to this condition.

Reason: To ensure that any archaeological remains or burials within the site are adequately investigated and recorded or preserved in situ in the interest of protecting the archaeological heritage of the borough.

1.3 Archaeological Background

Berkshire Archaeological Services carried out a desk-based assessment and subsequent archaeological evaluation of the proposal site in 2002 (Entwistle 2002). The following information has been taken from these reports, supplemented by additional data entered into the Berkshire HER since this date.

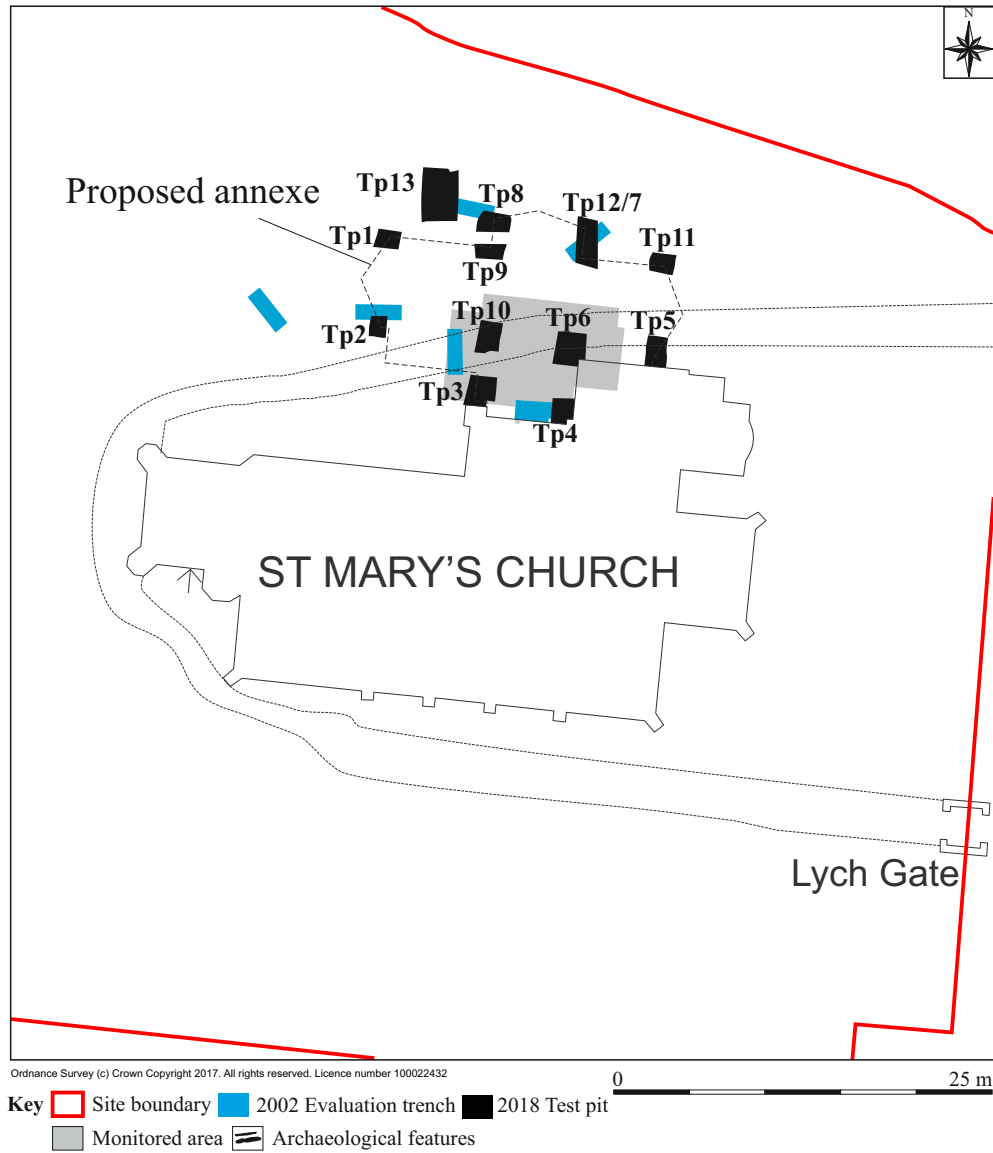
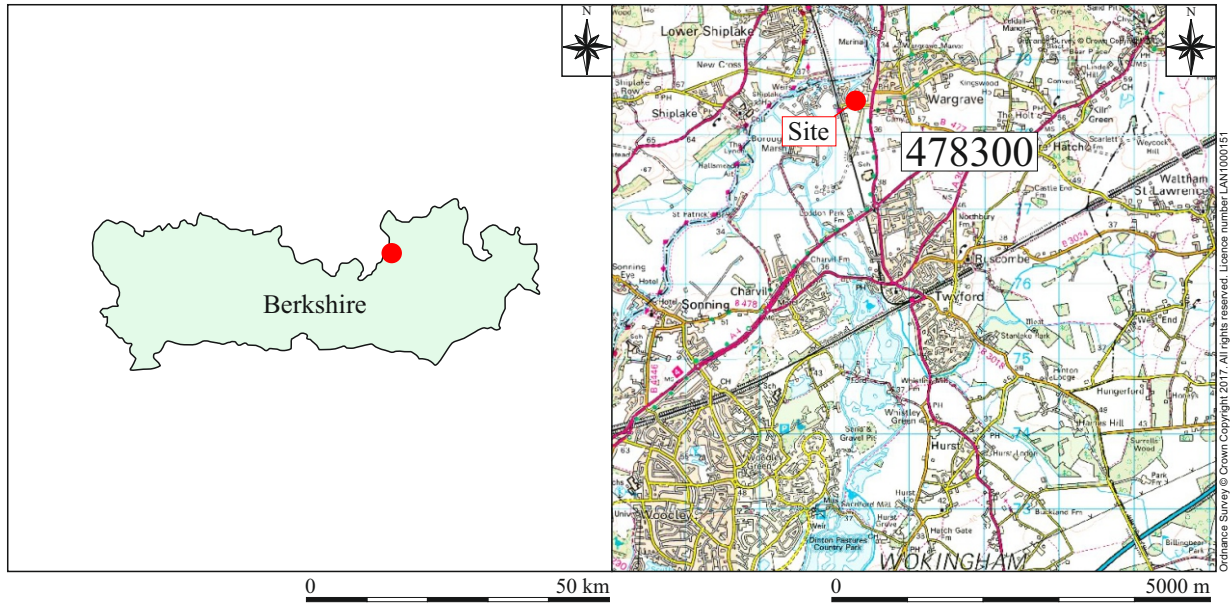


Figure 1: Site location

Prehistoric

The earliest activity within the vicinity of St. Mary's Church comes from two scatters of prehistoric worked flint, identified during the Loddon Valley Survey (MWK6764: SU 78062 78008). The first extends over a large area to the west of the railway, approximately 250 metres to the south-west of the church; while the second occupies land near Sheeplands Farm, some 550 metres south-east of St. Mary's. The earliest flint work dates to the Mesolithic period (10,000 to 4000 BC) while some of the assemblage was also considered early Neolithic (4000 to 3000 BC). The bulk of the flint work, however, is thought to be of late Neolithic or earlier Bronze Age date.

A crop mark likely to represent a ring ditch has also been observed in the same field. Alternatively this crop mark might be part of the ditch of an enclosure, possibly defining an area of settlement (MWK2053: SU 78048 78203).

The flint scatter near Sheeplands Farm only yielded two diagnostic pieces, including a broken early Neolithic leaf-shaped arrowhead and a blade of a type with a long history of production between the early Mesolithic and the early Bronze Age. This is part of a much larger flint scatter extending to the south of the pumping station which has been tentatively assigned to the later Bronze Age.

Further prehistoric finds comprise isolated artefacts dredged from the River Thames. These include a Mesolithic tranchet axe (MWK8738: SU 78000 78700); a Bronze Age axe (MWK8743: SU 78000 78700) and a possible prehistoric loom or net weight (MWK8739: SU 78000 78700).

There are no early Iron Age finds from the area close to St. Mary's. A middle to late Iron Age sword was recovered from the Thames to the north-west of the church (MWK8744: SU 78000 78700). This find-spot is approximately 200 meters to the west of a point near Wyatt's Boatyard, where a late Iron Age or early Roman pottery vessel was discovered (MWK8854: SU 78200 78700)

Roman

A Roman road runs on a north-east to south-west axis passing approximately 100 metres to the east of the church across Mill Green, where the agger was observed during a watching brief (MWK4810: SU 78410 78500). The earthwork is confined to the north-eastern corner of Mill Green where it is well preserved for a distance of approximately 40 metres.

Evidence of a contemporary settlement was found during the Loddon Valley survey (MWK6818: SU 78062 78007). One hundred sherds of Roman pottery were produced, with a marked concentration in a two hectare area in the south-east corner of the field, approximately 600 metres to the south-west of the church.

Scattered Roman sherds also came from land to the north of Sheeplands Farm between 300 and 500 metres south-east of St. Mary's; while two coins were found not far from the Roman road, in locations approximately 150 and 250 metres to the north-east of the church (MWK8864: SU 78450 78580; MWK8865: SU 78500 78600).

Early Medieval

The earliest evidence for Saxon activity close to the church coincides with the Roman pottery concentration and crop-mark complex, in the field to the west of the railway line. Eleven sherds of early to mid Saxon pottery were recovered from the south-east corner of this field (MWK6818: SU 78062 78007). It is probable that this material denotes subsequent Saxon occupation within the Roman settlement.

The earliest documentary evidence for occupation at Wargrave is confined to a charter of Edward the Confessor (AD 1061 to 1065) confirming an earlier grant of the manor to the Old Minster of Winchester. However, there is some doubt about the authenticity of this document, since the Domesday Survey of AD 1086 records Wargrave as a royal manor held by Queen Edith during the reign of Edward the Confessor (MWK1257: SU 78380 78464).

Medieval

There is no documentary evidence for a Saxon church at Wargrave, although there is a Saxon font in the south-east corner of the churchyard near the lychgate. None of the surviving features within St. Mary's are demonstrably earlier than the twelfth century AD. The church was burnt down in 1914, with the exception of the west tower of 1635, the walls and north doorway (DRM2299). The structure is of flint with stone dressings, a brick tower and gabled tiled roof. The nave comprises 5 bays, with chancel, north transept and organ chamber, south arcade and aisle with chapel.

During the 12th century the manor of Wargrave passed between church to king (1194) and back to church (1199), being retained by the church until the 16th century. A market charter was obtained in 1218 with borough status, possibly indicating the establishment of a new planned town (MWK1258: SU 78550 78600). The medieval settlement of Wargrave is primarily located to the north east of St Marys. Several domestic buildings have their origin in the medieval period; these include three grade II listed timber hall houses of 14th and 15th century date (DRM2287, DRM2150, and DRM2430).

A small linear gully was recorded during a watching brief at Ferry Lane (MRM16544: SU 78435 78641). One sherd of 11th – 14th century pottery was recovered, suggesting a possible medieval date. As the gully lies parallel to Ferry Lane, it may represent a property boundary.

Post Medieval

Post Medieval archaeology within the area is focused upon Wargrave, and predominantly comprises a series of extant buildings. Pertinent to the application (within the churchyard) are two grade II listed tombs; one metre from the north wall of the tower is the 18th century tomb of the Nind family (DRM2158) while one metre from the east wall of the south aisle is the 18th century tomb of the Abear family (DRM2159).

Geophysical survey and archaeological evaluation

A resistivity survey was undertaken across the proposal area; anomalies considered to be archaeologically significant were identified, including a possible building, infilled pit and several linear anomalies. The latter were considered to relate to linear features associated with the earthworks on Mill Green, the proposed location of the Early Medieval settlement of Wargrave.

An archaeological evaluation was undertaken in 2002; six trenches were positioned in order to investigate the anomalies identified through geophysical survey.

The results of the evaluation revealed a sequence of intercutting burials overlain by topsoil; an average of four burials were identified within each evaluation trench. On the basis of stratigraphy and coffin furniture these burials were dated to the 18th and 19th centuries and were considered likely to represent the latest in an extensive sequence of intercutting burials within the proposal area.

Where graves were identified excavation was limited to defining grave cuts, thus limiting the potential for the evaluation to inform upon the development of the church or churchyard

prior to the 18th century. None of the geophysical anomalies were identified convincingly during evaluation; this was considered to be due to the high density of unrecorded burials and the depth of deposits overlying the natural geology.

Residual pottery of late prehistoric and early medieval date, in addition to prehistoric flintwork, was recovered during the evaluation; this provides tentative evidence of activity within the immediate area prior to the development of the church in the 12th century.

2 AIMS OF THE INVESTIGATION

The aims of the investigation as laid out in the Written Scheme of Investigation were as follows:

- To record any archaeological remains that will be impacted on by the groundworks.

In particular:

- To record and excavate any burials encountered during the groundworks.

3 STRATEGY

3.1 Research Design

John Moore Heritage Services carried out the work to a Written Scheme of Investigation agreed with Berkshire Archaeology, the archaeological advisors to Wokingham District Council. The recording was carried out in accordance with the standards specified by the Chartered Institute for Archaeologists (2014).

An archaeologist was present at all times during the course of all excavations that had potential to disturb or destroy archaeological remains. This included ground reduction for the slab, excavation for service/drainage trenches and any other significant invasive works including landscaping, as outlined in the WSI (JMHS 2017).

When burials were encountered machine excavation in the area of the burials ceased until such a time as permission was obtained from the Diocese by way of detailed faculty of instruction. All further ground reduction around articulated remains was then carried out by archaeologists in order to clean, record and lift the burials. Disarticulated human remains were collected by the archaeologists for reburial when and where deemed appropriate by direction from the Church and under consultation with the Diocese.

Burials extending outside of the area of disturbance were not pursued, in accordance with Historic England's advice:

Our expert's understanding of the current guidelines is that they do not advocate 'chasing' burials found beyond the trench footprint, so the excavated area would be limited.

All cleaning, recording, lifting and processing of human remains and associated funerary furniture was in accordance with published guidelines (McKinley & Roberts 1993, Cox 2001, Brickley & McKinley 2004, APABE 2017).

Any archaeological features or other remains i.e. coffins or grave goods, were recorded by written, drawn and photographic record where possible. Where features were identified sufficient work was done to date, characterise and record the remains in accordance with the project objectives and in line with the sampling strategy set out in Annex 1, 1.8-1.9 of the WSI (JMHS 2017). Any variation to this was agreed with Berkshire Archaeology who

was notified regularly of all archaeological remains as they were encountered. All artefacts were collected and retained on site and were not removed without written instruction from the Church and Diocese.

All 'unexpected discoveries' were made known to both Berkshire Archaeology and the Diocesan Advisory Committee (DAC) as soon as it was possible. In all cases, preference was given to preservation of such finds *in situ* but where this was not practical such discoveries were hand excavated. All site recording was carried out in accordance with Appendix 1, 1.12-1.22 and the faculty. Berkshire Archaeology and the DAC were contacted before and during the excavation and watching brief phases in order to allow them to monitor the work and to arrange site visits as appropriate.

3.2 Methodology

When articulated human remains were encountered, work ceased in the immediate area until a faculty was obtained from the Diocese. Once the order had been received, the remains were cleaned by hand and excavated appropriately in accordance with the directions outlined in the faculty with guidance from Berkshire Archaeology. Standard John Moore Heritage Services techniques were employed throughout, involving the completion of a written record for each deposit encountered, with scale plans and section drawings compiled where appropriate. A comprehensive photographic record was also produced.

In the case of the location of the modern burials encountered (i.e. coffins and fittings), excavation of the area ceased immediately prior to disturbance of the burials. No further excavation of these burials was ultimately necessary after the architect took advice from a structural engineer and rerouted the structural plans and bridged over the area of modern burials. The resultant spoil from the ground works was visually scanned for archaeological material, especially for finds relating to disarticulated human remains.

4 RESULTS

The details of the excavations within the foundation pits are presented here. All deposits and features were assigned individual context numbers. Context numbers without brackets indicate features i.e. grave cuts, numbers in () show feature fills or deposits of material, while numbers in bold indicate structural features.

4.1 Fieldwork

Each of the twelve Foundation Pits (FP) and one soakaway on site was machine excavated until the uppermost level of burials was encountered. This involved the mechanical removal, by an 8-tonne excavator and a dumper, of c. 0.6m of topsoil and upper cemetery soils which extended to a maximum depth of 1.15m below current surface level (both of these deposits were assigned unique context numbers in each test pit, but the soil matrix was the same across the site). Due to the extent of truncation seen in the graveyard soils, a site wide matrix was not possible as all stratigraphic relationships prior to the latest burial in this northern section of the graveyard was lost in some form of ground raising actions which were seen to have occurred in the early 20th century. As such the phases discussed below can only be applied to the individual pits where physical relationships could be measured and recorded. The remains uncovered were cleaned and lifted in accordance with the faculty issued by the Church of England Diocese. After hand-excavation commenced, it continued as the main form of excavation within the test pits until natural geology was reached across the site.

Foundation Pit 1 (Figure 2)

In FP1, evidence of three articulated burials was recovered. There were two plots next to each other which, due to the apparent change in the graveyard level over time, there was no relationship visible between these two plots. The plot to the west in FP1 was for SK1 which was cut into natural geology. The plot to the east had SK24 cut into the natural and above that was SK5. All three had evidence of coffins, but the eastern most plot for SK5 and SK24 was seen to have very good preservation of the timber. Indeed coffin (1/10) for SK5 was so well preserved that large timber samples with fittings intact was able to be lifted and examined in post-ex (see detailed coffin analysis in Appendix 3 and 4). Within the coffin (1/10) for SK5, a safety pin was recovered which has a patent date of 1849. Above these burial plots was the grave soils, (1/07) which appears to be a levelling action seen across the entire graveyard and is present in all foundation pits. There was a masonry foundation from a previously removed grave marker **1/03** within cut 1/02, which was still visible in the ground and which abutted the location of the foundation pit. This was set within the topsoil layer (1/01) which also included the turf.

Foundation Pit 2 (Figure 3)

In FP2, evidence of seven articulated burials was recovered. There were multiple plots next to each other which, due to the position of the foundation pit, were only partially visible within the limit of excavation. There were six phases of burial which can be argued to have taken place with the lowest chance of chronological overlap due to their physical relationships. The first phase is represented by SK13. This was the earliest established burial based on the stratigraphic sequence. This burial was overlain by on its left side by SK10 which was the most complete remains recovered from FP2 and the only remains in Phase 2. The first of three burials within a plot centrally located within FP2 likely truncated this earlier burial. This first burial is SK20 and represents Phase 3. Phase 4 is seen in the second burial within this same plot, SK15. Phase 5 is represented by the final burial in this plot, SK2 as well as the first in a second plot in the northernmost section, SK12. The final phase is seen in SK6, the last burial in the plot to the north within FP2. The plot within the centre of FP2 was seen to have been reused for three individuals. The earliest was SK20, cut into the natural geology. Directly above it was SK15. Only the portion of the individuals below the knee was within the limits of the pit. These were so closely inline that it was suggested that they may have been buried together in separate coffins but in one cut. However, the evidence of coffins and grave goods shed light on the chronology. Within the grave fill (2/24) for SK20, a number of buttons were recovered which were analysed and dated to 1800s military trousers, as well as coffin fittings (2/26) which dated to the 18th century. The coffin fittings for SK15 dated to the early to mid-19th century. Above these burials and also closely aligned was SK2. This most recent burial within the plot was cutting another grave for SK10, slightly to the south. It is most likely that all three burials in the central plot truncated this individual, however due to the fact that SK10 is buried at a shallower elevation than all those buried within the plot, the chronology of which of these truncated SK10 is unknown. It has been reasoned that if the grave marker was present to indicate with such accuracy the location for reuse for SK2, SK15 and SK20, it is unlikely that a grave which did not predate all three of these burials would not also have been marked and accounted for during subsequent burial actions. It should be noted that this interpretation is therefore speculative and acknowledges that examples exist where graves were known to exist but the need to bury outweighed the indecency of disturbing remains. However, that interpretation is less likely. Moreover, the lack of any coffin evidence for SK10 also supports an earlier date for burial, as it and SK13 were the only two burials within FP2 which did not have any evidence of coffin presence. Above these burial plots was the grave soils, (2/06) and cut 2/07 and (2/05) in a cut 2/04 which appear to be possible

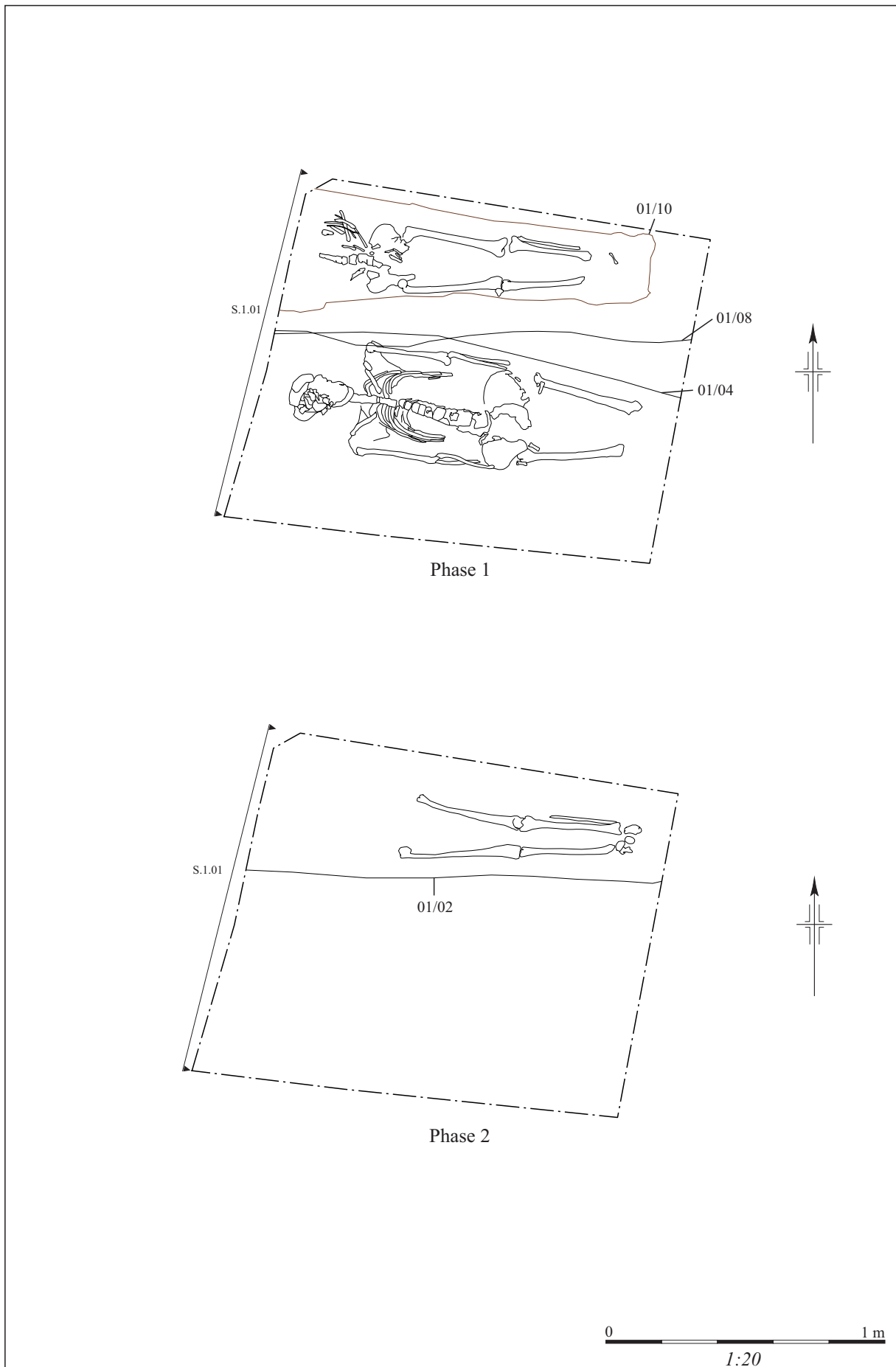


Figure 2: Foundation Pit 1, phases 1 and 2

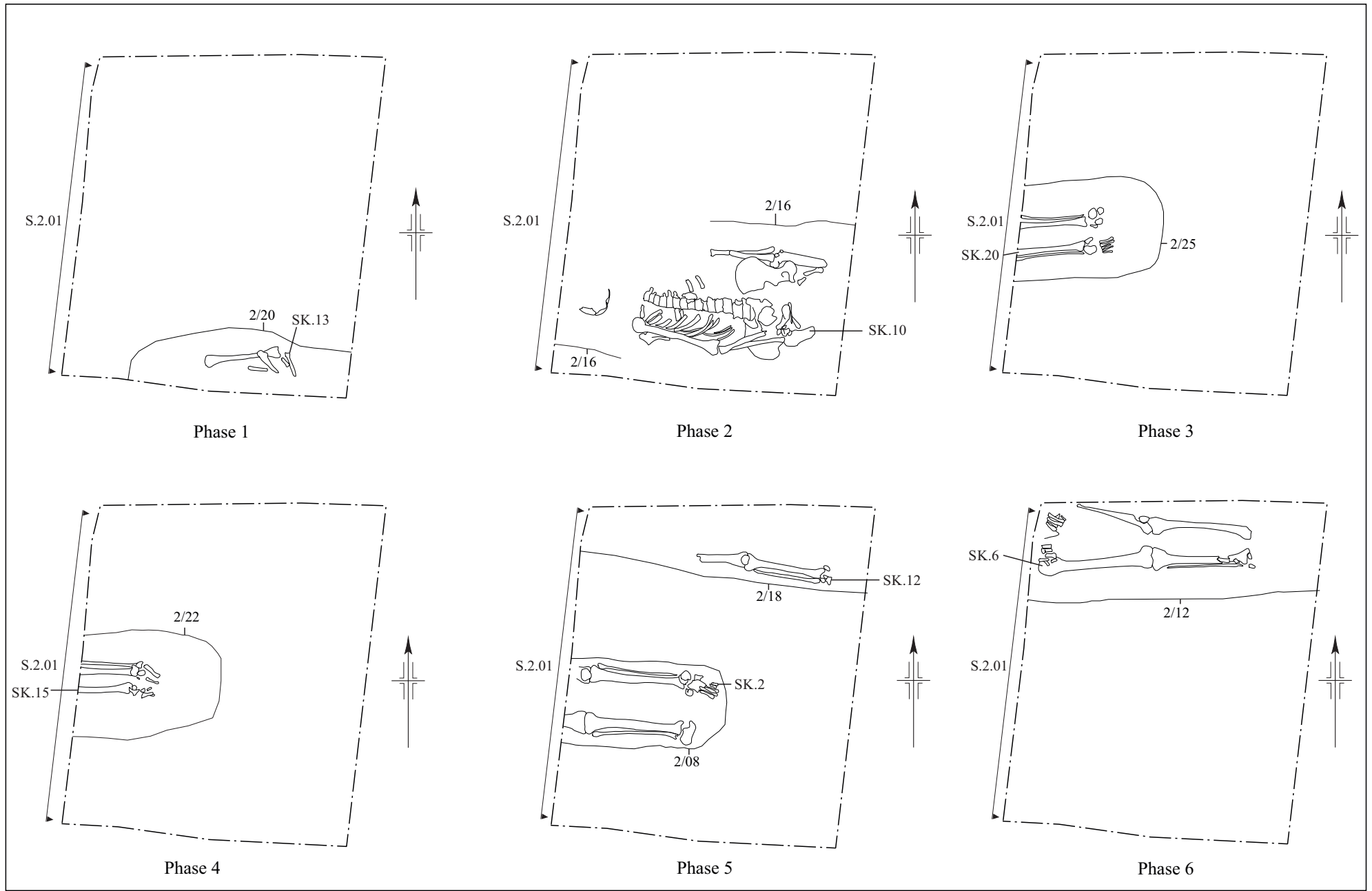
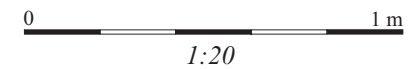


Figure 3: Foundation Pit 2, Phases 1-6



levelling actions. Evidence of truncation and deposition of redeposited grave soil was seen across the entire graveyard in all pits extending beyond the area disturbed by the rebuilding of the church in the early 20th century. The pits abutting the church showed disturbed soils to an even greater depth (up to 2m below ground level). There was a masonry foundation from a previously removed grave marker **2/03** within cut 2/02, which was still visible in the ground and which abutted the location of the foundation pit. This was set within the topsoil layer (2/01) which also included the turf.

Foundation Pits 3-6 (Figures 4-8)

Excavations against the church wall identified a foundation cut, however the depth of these were associated with the excavation of the 20th century foundations which extended down over 2m in total depth and resulted in a great deal of soil deposition over the top of the previously truncated graveyard surface. The evidence of this action was seen in all test pits abutting the church foundation (FP3, FP4, FP5, and FP6). The redeposition of at least some of this material is thought to have been spread across the previously disturbed graveyard. Evidence of an unusually deep grave soil, up to 1.5m below ground level in some pits, was found across the site and contained a great deal of disarticulated human bone (charnel). This lends support to this theory. In all cases, excavation stopped when the foundation's concrete footer was encountered in all test pits upon the structural engineer's advice.

Foundation Pit 3 (FP3) was located in the western most corner of the northern façade of the original north wall for the church (see Figure 1) which had a modern buttress added for support at the time of the construction of the new office addition in 1914. This pit contained eight articulated burials showing evidence of having been disturbed at the time of the construction of the new support buttress to the church in the early 20th century. The foundation of this support was observed to a depth of over 1.5m below the current surface. Within the pit, five phases of burial activity was evident based on stratigraphic and artefactual evidence (see Figure 4-6). The first and earliest phase was seen in SK33, in cut 3/21 which was the right lower leg of an individual. Phase 2, SK23 in cut 3/17, which was the left lower arm of an individual. Phase 3 was comprised of SK60 in cut 3/29, SK48 in cut 3/26, and SK 34 in cut 3/23. The coffin for SK60 was dated to the early to mid-19th century. Phase 4 was comprised only of SK26. Finally, Phase 5 was SK3 in cut 3/06, SK7 in cut 3/10, and cut 3/18 which was likely for another burial which was outside the limit of excavation. It is likely that SK7 and SK26 were in the same plot. The coffin (3/11) for SK7 was dated to the late 18th or early 19th century.

Foundation Pit 4 (FP4) was located in the south-west corner of the 1914 office addition along the northern façade of the original north wall for the church (see Figure 1). This pit contained no articulated burials as it showed evidence of having been greatly disturbed by the early 20th century construction activities. The new foundation was observed to a depth of over 2m below the current surface. The relationship between the old and new sections of the church was recorded in section 3.01 and a wrap section 4.01 and 4.02 (see Figure 7).

Foundation Pit 5 (FP5) was located in the north-east corner of the 1914 office addition along the northern façade of the original north wall for the church (see Figure 6). This pit contained one articulated burial and showed that there was a high level of disturbed ground from the construction of the new addition to the church in the early 20th century. The single burial for SK72 was seen in the eastern most limit of the foundation pit. The coffin (5/06) was dated to the 18th to 19th century. It was shown to have truncated an earlier burial which was subsequently deposited within the fill of the grave for SK72. Below this was the cut for the previous grave associated with the charnel deposit, 5/15. This cut truncated an earlier

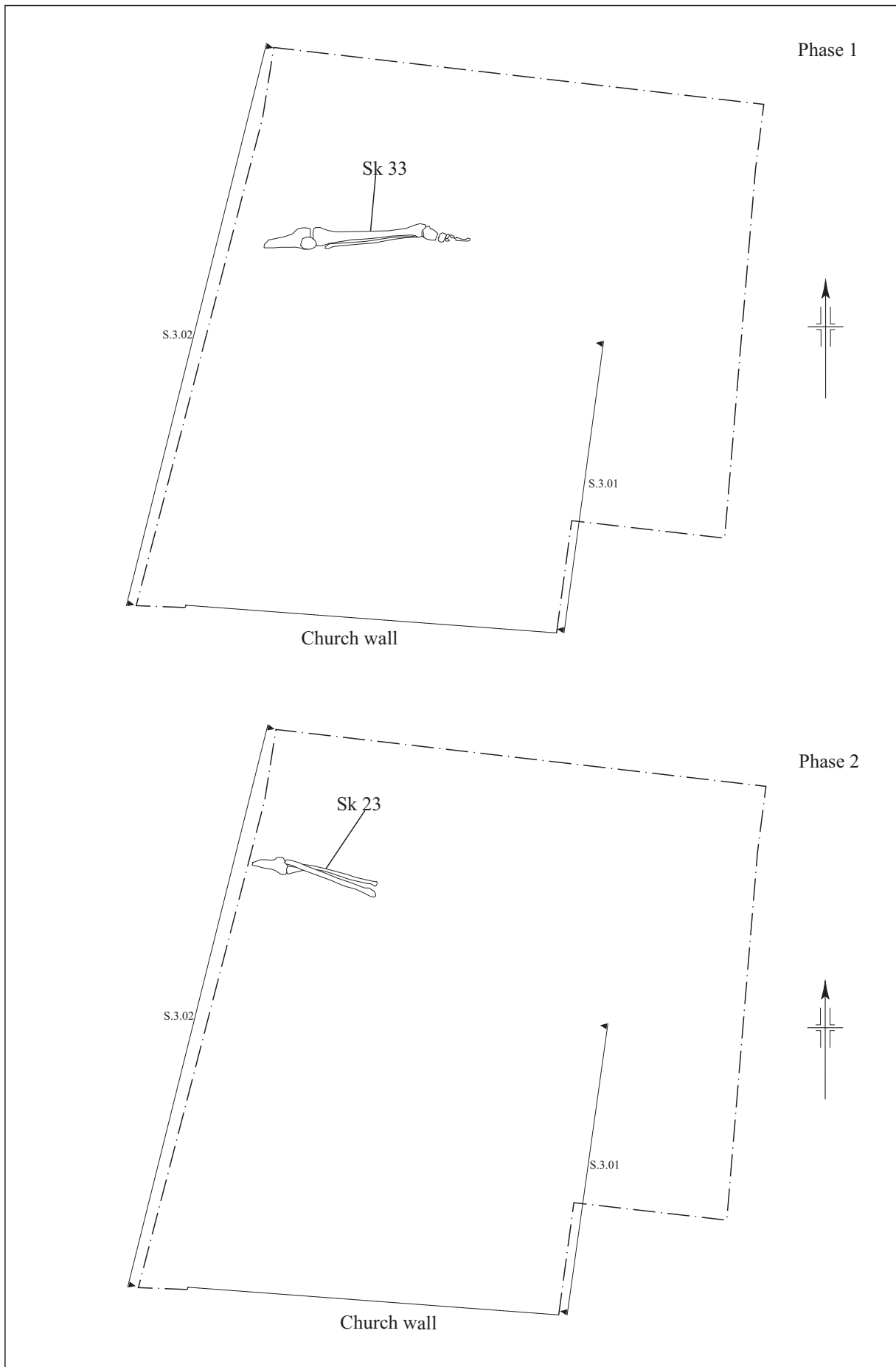


Figure 4: Foundation Pit 3, Phase 1-2

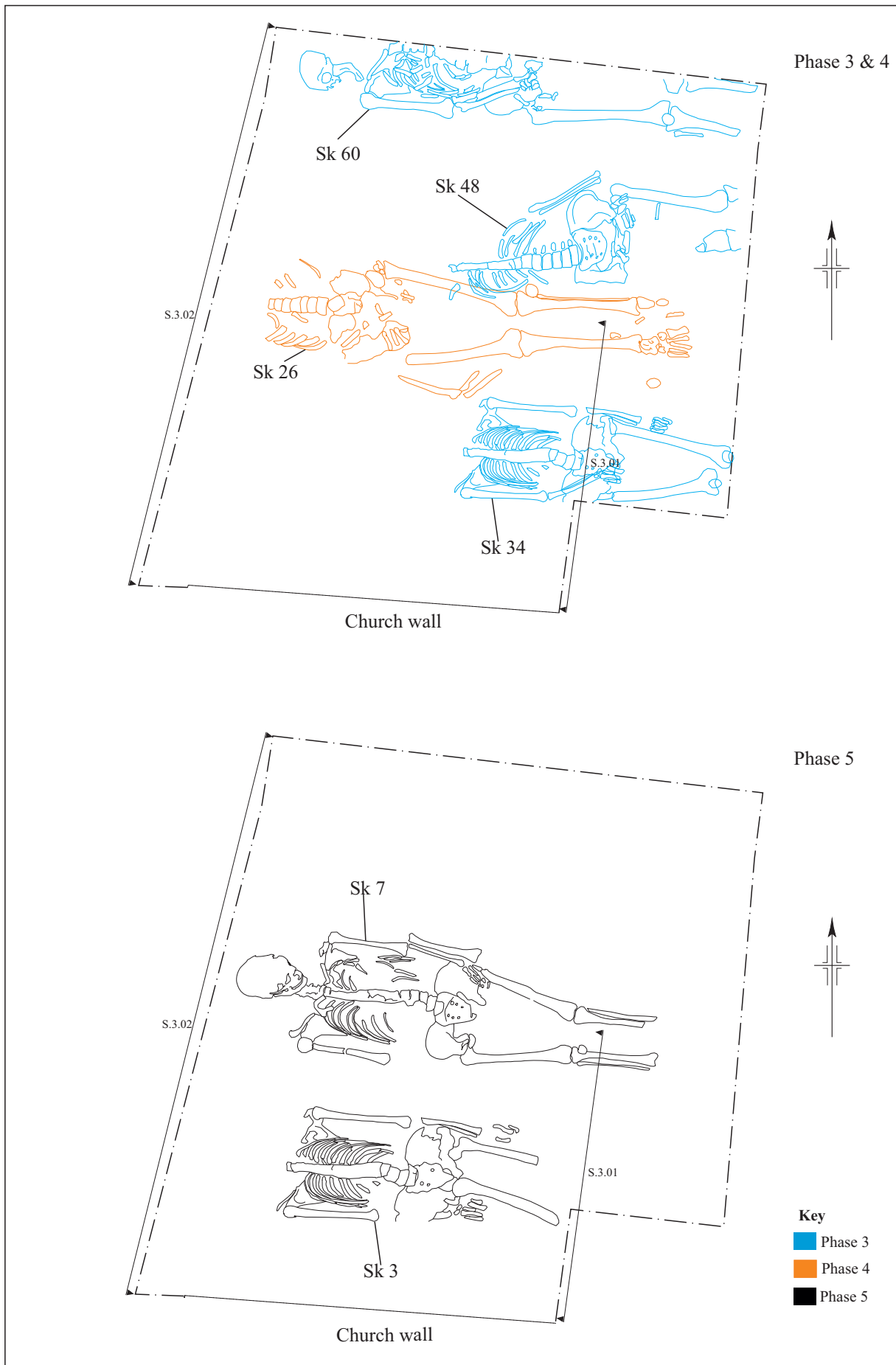


Figure 5: Foundation Pit 3, phases 3-5

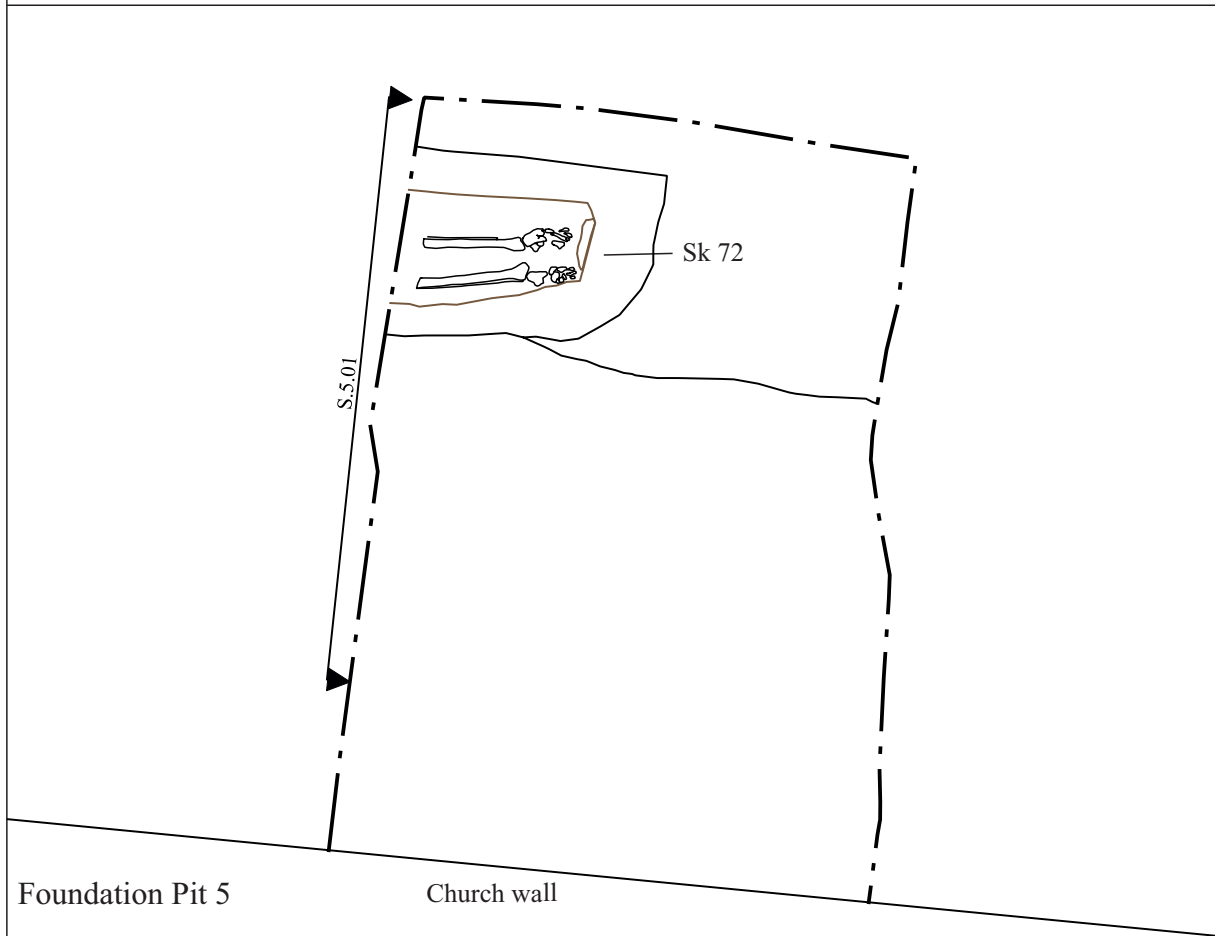
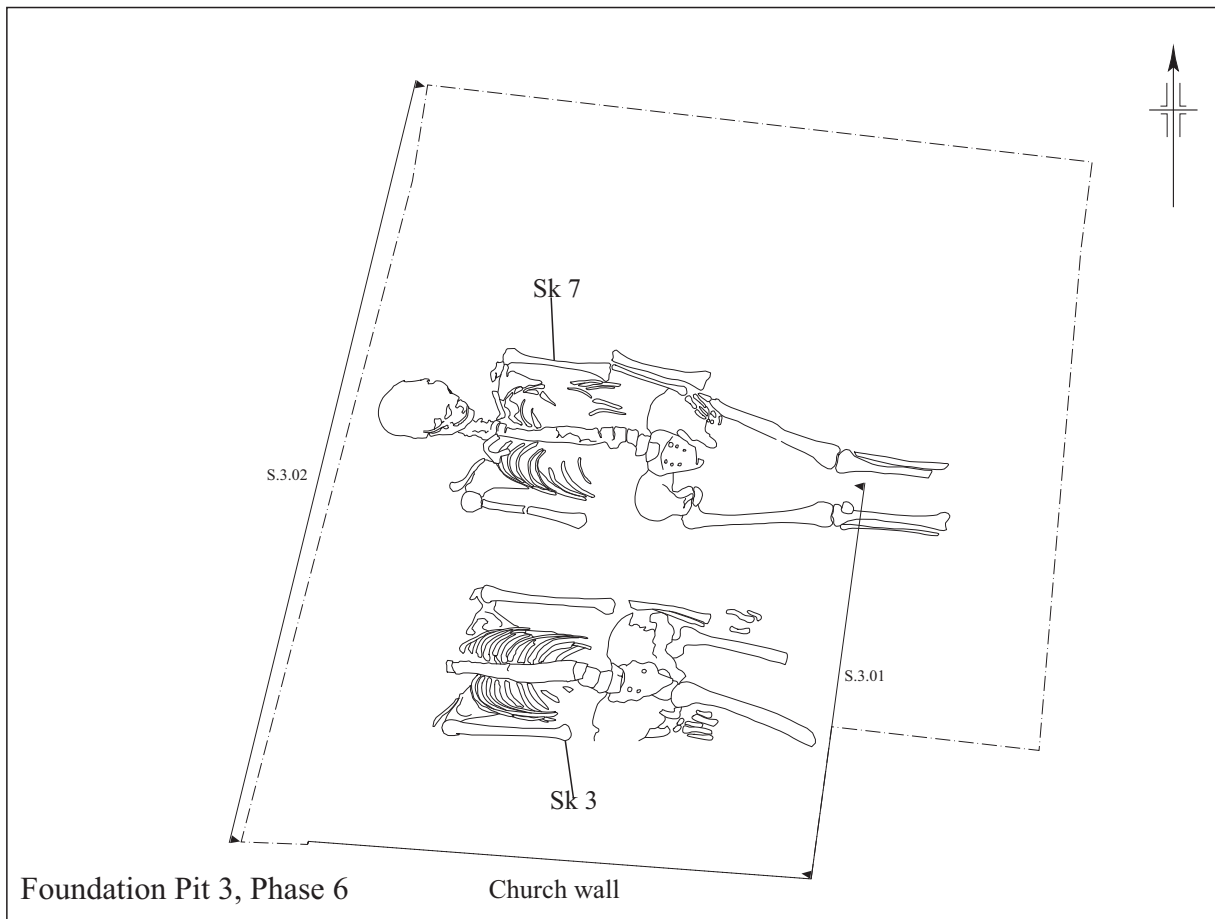
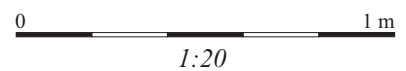


Figure 6: Foundation Pit 3, Phase 6; Foundation Pit 5



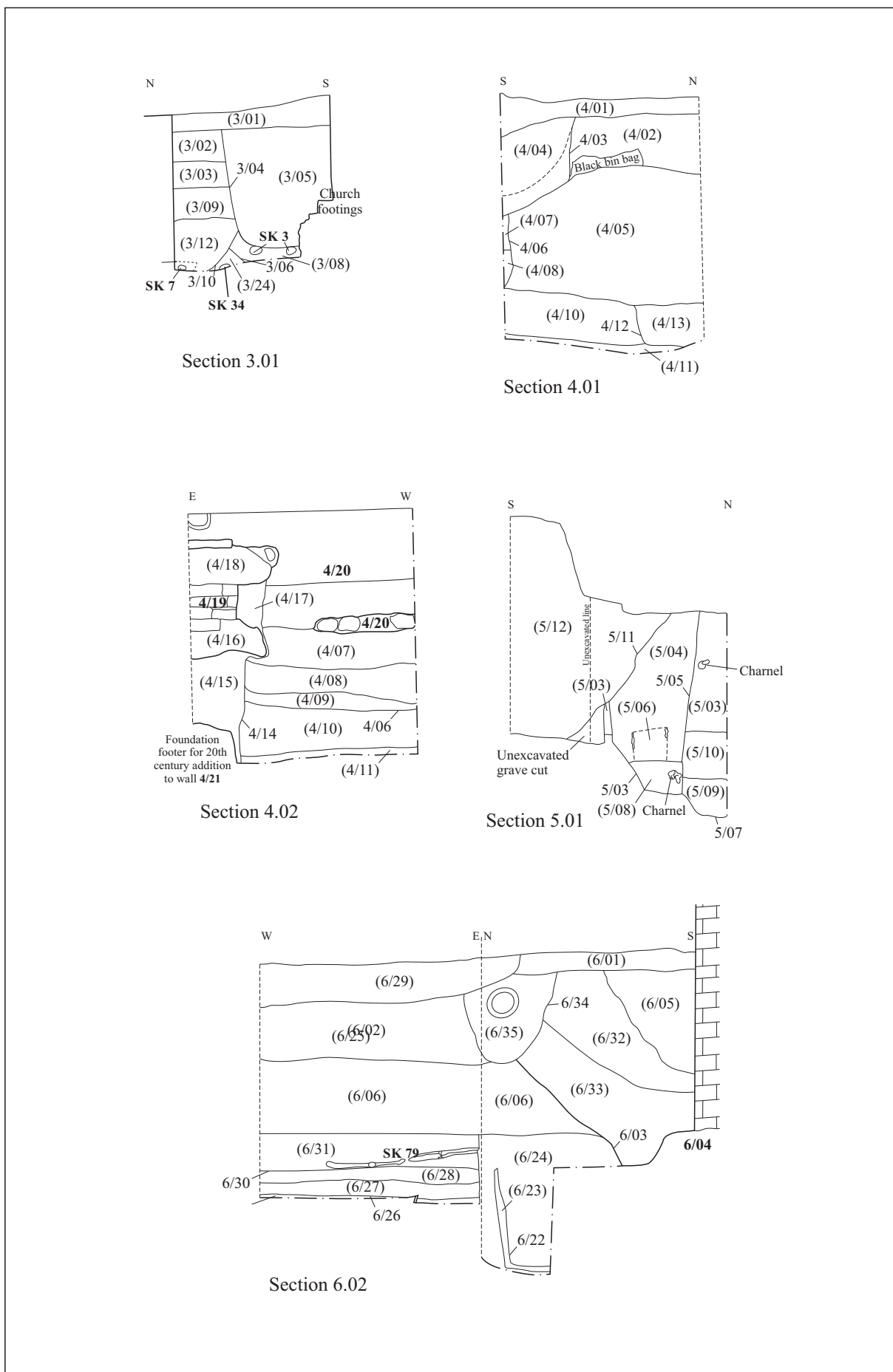
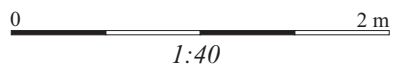


Figure 7: Sections S.3.01, S.4.01, S.4.02, S.5.01, S.6.02



ditch running roughly on an N-S alignment through the graveyard. The relationship of the gravesoil and church can be seen in section 5.01 (see Figure 7).

Foundation Pit 6 (FP6) was located in the north-west corner of the 1914 office addition along the northern façade of the original north wall for the church (see Figure 8). This pit contained six articulated burials and evidence of a burial with intact coffin but no remains visible within the limit of excavation. There was evidence that the area was deeply disturbed from the construction of the new addition to the church in the early 20th century. The new foundation was observed to a depth of over 1.5m below the current surface; excavation stopped when the foundation's concrete footer was encountered due to the structural engineer's advice. The relationship between the old and new sections of the church was recorded in a wrap section 6.01 and 6.02 (see Figure 7). Five of the six burials was able to be identified in terms of the chronological phase of burial. The earliest was SK79 which was truncated on the south by SK77. Then just slightly to the west SK78 was placed which truncated SK77. East of this was SK76 which truncated the lower leg and right arm of SK78 and SK77, respectively. Then slightly south again was SK83 which truncated SK76. The coffin (6/20) associated with SK83. Evidence of a later burial which truncated all of these was seen in cut 6/22 which contained a well preserved wood coffin (6/23) but had no human remains visible within the limits of the excavated area. The cut for the grave was visibly truncated by the activities associated with the rebuilding of the church in the early 20th century, so a late 19th century date is likely. To the south and being truncated by the foundation of the new addition of the office in the early 20th century, was SK73. The coffin fittings recovered dated this individual broadly to the 18th or 19th century. A single pewter button was also recovered from the fill of this grave.

Foundation Pit 7

Foundation pit 7 was excavated and recorded as FP12 (see below).

Foundation Pit 8 (Figure 9)

In FP8, evidence of one articulated burial was recovered. There were two plots next to each other however, due to the recent burial activity in the western plot (c. 1985) no building works were allowed to disturb the grave. To achieve this, a protective frame was constructed and allowed the excavation on either side of the modern burial to proceed. The plot to the east contained SK62 cut into the natural, with evidence of a coffin (8/04) dated to the early to mid-19th century. Above this burial plot was the same grave soils (8/02) seen across the entire graveyard and is present in all foundation pits. Above this was the topsoil (8/01) layer which also included the turf.

Foundation Pit 9 (Figure 9)

In FP9, evidence of five articulated burials was recovered. There is evidence of at least four separate plots and a minimum of four distinct phases of burial which are distinct and can be chronologically sequenced. The earliest burial was SK65 which had no evidence of a coffin and cut natural. Above this in the same plot was SK32 which also had no evidence of a coffin. Above this were SK61 with coffin (9/14) dated to the 18th or 19th century and SK63 with coffin (9/17) also dated to the 18th or 19th century. They were only partially visible within the limit of excavation. Above all of these was SK36 which was within coffin (9/11) dated to the late 18th to mid-19th century. The coffin was relatively well preserved and allowed for the recovery of details related to the fittings and the shape of the coffin was able to be recorded and analysed in post-ex (see detailed coffin analysis in Appendix 3 and 4). Above this burial plot was the same grave soils (9/02) seen across the entire graveyard and is present in all foundation pits. Above this was the topsoil (9/01) layer which also included the turf.

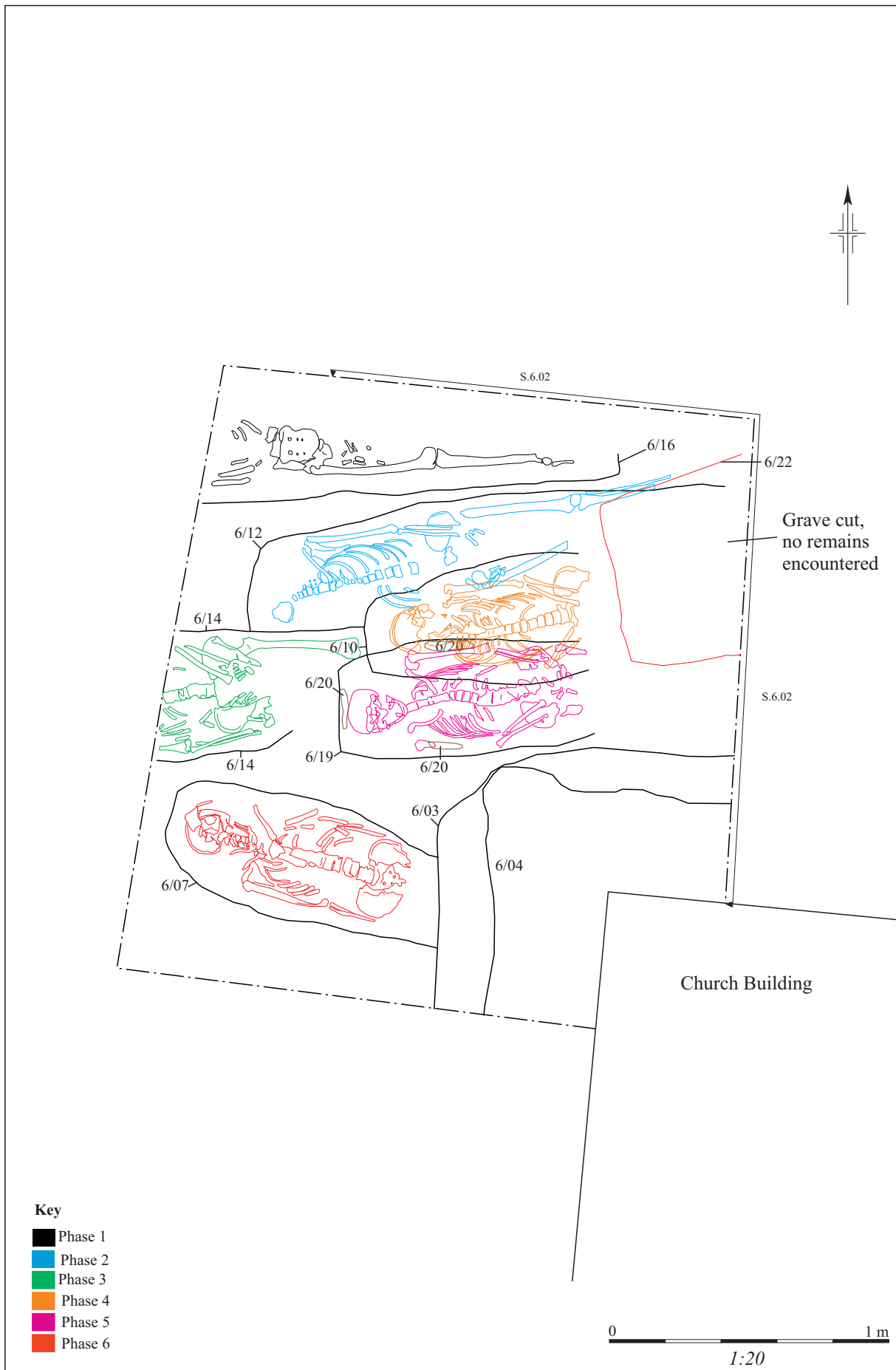

Figure 8: Foundation Pit 6, Phase 1-6

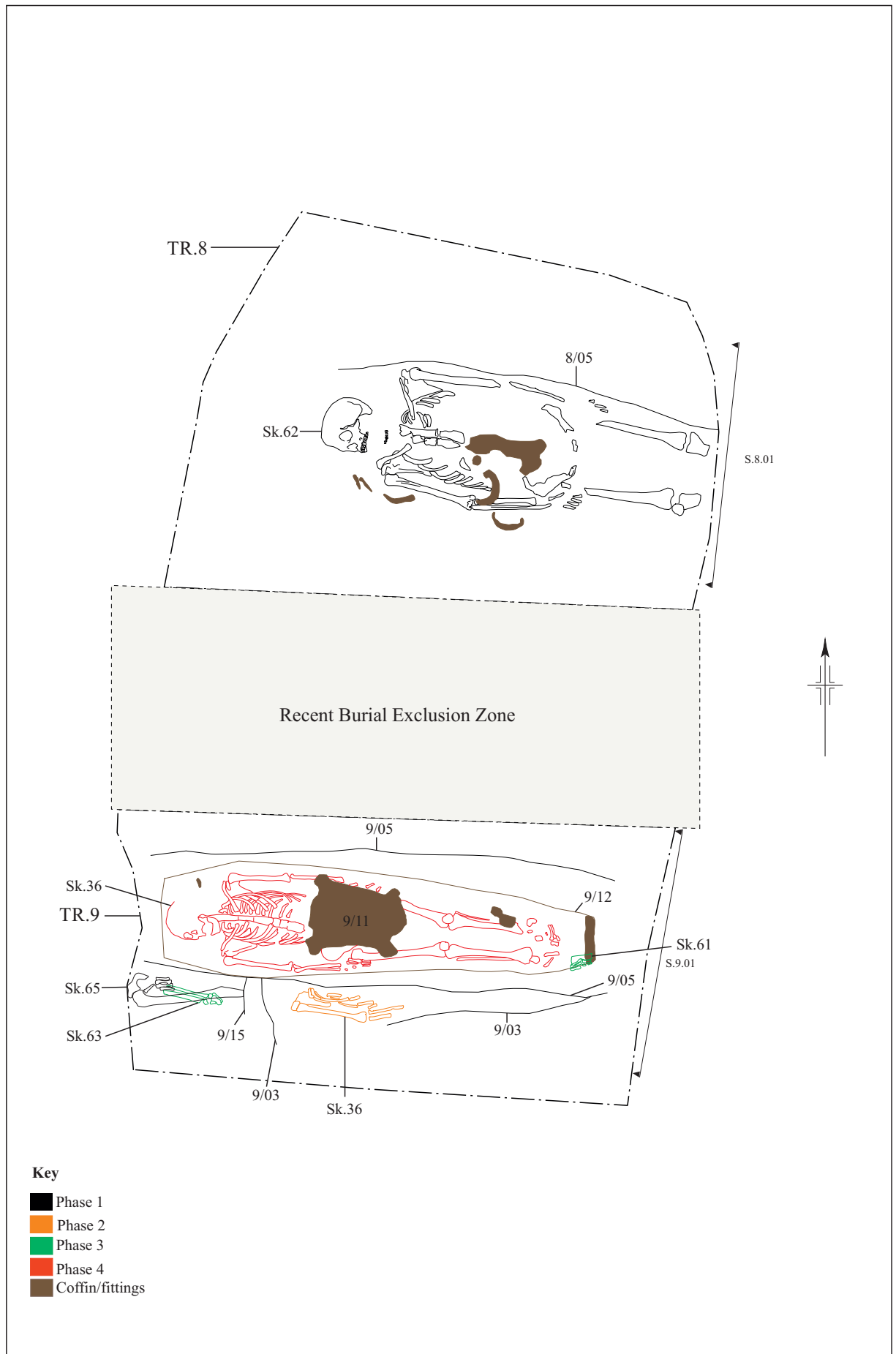


Figure 9: (above) Foundation Pit 8, phase 1;
 (below) Foundation Pit 9, phases 1-4

Foundation Pit 10 (Figure 10-11)

In FP10, evidence of 14 articulated burials was recovered. At least seven distinct phases of burial activities were able to be determined with the use of traditional stratigraphic analysis and georectification photography, and evidence to support the reuse of four burial plots.

The earliest of these phases was represented in SK51 and SK56. They lay on a similar alignment and were cut into the natural geology. Above these in Phase 2, was the very fragmented remains of SK22 which had experienced heavy truncation by later, surrounding burials. Phase 3 was seen in SK25 which was slightly lower in elevation than SK21 to the right (which may have slightly disturbed the lower right forearm) and roughly the same depth as SK45 to the left (which appears to have disturbed the left half of the remains). These flanking burials comprise Phase 4. Phase 5 is comprised of SK47 (which is directly overlying SK21), SK52 (only skull, mandible and a few vertebrae were within limit of excavation) and SK54. The latter was truncated to the left and right by Phase 6 burials SK4 and SK53, respectively. There was evidence for a coffin (10/07) belonging to SK4 which produced a grip plate that was dated to 1839-1845. The single burial in Phase 7 was of a mother and her unborn foetus, SK8 and SK14, respectively. Finally, the most recent burial represented in Phase 8 was SK9, which truncated the lower left forearm and left leg of SK8. Evidence of a coffin (10/12) was recovered in the form of nails and timber staining, however only a general post-medieval date could be attributed due to the lack of fittings. The plainness of the coffin could indicate a date of mid-18th century or earlier.

Foundation Pit 11 (Figure 12)

In FP11, evidence of four articulated burials was recovered. There were only two distinct phases of burial activity which could be determined stratigraphically. The first phase is seen in three of the four burials, SK80 SK84, and SK85. There was evidence of a decayed coffin timber (11/07) underlying SK84. All of the burials for this phase were encountered at a similar depth and were spaced far enough apart to potentially have been contemporary inhumations. The latest phase was seen in SK86. This burial was cut significantly deeper into the geology than the previous phase, and truncated SK80. Significantly, this burial cut was visible through the more recent graveyard soil disturbance which appeared across site. There appears to be at least two separate episodes of major grave soil disturbances, one quite near the church (which has been interpreted as a major ground levelling episode possibly associated with the rebuilding of the church in the early 20th century) and one which is evident in FP2, approximately 10m from the wall of the North Aisle and entrance. Evidence of a coffin (11/13) for SK86 were found by way of nails only which were dated to the 19th century, so it is likely associated with the earlier of these episodes.

Foundation Pit 12 (Figure 13-14)

In FP12, evidence of 13 burials with articulated remains was recovered. Two additional cuts were also recorded but no remains were encountered within them in the limit of excavation. There was evidence of four phases of burials. The earliest is composed of SK17 and SK27. Neither of these burials had evidence of an associated coffin with their remains and they were similarly aligned (slightly oriented with the head more to the south west and the feet more to the north east). Phase 2 was comprised of SK19, SK28, SK35 and SK50 with coffin (12/34) which dated to the early to mid-19th century. Phase 3 had the most activity with SK16, SK30 with coffin (12/20) which dated to the late 18th to early 19th century, SK31, SK43 with coffin (12/25) which was undated, and SK44 with coffin (12/28) which was only broadly dated to the 18th to 19th century. Phase 4 was the most recent burial activity and was seen in SK18 with coffin (12/08) which dated to the early to mid-19th century and SK29 with coffin (12/17) which dated to the middle to late 19th century.

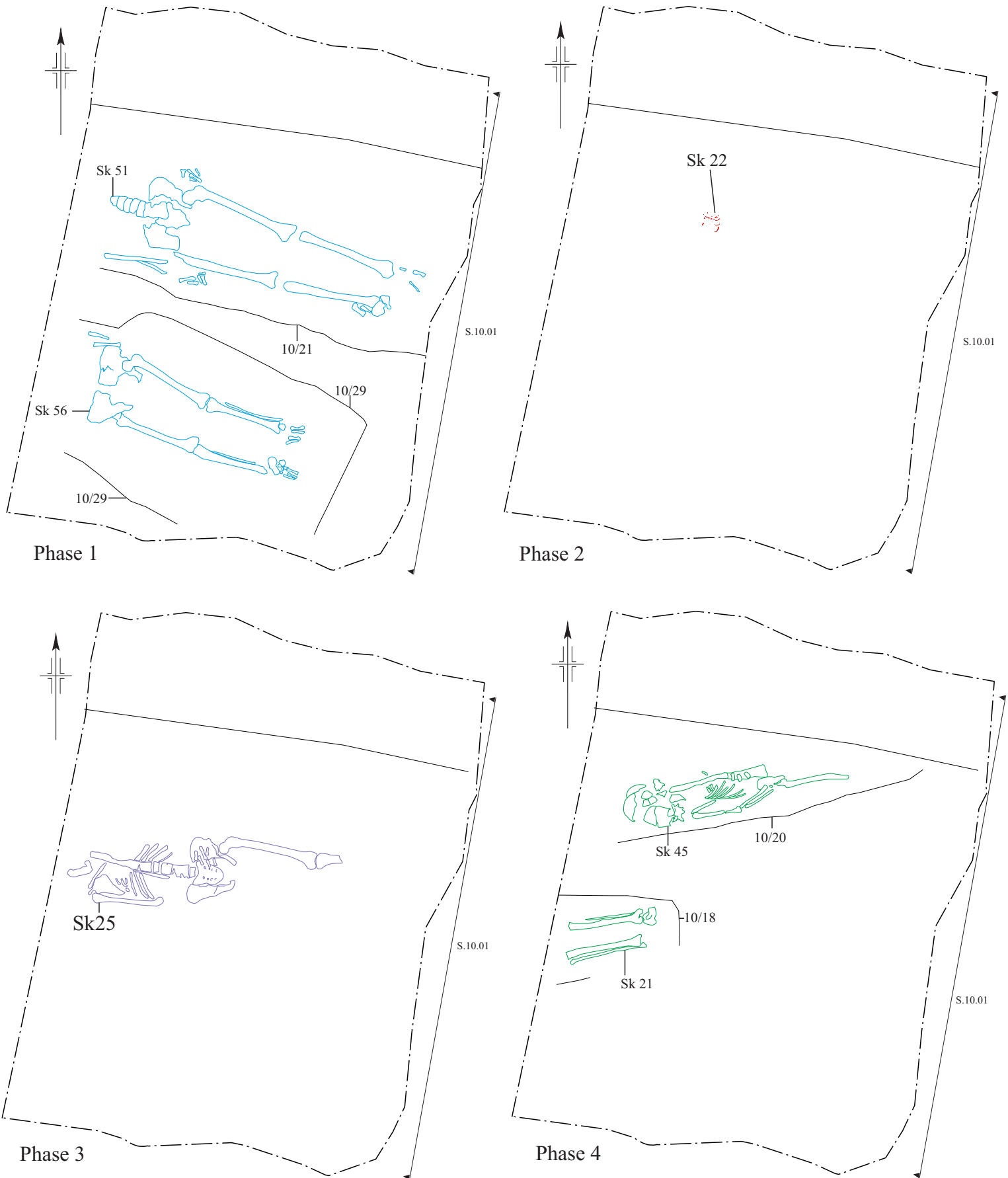


Figure 10: Foundation Pit 10, Phases 1-4

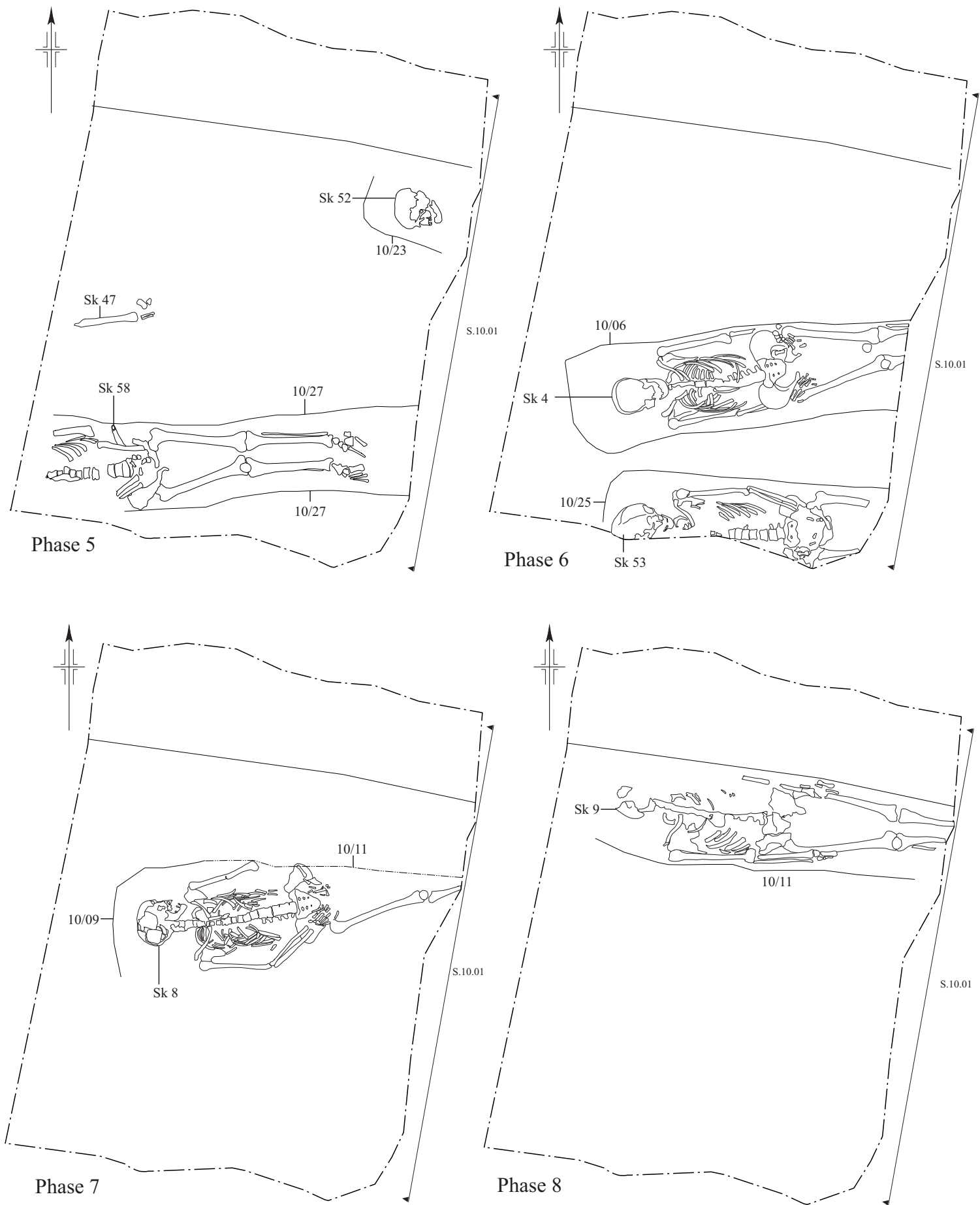


Figure 11: Foundation Pit 10, Phases 5-8 20

0 1 m
1:20

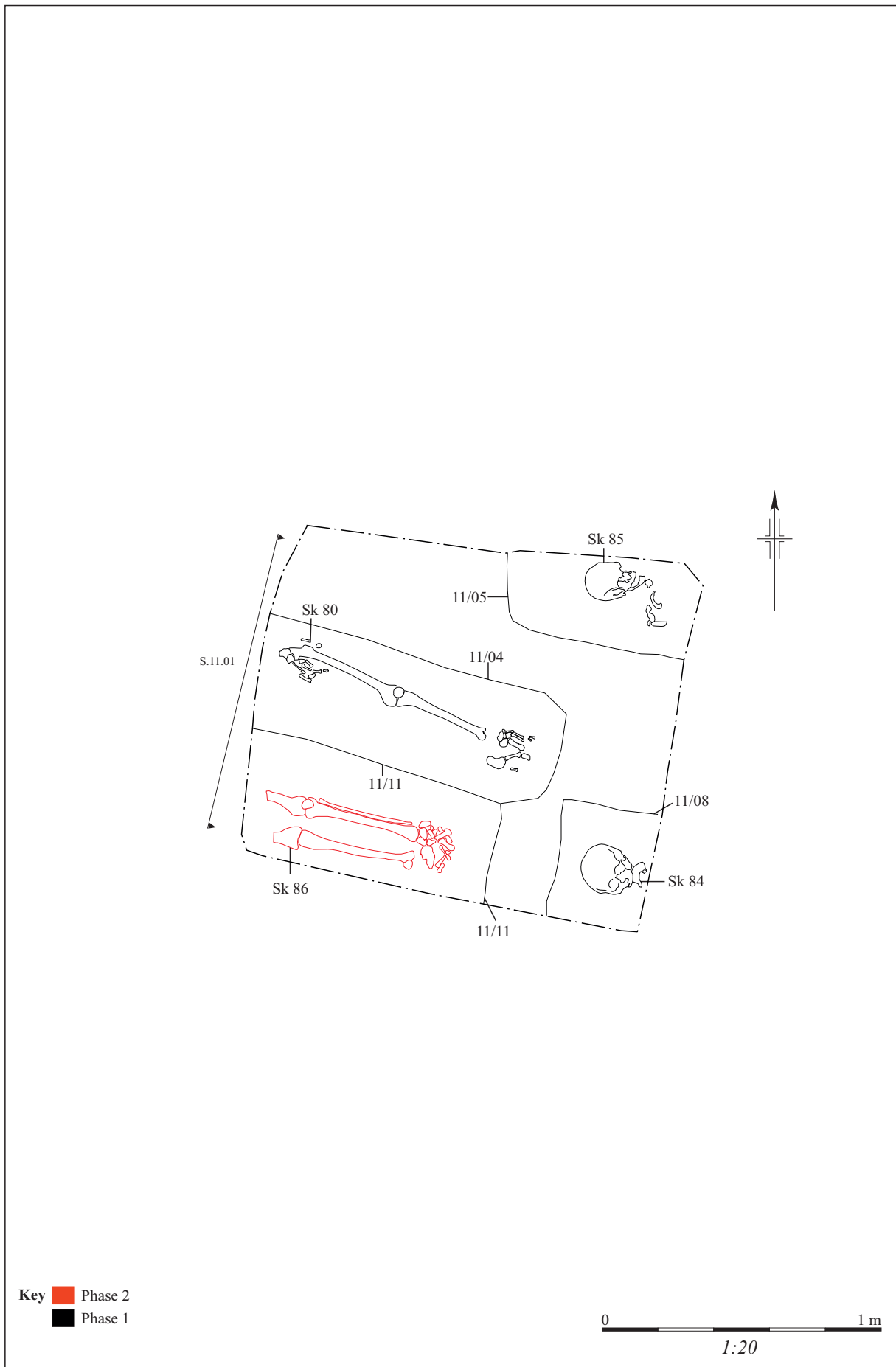


Figure 12: Foundation Pit 11, phases 1 & 2

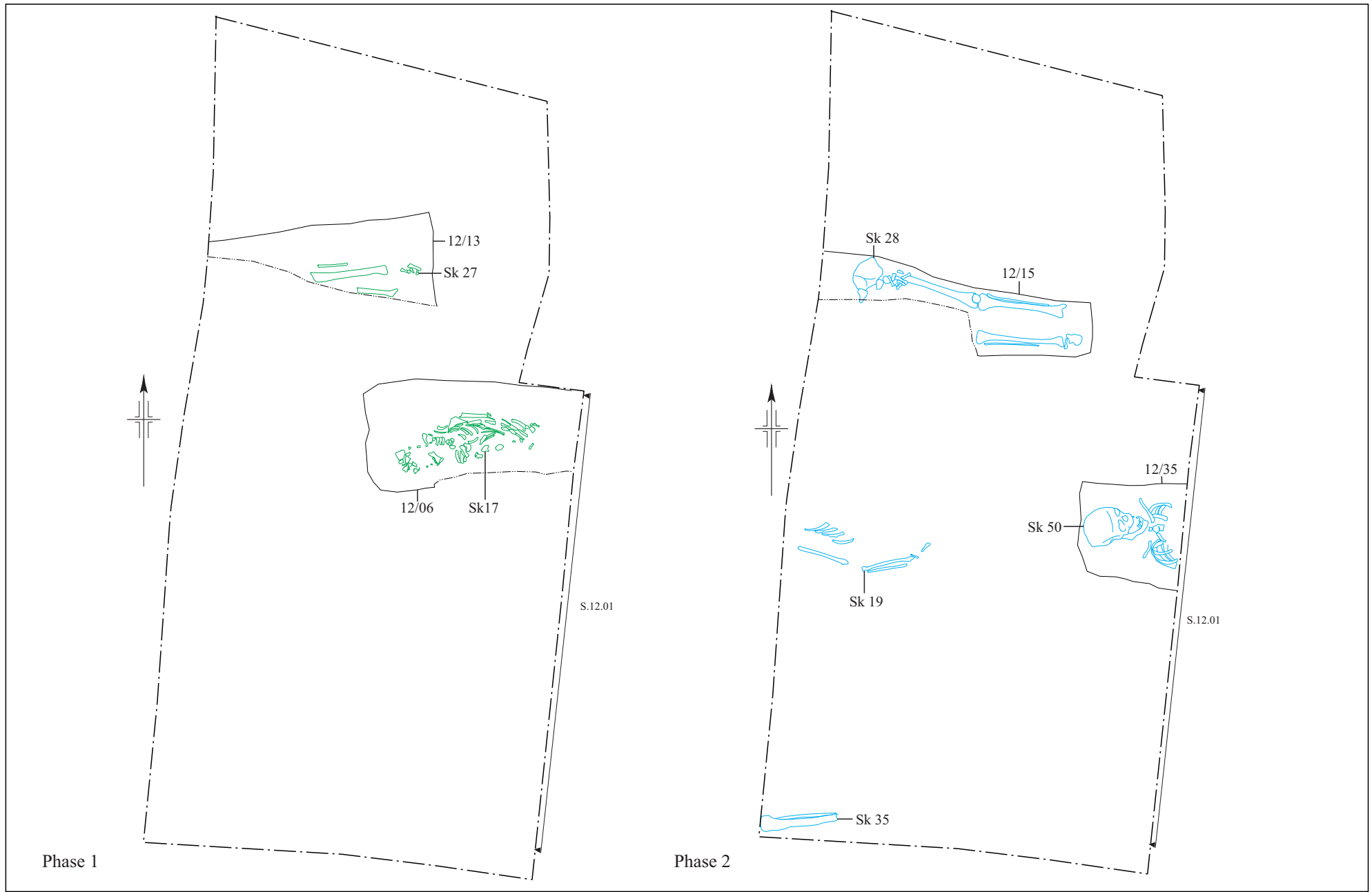
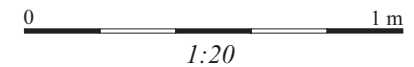


Figure 13: Foundation Pit 12. Phases 1-2



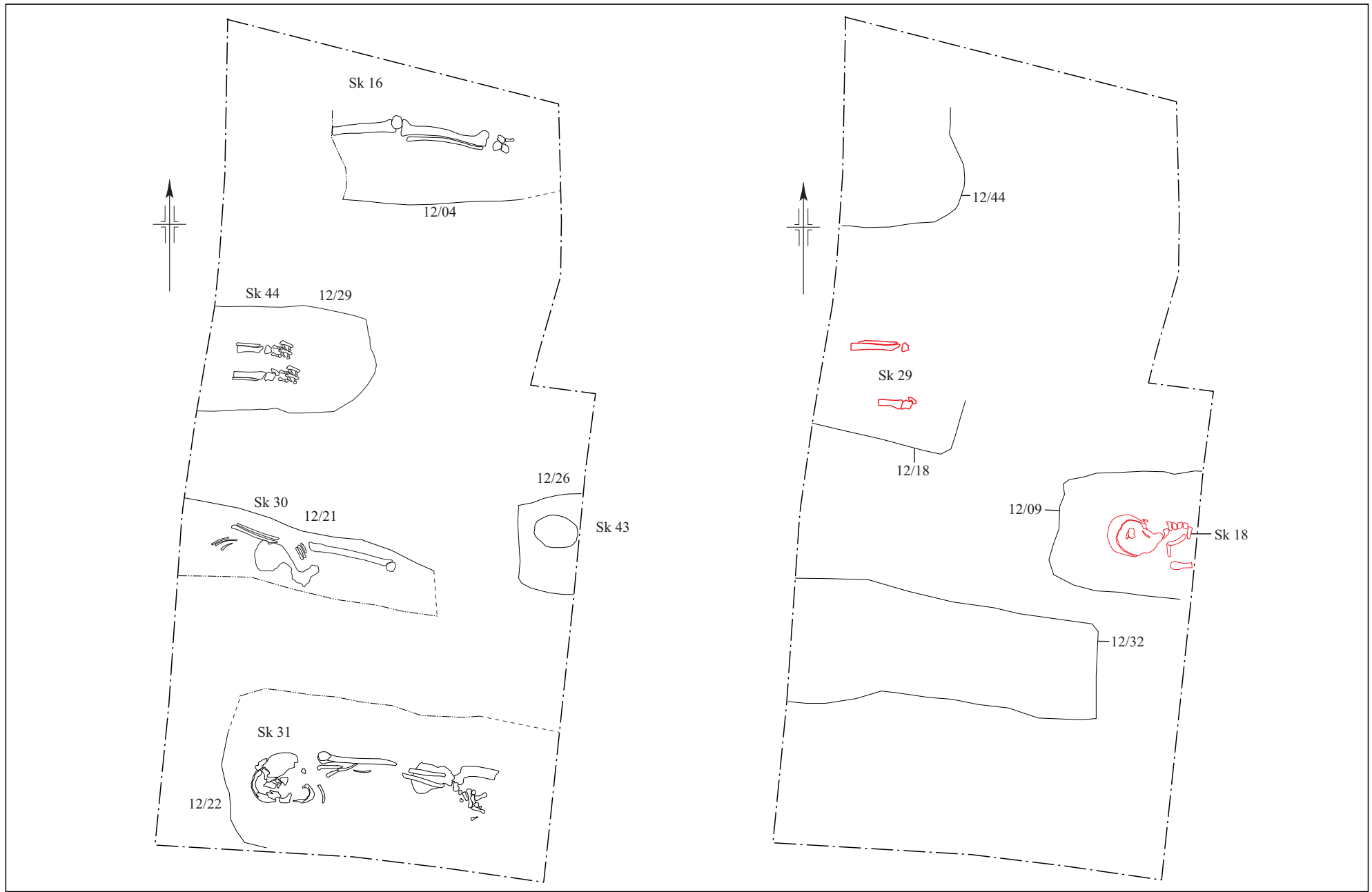


Figure 14: Foundation Pit 12. Phases 3-4

Additionally, a grave cut 12/44 in the NW corner which had a coffin stain (12/43) which was barely visible in the section and thus not dated. This was not excavated due to the fact that it fell outside the excavation limits and was deemed preferable to leave as intact as possible, as per the Faculty. The other cut was very recent as it was visible cutting through all the layers of graveyard soils up to the topsoil. It was excavated down to the water table and no articulated remains encountered, therefore it was thought to be a borehole test from within the last half century.

Soakaway/ Foundation Pit 13 (Figures 15-18)

In the soakaway (referred to throughout as FP13 for brevity), evidence of 28 articulated burials was recovered. There were seven phases which could be established in terms of stratigraphic and physical relationships. The earliest phase comprised of five burials, SK39, SK42, SK74, SK88, and SK92, none of which had associated coffins recovered. Phase 2 had three burials, SK70 with coffin (13/36) which was only broadly dated to the 18th-19th century, and SK71 and SK81, both of which had no associated coffins. Phase 3 was comprised of two burials, SK66 and SK93, neither of which had evidence of coffins. Phase 4 was comprised of only one burial with no coffin, SK57. Phase 5 is also comprised of three burials, SK40 and SK90, neither of which had evidence of coffins, and SK64 with coffin (13/45) which was late 18th to early 19th century. Phase 6 had five burials including, SK67, SK69 and SK94 which had no associated coffins, and SK82 with coffin (13/58) which was early to mid-19th century, and SK58 with coffin (13/27) which was dated to the late 18th to mid-19th century. Phase 7 had two burials including, SK59 without coffin and SK55 with coffin (13/28) which was late 18th to mid-19th century. Phase 8 had six burials including, SK37 coffin (13/17) which was undated, SK38 coffin (13/07) was late 18th to early 19th century, SK68 with coffin (13/41) which was undated, SK75 with no coffin, SK87 with coffin (13/61) which was not dated, and SK89 with coffin (13/66) which was also undated. Phase 9 had one burial, SK91 with coffin (13/71) which was undated.

It is interesting to note the number of undated coffins dating to the later phases of use in this foundation pit, which likely indicates the increase of lower status burials in this particular area towards the middle to late 19th century.

Summary

These results accurately provide a broad summary the overall findings from the excavation of the foundation pits and soakaway. The following sections provide a more detailed analysis of the specialist finds report which were relied upon to assist in the phasing outlined above.

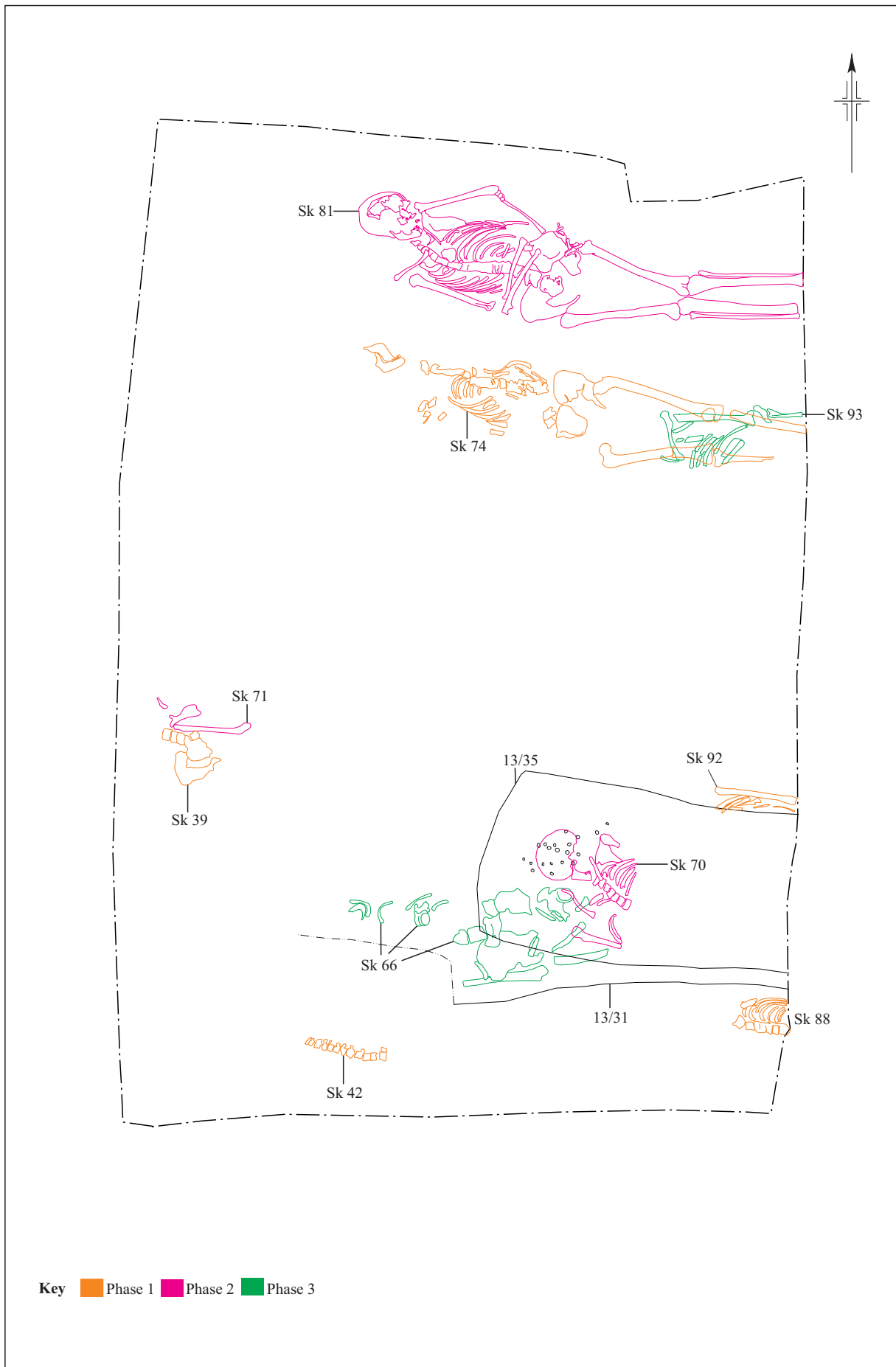


Figure 15: Soakaway (FP13), phases 1-3

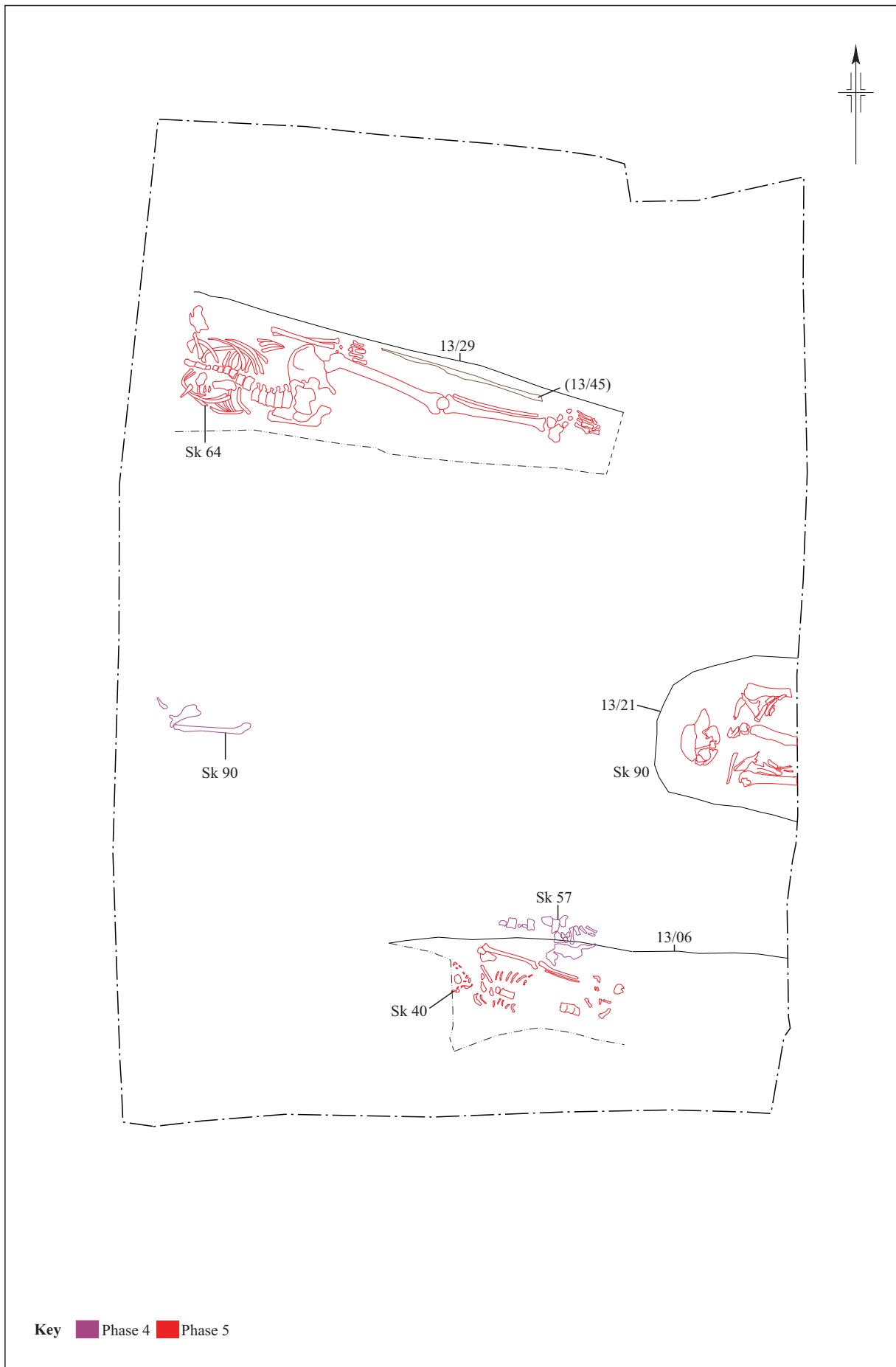


Figure 16: Soakaway (FP13), phases 4-5

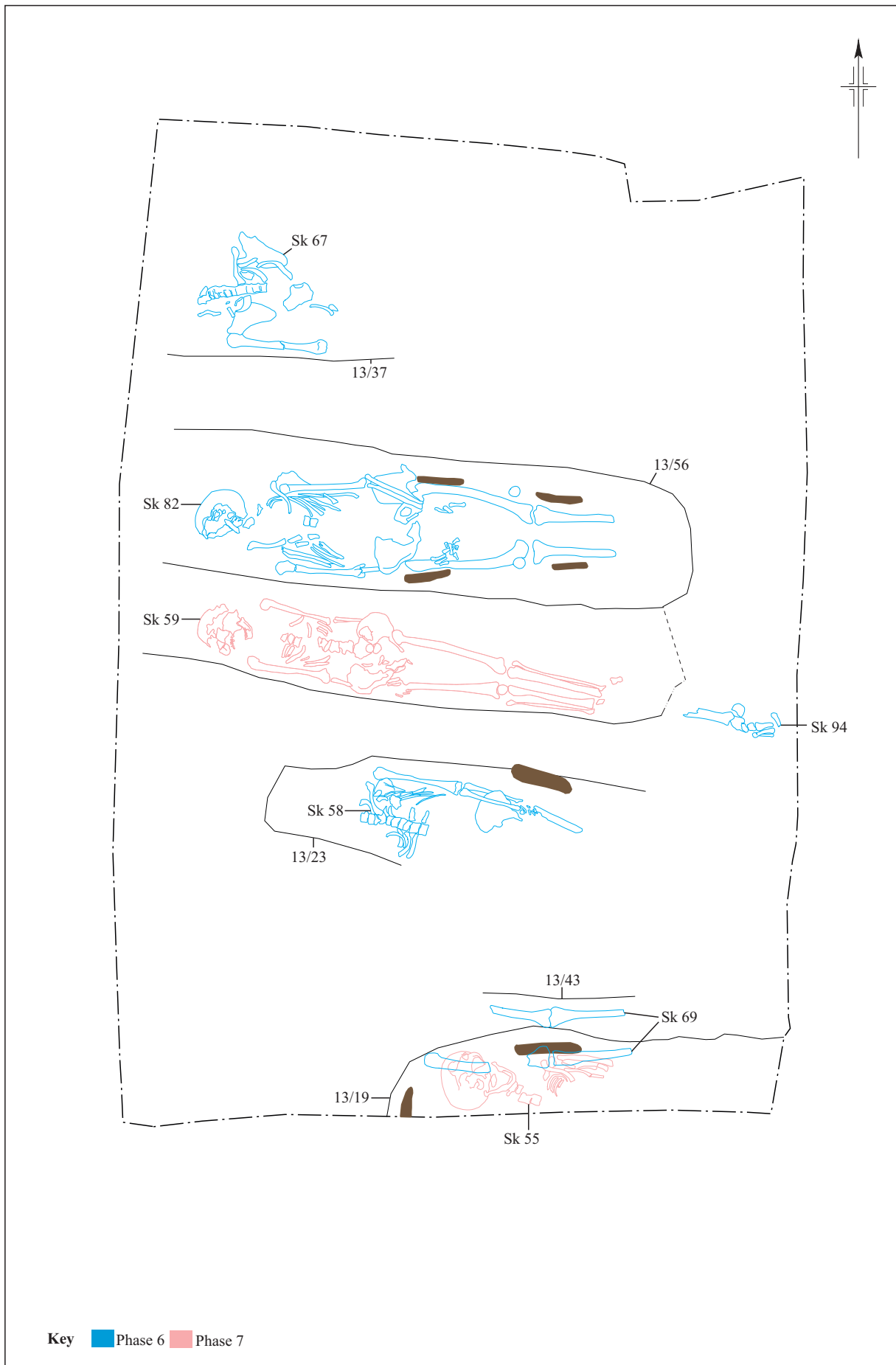


Figure 17: Soakaway (FP13), phases 6-7

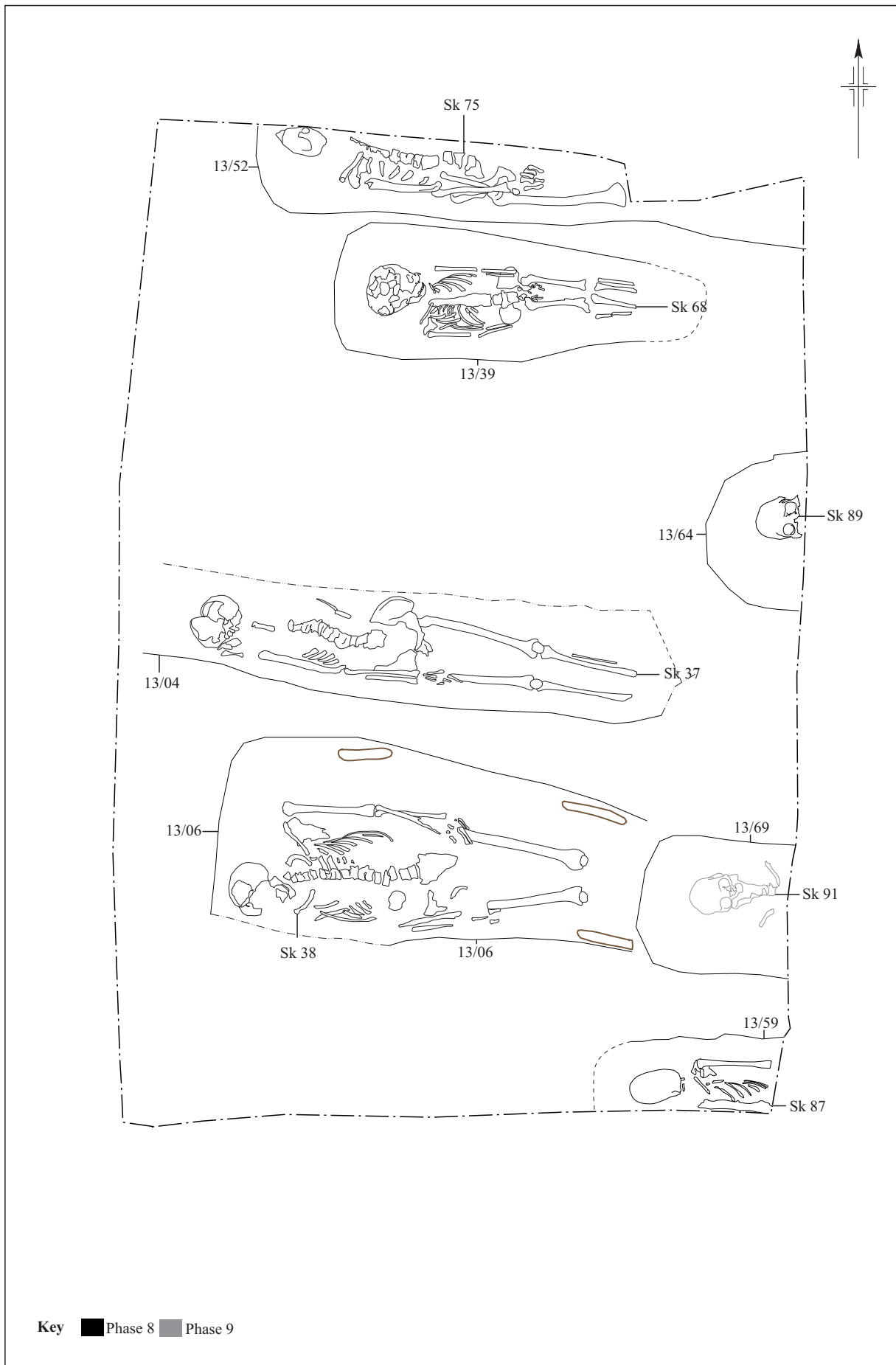


Figure 18: Soakaway (FP13), phases 8-9



Plate 1. External view of the North Aisle, St. Mary's Church, Wargrave. Flint masonry uncovered during excavation for the reburial of the human remains. Extending at a perpendicular angle to the North Aisle and corresponding to the archway on the internal side of the wall, it is thought to be potentially associated with an earlier architectural layout of the church. View facing south.



Plate 2. Interior view of St. Mary's Church, Wargrave. An archway associated with an earlier architectural layout of the church, potentially corresponding to the flint masonry uncovered perpendicular to the archway on the external side of the wall. View facing north.



Plate 3. Anglo-Norman Baptismal Font (c. 1000- 1300 AD), St. Mary's Church, Wargrave. This shows an early medieval font situated at the entrance to the churchyard at St. Mary's Churchyard in Wargrave. It is likely that it was associated with an earlier phase of use of the church. View facing north-east.

5 FINDS

5.1 Human Remains

Eighty-nine articulated skeletons and a large quantity of charnel were excavated by John Moore Heritage Services in the northern churchyard of St Mary's Church, Wargrave, Berkshire, in 2018. With the exception of coffins, very few graves contained dateable artefacts, and without radiocarbon dating it was very difficult to date individual burials. Crude dating of each burial was made from the presence or absence of a coffin (usually determined by coffin nails located around the skeleton). On the basis of this broad schema, the 89 articulated skeletons excavated in 2018 were broadly dated to late Saxon or medieval periods (c. 1100- 1485 AD) if uncoffined, to the early post-medieval (1485- 1730s) period if in plain coffins, and to the later post-medieval period (1730s- 1900) if in decorated coffins. The osteological analysis in the full report (Appendix 1) describes the composition of the skeletal assemblage as a whole, in terms of age, sex, stature and skeletal and dental health, and compares demography of the assemblage to historical records, primarily parish burial records of St Mary's Church (1538- 1899) and presents the data by total assemblage and according to these three approximate time periods. However, this section only represents a summary of the discussion and conclusions from the full report.

For the full detailed osteological analysis and report from which this discussion was taken (including tables, figures and plates), see Appendix 1.

Demography

When the demography of burials recorded in parish records is compared with that of the skeletal assemblage, considerable differences are apparent. Throughout the post-medieval period, the burial registers record a consistent pattern of slightly more males to females (1:0.9). This includes individuals of all ages. From 1813, when the name and age of the deceased was given, it was possible to calculate the proportion of adult males to females (204: 195 or 1: 0.96, respectively). Osteologically, it is not possible to sex non-adults, but overall, they comprised less than 10% of the total assemblage. Fifty-two adult skeletons could be sexed from skull and pelvic morphology, and these revealed almost twice as many males than females. The reason for this major disparity between the historical and osteological data is unclear. One possible factor is the tendency for the skulls of older females to appear more masculine in character, as a consequence of hormone changes associated with the menopause. Careful checking revealed that very few Wargrave skeletons were sexed solely skull morphology, so this is unlikely to be a significant factor in the overrepresentation of adult males in this assemblage.

Another very evident disparity is the underrepresentation of infants and young children in the skeletal record. Burial records of the 19th century indicate that infants below two years comprised almost one in five (18.4%) of all interments. It is unclear if this held true for earlier centuries, but certainly, for most working class women and their infants in the past, childbirth was potentially a very hazardous undertaking. Weaning was another critical and dangerous period in an infant's life. Malnutrition and infection were major factors limiting the survival of many infants and children in the past, as in many non-Western societies today. Thus, the high historical infant mortality in Wargrave is unsurprising. What is unexpected is the complete absence of infants and children below the age of five years in the skeletal assemblage. Together with the dearth of adult females, this absence strongly suggests zoning within the churchyard: that many mothers and their infants were buried elsewhere in the churchyard and were not archaeologically excavated in this project.

When considering the age distribution of Wargrave skeletal assemblage, it was clear that a very substantial portion of the population had survived beyond the age of 45 years. Indeed, historical analysis of the 19th century burial records revealed that, in this period at least, there were a significant number of septogenarians and a few surviving into their 90s. The high rate of degenerative joint disease may probably be explained by this older demographic, but activity undoubtedly contributed to joint wear-and-tear.

Pathology

Similarly, many pathological lesions on the skeleton are attritional, and hence, are more common in older populations. For example, the very high rates of dental disease, especially antemortem tooth loss, is probably in part due to this older demographic. The dental disease rates in the Wargrave assemblage compared much more closely with middle class assemblages of St George's Church, Bloomsbury, and the King's Lynn Quakers- both older assemblages. However, it should be noted that dental disease was present in all age groups at Wargrave, including children's milk teeth, suggesting that tooth decay and loss began early in life. This probably reflects poor oral hygiene and a diet rich in carbohydrates. In the later post-medieval period, the culprit was probably cane sugar.

Health

In terms of general health of the Wargrave population, the osteological evidence is slightly contradictory. Final adult stature is widely used as a yardstick of the general health of populations, both past and present. With a mean stature of 169.5 cm, Wargrave males were slightly shorter than several small-town medieval populations in the region. Male stature

fell between values noted for multiple working class and middle class assemblages of the 18th and 19th centuries. In contrast, mean female stature was considerably higher than other medieval assemblages, and slightly higher than many post-medieval ones. This would tentatively suggest a slightly higher status of females in Wargrave, especially in earlier centuries. However, all interpretations must be tempered by the reflection that these means are based on very small sample sizes, which may well result in unrepresentative data.

Another measure of the health of a population is the health and survivorship of infants and children. The parish burial records indicate that, like many populations in the past, there was a high rate of infant and child deaths in Wargrave, at least in the post-medieval period. This was not reflected archaeologically (see above). None of the non-adults in the skeletal assemblage displayed bony lesions suggestive of chronic ill health or malnutrition, such as scurvy, rickets, anaemia or periostitis. However, one child had experienced considerable growth stunting, strongly suggestive of chronic ill-health. Similarly, osteological evidence in adults for malnutrition was slight. Possible scurvy was the most common, but diagnosis was tentative, and may reflect seasonal shortages of green vegetables and fruit in winter and early spring.

Lifestyle & Status

Most adult skeletons, both male and female, displayed defined muscle insertions, especially on the arm bones, suggestive of a lifestyle that involved strenuous, repetitive physical activities of the upper body. Bony evidence of spinal loading in childhood or adolescence (such as carrying heavy loads in the arms or on the head), suggests that work started early in life for many parishioners. This is may also be true of the two individuals with osteochondritis dissecans, although it must be acknowledged that such lesions may be incurred during sport or play activities as well as work.

Two unusual fractures seen in the Wargrave assemblage may also be occupationally-related: Shepherd's fractures of the talus and third metacarpal styloid fractures. High prevalences of both fractures have been observed in 18th century Royal Navy skeletons, and of the former, in female Lancashire handloom weavers. It is probable that Shepherd's fractures in the females in Wargrave were also related to driving a treadle during cottage-industries of weaving or spinning. Although, fanciful, the presence of bilateral Shepherd's and other fractures and possible scurvy in skeleton 7 tentatively suggests that at one time in his life, he was a sailor. All third metacarpal fractures were noted in the right hand of five males, and are likely to be activity-related injuries. This high prevalence in Wargrave may reflect the engagement of many Wargrave men in the river trade, with these injuries incurred during rowing, poling or sailing river craft. Alternatively, these riverine activities may have been recreational. Chronic sinusitis appeared to affect females more than males, and may reflect greater exposure to smoke and soot of domestic fires, particularly during cooking.

Infectious disease

There was relatively little osteological evidence for chronic infectious disease. Of the 13 individuals with periostitis, several may have been scorbutic rather than infective in origin. There were two probable tuberculosis, one definite and one probable syphilis case. One other individual had tibial periostitis thick enough to tentatively suggest a third syphilitic in the assemblage, but this may well have been non-specific infection. There were no other cases of osteitis or osteomyelitis.

5.2 Coffins & Coffin Furniture

It is unusual for extramural burials of the late Saxon and medieval periods to be coffined—the overwhelming majority were buried naked within a shroud (Gilchrist and Sloane 2005). Burial within a coffin became more popular in Tudor times and by the 17th century burial within a plain trapezoid coffin was normative (Litten 1991).

From the early 18th century it was common to decorate the coffin with upholstery and elaborated metal fittings. After 1730, the production of coffin furniture by stamping machines became power assisted, allowing mass production and a reduction in cost. From this period onwards, all but the most destitute's coffins were covered in cloth (usually baize or velvet), secured with upholstery studs (often in rows or elaborate patterns) and decorated with decorative stamped metal plates (escutcheons, grip plates and lid motifs), grips and/or *depositum* metal plates (most commonly breastplates) engraved or painted with the name, age and date of death of the deceased (Cherryson et al. 2012; Litten 1991). The financial investment in funeral furnishing grew over the course of the 18th and into the 19th century, reaching its zenith in the 1840s (Rugg 1999). After that date, a taste for a simpler funeral became the norm.

The number and the metal used in the coffin fittings broadly indicated the affluence and status of the deceased and/or mourners (*Ibid.*), with brass and lead fittings used in more expensive coffins, and iron in more modest ones. Completely unadorned coffins of this period generally represent the extremity of poverty, most commonly used in 'pauper burials' of those 'dying on the parish' in workhouses or in other institutions, such as asylums, or indigent strangers to the parish buried at the parish's expense. More elaborated coffin furniture is therefore likely to be dated to the late Georgian-early Victorian times (Boston 2006); however, in this period coffins varied considerably in construction, materials and decoration, ranging from simple wooden coffins held together by joinery to heavily decorated, upholstered examples, as confirmed by the evidence from St Mary's.

For the full detailed analysis on the coffin furniture see Appendix 3. For catalogue of coffins see Appendix 4.

Wargrave funerary custom

It should be noted here that one of the coffined burials encountered revealed the top of the coffin but no remains were encountered within the limits of excavation. The burial count therefore is one greater (90) than the skeleton count (89) as no articulated remains were encountered or removed from the portion of the burial within the scope of our mitigation efforts. Over 46% of the 90 individuals buried at Wargrave had a coffin. Thirty-six of the graves had metal objects indicating the presence of a wooden coffin; no remains of lead shells were recovered. Four graves presented traces of decayed coffin wood, visible as a darkening of the grave fill, although no associated metalwork was found. Two additional graves, not investigated, showed traces of wood staining.

The vast majority of the coffins were much degraded and in fragmentary condition, with only coffin furniture such as studs, fasteners, and grips being recoverable. Coffin 1/10 for SK5 was the only example that partially preserved the original wooden planks, to a maximum length of 530mm; smaller fragments were also found in the graves for SK24 and SK82. Traces of wood were also observed on the reverse of some upholstery pins.

The poor state of preservation of the coffin furniture, severely affected by oxidation, prevented from the full observation of design details; grips decoration was only partially visible. The degradation had particularly affected the thin, tin-dipped elements of the

furniture (grip and breast plates, lid motifs), obliterating any decorative detail and, in most cases, reducing the items to fragments concreted around the reverse of the terminals.

All of the coffin furniture recovered during the excavation was made of iron and tin, with a single example (coffin (1/10) for SK5) of copper alloy. Iron and tin were the two cheapest materials available in the 18th century, usually associated with working class coffins in the later Georgian and Victorian eras (Boston 2008). On the other hand, the practice of painting tin grip plates in black was an expansive variant (Litten 1991), possibly to disguise the fact that the grips were made of cheap materials (Webb 2007). Black lacquer was observed on 20 of the grips recovered during the excavations; a number of upholstery studs, found in association with SK2, SK36 and SK61 also preserved traces of paint.

Only three of the graves (SK20, SK55 and SK73) contained buttons, suggesting burial in everyday clothing. Additionally, SK82 was buried with a pocket watch and seal, positively indicating the body was clothed.

The single copper alloy shroud pin collected during the excavation was found with SK7, indicating the presence of clothes or a shroud, while the grave for SK5 contained a safety pin.

Verdigris stains caused by the presence of copper alloy pins were recorded on the skeletal remains of eight additional individuals (SK38, SK55, SK58, SK64, SK67, SK72, SK73, SK82), although none of the items was recovered during the excavation.

Generally, the absence of any kind of clothes fastening in earlier burials suggests the body rested unclothed, wrapped in a shroud (Boston 2006).

Discussion

The Wargrave coffin furniture assemblage seems to generally conform to the trends registered for many other contemporary burial grounds. The material recovered has several parallel with collections from various sites across Southern England, with the minor variations in style probably representing different (possibly local) centres of production.

A notable characteristic of the assemblage found at St Mary's is the general absence of *depositum* plates. The widespread use of deposition plates starts after the 1750s; previously, from the late 17th to the mid-18th C the studs on the coffin lid were used to spell the initials, age and date of death of the buried individual (Bashford 2003), which could either suggest a generally earlier date for the Wargrave assemblage, or a generally lower level of income of the local population.

5.3 Personal Objects (Table 1)

A very limited collection of personal objects was recovered during the excavation at St Mary's, composed of 14 items (Table 1) associated with 6 individuals. The state of preservation of the items was generally poor, being severely affected by *Verdigris*.

Three types of objects were recorded; the largest group was composed of buttons (10 items), the remaining objects being pins and a pocket watch set.

Pins

A single copper alloy shroud pin SF4 was found in deposit (3/12), the grave fill for SK7. The item was built from drawn wire with a circular cross-section and a wound wire spherical head, measuring 1mm in diameter. The production of similar pins can be dated the 18th and 19th centuries.

In association with burials, pins had several functions. They could have been used to keep the shroud in place and hold garments to prevent slippage (McCarthy 2012), or to secure coffin linings (Cox 1996a).

SK5's grave fill (1/09) contained a copper alloy safety pin, patented by Charles Rowley in 1849 (<https://www.charlesrowley.co.uk/>).

Buttons

A group of eight tombac buttons (SF5, Plate 4) were found in association with SK20. The items, identical, were flat disc, stamped buttons measuring 30mm in diameter, with a wire shank soldered onto the flat reverse. The front of the buttons was engraved with a beaded border and peripheral wavy line, and a central 8-points star. No exact reference was found in the literature, although general design and individual decorative element are known from other examples dated to the 18th century (Bailey 2004).

The buttons were found along the right leg of the skeleton, indicating the body was buried clothed.

The copper alloy ring found in the grave for SK11 measured 14mm in diameter and 1mm in thickness, and was tentatively identified as the only surviving part of a combination or cloth button, as traces of textile were also observed.

A single pewter button was collected from (06/09), fill of the grave for SK73. The object was of the flat disc type, with wire shank. No decoration was present.

Pocket watch and fob seal (Plate 5)

One pocket watch (SF8) complete with fob seal (SF9) was recovered from deposit (13/57), fill of the grave for SK82. The items, although complete, were in a very poor state of preservation, being severely affected by *verdigris* and oxidation.

The watch, measuring 52mm in diameter, had a white dial with roman numerals; the hands were not preserved. The associated fob seal, measuring 23mm in length and 18mm in width, was incised with the profile of a female figure dressed in a Greek-style tunic and wearing a *kekryphalos*, a well-documented type of caul.

Fob seals were included on watch chains from the early 18th to the early 20th centuries (Bailey 1993); the name derived from the fashion of attaching them to a watch-chain or ribbon which was carried in the 'fob' (pocket). Fob seals were particularly popular in the Georgian period (1714-1830) (<https://www.ukdfd.co.uk/ceejays/site/pages/SealMatrix7.htm>).

Table 1: Personal objects occurrence by burial

Skeleton	Context	Small Finds No.	Material	Type	Quantity	Weight (g)	Date Range
SK5	1/09	N/A	CuA	Safety pin	1	0.6	1849+
SK7	3/12	SF4	CuA	Shroud pin	1	1	18 th -19 th C
SK20	2/24	SF5	Tombac	Button	8	58	18 th C
SK11	13/18	SF11	CuA	Button ring	1	0.5	Post-Medieval
SK73	6/09	N/A	Pewter	Button	1	7.6	Post-Medieval
SK82	13/57	SF8	CuA	Pocket watch	1	96.6	1714-1830
SK82	13/57	SF9	CuA	Fob seal	1	10.1	18 th -20 th C

5.4 The Pottery (Tables 2 & 3)

Prehistoric by Emily Edwards

A total of five sherds (23g) of prehistoric pottery were recovered from later grave fills within the churchyard at St Mary's in Wargrave.

The pottery was counted and weighed by context whilst fabric and form were briefly noted (PCRG 1997). Fabrics were given alphanumeric codes relating to the size of the principal inclusion. Codes included within the data comprised: A – Sand, D – glauconitic sand, F – flint, 1 – Fine, 2 – Medium, 3 – Coarse.

The range of surface treatments known to exist for prehistoric pottery found in Britain include smoothed, wiped, burnished, slipped, knife-trimmed, finger smeared, the application of crushed iron-rich matter, dry coating, painted and scraped. The kind of treatment and its location on the vessel are both important (PCRG 2010: 33).

It is widely recognised (Shennan 1981, Lambrick 1984; PCRG 1997) to be the case that 25-30 is the minimum number of sherds from which the dating of a defined episode of occupation can be determined with any confidence (Table 2).

This was an unstratified assemblage, with the sherds being associated with the lowest deposits or natural, within each later feature. It is also a small and fragmented assemblage, within which a range of vessel types are represented, including coarse jars and finer tripartite bowls, some burnished. The burnished sherd was covered with charred residue, on the internal face, which shows evidence of cooking, therefore of domestic activity.

It is possible, despite the fact that these sherds are residual and are not associated with any contemporary features, that these fragments are representative of a nearby, waterside later Bronze Age / early Iron Age settlement.

No further work recommended.

Table 2. Prehistoric pottery occurrence by context and type.

Skel.	FP	Cut	Fill	Coffin	Date	No.	Wt (g)	Fabric	Surf. Treat, Location	Elmt	Res?	Th (mm)
SK58	13	13/23	13/22	13/27	LBA-EIA	1	1	D1	Smooth, Int/Ext	Body		6mm
SK6	2	2/12	2/10	2/13	LBA-EIA	1	5	A1	Burnish,Int; Smooth,Ext	Body	Y	5mm
SK6	2	2/12	2/10	2/13	LBA-EIA	1	6	DF1		Body		8mm
SK73	6	6/07	6/09	6/08	LBA-EIA	1	2	FD2	Coarse	Body		9mm
SK77	6	6/12	6/13	na	LBA-EIA	1	9	DF1	Smooth, Int; Burnish, Ext	Body		7mm

Post-Medieval by Stephanie N. Duensing

A small assemblage of post-medieval pottery was recovered within grave fills and associated residual burial actions (Table 3). The assemblage had a combined weight of 35g and was comprised of 3 individual sherds. One piece of possible medieval grey ware was also present weighing 18g. All post-medieval pottery subscribes to the Museum of

London's codes for ceramics (MOLA 2018); for medieval material, Mellor (1984; 1994) was used.

Medieval:

OXAM: Brill/Boarstall ware, AD1200 – 1600. Wheel-thrown grey sandy ware with buff fabric on external surface, darker grey on internal surface. 1 sherd, 18g.

PostMedieval:

PMR: Red Earthenwares, 1580 – 1800. Fine sandy earthenware, usually with a brown or green slip or glaze, but sometimes with none, occurring in a range of utilitarian forms. Such pottery was first made in the late 16th century, and in some areas continued in use until the 19th century. 2 sherds, 7g.

PEAR: Pearlware, 1770 – 1900. Refined white ware with blue tinged glaze, commonly with a transfer-printed decoration. Pearlwares with underglaze polychrome-painted decoration in 'earth' colours was developed and were popular between 1790–1820. 1 sherd, 28g.

Fragments representative of 17th century to 19th century material consistent with residual deposition within graveyard soils or grave fills.

No further work recommended.

Table 3. Medieval and Post Medieval pottery occurrence by context and type.

Skel	FP	Cut	Fill	Coffin	Date	No.	Wt (g)	Code	Elmnt	Comments
SK2	2	2/08	2/09	2/14	1780-20 th c.	1	5	PMR	Base	Red earthenware (red inter glaze)
SK2	2	2/08	2/09	2/14	17 th -19 th c.	1	2	PMR	Vessel	Red earthenware (black inter glaze)
SK3	3	3/06	3/08	3/07	1860-1880	1	28	PEAR	Rim	Polychrome dendro mocha pattern
SK74	13	13/50	13/51	N/A	1600-1800	1	18	OXAM	Body	Medieval grey earthenware w/ green glaze (?)

5.5 The Flint (Table 4) by Rebecca Devaney

Just seven pieces of worked flint were recovered from context 10/08 and one piece from context 12/08 during the excavations at St Mary's Church, Wargrave (Table 4). All but two are secondary removals, exhibiting both the scars of previous removals but also retaining some dorsal cortex. The flakes remain uncorticated and have suffered slight to moderate post-depositional damage. The blade-like flake from context 12/08 is lightly burnt. The flint is not chronologically or technologically diagnostic and could derive from human activity at the site at any point in prehistory. However, the presence of blade-like flakes and the bladelet may suggest an earlier rather than a later prehistoric date. Due to the small assemblage size and residual nature, further work is not recommended.

Table 4. Summary of flint by type and context

Flint Category	10/08	12/08	Total
Flake	5		5
Blade-like flake	1	1	2
Bladelet	1		1
Total	7	1	8

5.6 Miscellaneous (Table 5 & 6) by Simona Denis

Clay Tobacco Pipe

A very limited assemblage of three clay tobacco pipe fragments, of a combined weight of 14.6g, was recovered from three different deposits. The material, although extremely fragmentary, was found to be in a fair state of preservation.

The items were positively identified as stem fragments; the example found in context (3/05), fill of the grave for SK37, preserved the heel. No marks or decorations were observed; unmarked stem fragments without diagnostic features or decorations have very little dating value, and can only generally be assigned to the Post-Medieval period.

Ceramic Building Material

A small collection of 17 ceramic building material fragments, weighing 2552.1g in total, was recovered during the excavations. The material, generally dated to the post-medieval period, included brick and roof tiles, and was in a fair state of preservation, although largely fragmentary.

Over 58% of the assemblage is composed of roof tile, while brick represents 23%; the remaining 17% remains undetermined.

- Roof Tile

10 of the ceramic building material objects, of a combined weight of 953.7g, were positively identified as roof tiles; of these, 2 preserved circular peg holes, and were therefore positively identified as peg tiles. The remaining 8 items were identified as plain tiles, as they did not preserve peg holes or nibs.

Traces of glaze were observed on one of the fragments found in deposit (6/09), fill of the grave for SK73.

The material can only broadly be dated to the 18th – 19th century, as hand-made peg tiles were commonly used until the 19th C, when machine-made tiles became popular, with little variation in the manufacturing technique. Also, good quality roof tiles were reused over long period of times; therefore, the potential for dating evidence of plain roof tiles remains limited.

- Brick

Four of the items recovered were identified as brick, weighing 1539.8g in total. None of the objects was preserved to its original dimensions; however, the complete thickness, ranging from 27 to 49mm, was recorded for all of the fragments.

Two of the examples showed traces of dark glaze or overfiring on the upper face and side.

Table 5: Clay tobacco pipe occurrence by context

Context	Type	No. of Items	Weight (g)	Length (mm)	Diameter (mm)	Comments	Date Range
2/21	Stem	1	3	36	5	Off-centre bore hole	Post-Medieval
3/05	Stem with heel	1	9.4	56	8		
9/10	Stem	1	2.2	20	6		

Table 6: Ceramic Building Material occurrence by context and type

Context	Type	Count	Weight (g)	Dimensions (mm) LxWxT	Comments	Date Range
U/S	Brick	1	444	123x65x40		N/A
	Brick	1	678	110x100x40	Corner. Traces of dark glaze/overfiring on upper face and side	
1/14	Peg tile	1	211	110x80x15	Corner. Complete circular peg hole	18 th –19 th C
2/09	Brick	1	46.8	49x31x27		N/A
	Peg tile	1	56.8	55x48	Partial circular peg hole, 11mm in diameter	18 th –19 th C
	Plain tile	1	54	31x10		
2/24	Plain tile	1	43	53x29x12		
3/03	Brick	1	371	83x62x49	Corner. Traces of dark glaze/overfiring on upper face and side	Post-Medieval
	Plain tile	3	220	Max 85x57x14		18 th –19 th C
3/20	Plain tile	2	348	Max 112x98x16		
6/08	N/A	1	27	44x40x10 (incomplete)		N/A
6/09	Plain tile	1	21	44x20x12	Corner. Traces of dark glaze/overfiring on upper face and side	18 th –19 th C
	N/A	1	10	29x23x10 (incomplete)		N/A
13/00	N/A	1	21.6	33x33x14 (incomplete)		N/A

6 DISCUSSION

The archaeological monitoring of the foundation works to the north of St. Mary's church revealed a great deal of new information about the burial practices across many generations of use, and most importantly, gave stunning insight into the daily lives of the members of the church over a period of roughly 1,000 years.

While positive dating was only possible on roughly 25% of the individual burials we encountered, the date range of occupation at this site spans from the prehistoric use of the area up to the 1980s. This is exceptionally significant as the area has little recorded on the prehistoric occupation of the area. Though this site demonstrates a presence of activity or settlement in the surrounding area, the location of the settlement is still unknown.

The phasing for the excavated human remains was restricted by severe truncation and the limitations of the areas excavated, so it has been simplified into three broad categories: Uncoffined (c.1100- 1485 AD), Coffined (c.1485-1900 AD) and Non-burial/Other (see Figure 19). Further subdivisions within these categories was based on residual artefactual evidence or historical records of known graves. The most significant results from this project were gained from the detailed osteological analysis which is included in its entirety in Appendix 1.

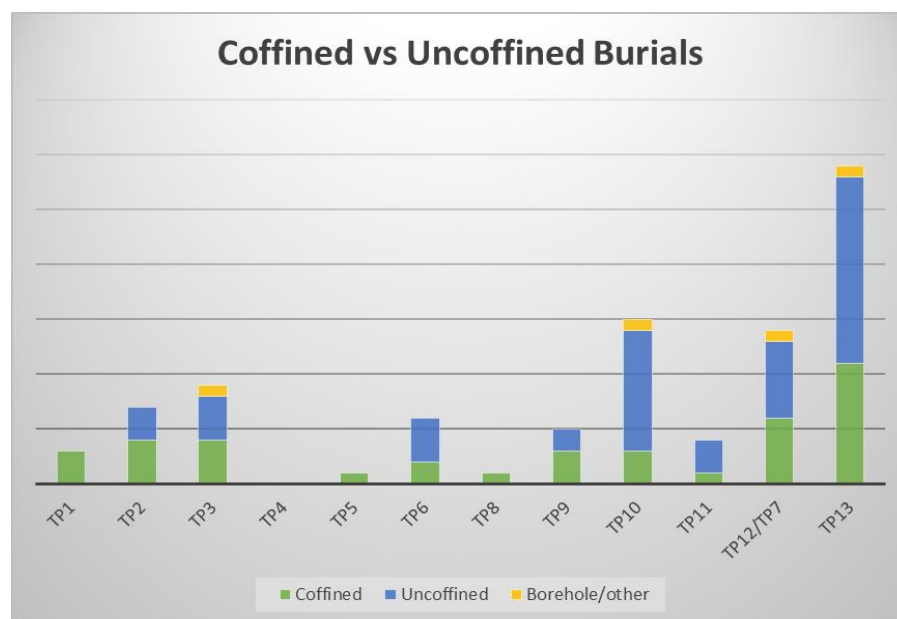


Figure 19. Distribution chart of burials and phasing by Test Pit.

Residual material

There was a low-level background presence of late Bronze Age or early Iron Age pottery. This was interpreted to be residual in the fill of the more recent burials, but still indicated that there was settlement activity in the area prior to the establishment of the church.

Evidence for extensive ground reduction noted within the investigation area from the addition of the office in 1914 after the main building was burned down. Traditionally, charnel pits usually occur when burials are too close to the surface and human remains are exposed. It has also been established that it was common practice for churchyards to raise the contemporary ground level with the importation of new soil (Harvey. 2014: 6).

Further monitoring was undertaken for the drainage trenches associated with the septic tank (FP13) and the location of the new accessible toilet (FP4). These drainage trenches were relatively shallow and therefore did not extend below the disturbed churchyard soils or disturb any archaeological features or remains.

Uncoffined Burials (c. 1100- 1485 AD)

As shown in Figure 3, the majority of the articulated burials encountered were uncoffined or had been too badly truncated by subsequent burial activities for coffin evidence to survive. Based on the limited area exposed during the excavation of the foundation pits, the stratigraphic relationships were complex and often the only source to establish any chronology.

Burials with Evidence of Pre-Medieval Activity

The graves with prehistoric pottery in their fills were all post-medieval as identified by the associated coffins found with each burial, therefore the pottery was positively determined to be residual. However, the frequency of the material present indicates that there is a strong likelihood that there was settlement or activity in the vicinity during the late Bronze Age or early Iron Age.

The paucity of remains which could potentially date from the Saxon period is notable in the context of a known abbey church mentioned as early as 1121 when it was gifted to Reading Abbey by Henry I (Gray & Griffiths 1986: 26). However, there were two uncoffined burials which presented a strong case for a potential Saxon date based on tooth wear: SK70 and SK74 (for detailed discussion see Appendix 1).

Coffined Burials (c. 1485-1900 AD)

The rest of the burials were in a mix of clearly coffined graves – indicated by furniture comprising grips, upholstery pins and occasionally plates, or nails, associated with the construction of the coffin itself – and graves where individuals had been interred in shrouds – evidenced by shroud pins, buttons and other clothing paraphernalia; there were a number of graves where the evidence for such burial traditions is less certain, and may have involved burial in a shroud with no fastenings, merely wound round the body.

It is important to bear in mind that ‘For most parish churches... the coffin was a reusable resource, used to bear the corpse... to the church or chapel where the funeral service was to be conducted’ (Gilchrist & Sloane 2005: 111) and that consequently it is unsurprising that we have no evidence for coffins for many of these individuals. Only two examples of post-Reformation parish coffins survive in England (Gilchrist & Sloane 2005). The continued use of parish coffins into the post-medieval period highlights the degree of continuity between the periods. As a result it is unsurprising that burials, which are not high status, are not easily distinguishable in the pre-modern period. Moreover, in a rural cemetery such as St Mary's Church, Wargrave, a high degree of continuity of practice is to be expected.

Although the churchyard soil layer seemed to be uniform across the whole of the area impacted, it is possible that the norther portion of the monitored area may have been a redeposited layer from an earlier episode of building works resulting in ground-raising deposition of excavated material across the graveyard. Later, a secondary deposition of the charnel-laden material excavated from the foundations of the new addition of the office in the early 20th century would explain why the landscape was at a slight elevation as it neared the structure of the church near the North Aisle.

As a result, the burials are treated as a homogenous group of post-medieval to early modern burials, with the caveat that there may well be some earlier burials. These may include

burials as early as the Late Saxon period but, due to lack of associated finds, without scientific dating this cannot be assured.

Undated Features

There was a single undated ditch which was partially caught in the northern sections of both FP5 and FP6. The ditch stratigraphically predates all of the burials in both test pits where it was encountered. In FP5, the ditch was cut by the only historic charnel deposit encountered on site, (5/08), which was itself underneath the only articulated inhumation excavated in FP5, SK72.

The ditch ran on an east-west alignment parallel to the church and was approximately 2m away from the north wall of the 1914 office addition. Ditch cut 5/07 and 6/26 were excavated manually to the fullest extent which was encountered in each test pit. Based on the evidence encountered archaeologically, this ditch was over 10m long and over 0.5m wide. As it was not seen in any of the other test pits, however it appeared to be on a slight angled trajectory which means it may have missed FP10 (the only other test pit which would have potentially caught it based on its alignment). The eastern-most section of the ditch was in FP5 and the base was not encountered due to it being outside the limits of excavation, but the sides were at c. 60° angle and it is likely based on the relative depth of the feature and the known depth of the water table, that the base of the ditch was close at the limit of excavation; the wester-most section of the ditch in FP6 only encountered a section of the shallow sloping side of the ditch, the rest was outside the limit of excavation. This would indicate that the ditch was skewing at an angle which would have not been seen in FP10 if the hypothetical line was carried forward.

While it is clear that a possible boundary or drainage ditch is indicated by the presence of the ditch, what is inside, or indeed outside, the ditch is unclear. It is possible that the ditch defines the minster enclosure – although this is unlikely given the narrowness of the ditch; or perhaps it defined an enclosure for St Mary's. It is also possible that this ditch predates any church structure and may be indicative of earlier settlement at this location.

However, as the ditch runs at an approximate parallel line to the extant church structure, the most likely interpretation is that the ditch corresponds with some earlier phase of use associated with the church. While there is some slight deviation in the alignment of the church to the ditch, it is commonly accepted that early building techniques relied on sun position to establish polar orientation. Therefore, if an earlier structure was built in winter but the later one was built in summer, then the orientation would be off alignment. Furthermore, it has been suggested that though alignment based on an east-west sunrise/sunset was traditionally thought to be set strictly on the solstice positions, many examples exist of churches using their patron saint's fest day rather than the solstice (Benson 1956).

It should however be noted that more recent studies have demonstrated that while misalignments indeed exist, there is no correlation to the saints' feast day (Hinton 2006). Hinton (2006: 222) states that, "The results of this survey confirm that there was an intention on the part of church builders to align their churches roughly with east. Accuracy was not apparently paramount – an approximate direction appears to have been sufficient." This may be the case with St. Mary's as it is misaligned to some of the earlier burials. This may also explain why a ditch that is potentially associated with an earlier Saxon church might be off-set slightly to the current structure.

Architectural Elements

Most notably, the archaeological information gained pertaining to the architecture of the earlier structures on this site could potentially support theories suggesting that there was a late Saxon or early Norman church on this site (AD 1200-1299). Further evidence supporting this was found in the skeletal remains of two individuals which demonstrate traits suggesting that they are of an early medieval provenience. Without radio carbon dating this remains speculative, however, should the remains confirm the suggested date, this would provide strong support that the graveyard has been in constant use since the early medieval period.

Conclusion

The northern churchyard location, coffin fittings & historical records all suggest that this was largely a working class assemblage (agrarian and riverine). This is supported by the osteological analysis of the skeletal remains showing muscle insertion sites which indicate repetitive strenuous activity in most individuals. However, the lack of deficiency diseases and average stature suggest that the Wargrave population was not particularly deprived.

There were two unusual fractures (Shepherd's and avulsion fractures) which appeared to be occupational (spinning/weaving and rowing) which further supports the interpretation of the assemblage being comprised largely of working class.

Although numerous small archaeological excavations have been undertaken in country churchyards across Britain, many skeletal assemblages from these excavations are too small for meaningful analysis. Although not large by urban excavation standards, the 89 Wargrave skeletons in this analysis constitute a fairly large and therefore, significant assemblage when exploring country life and health in the past. However, this is a small sample of the whole population of Wargrave over 1,000 years & burial records have indicated that it may not be representative. This archaeological and osteological study has provided a window into the lives health and activities of the common people that lived in Wargrave in the past, and has demonstrated some new insights into how the lifestyle, occupation and activities of past parishioners impacted on their health and longevity.

7 ARCHIVE

Archive Contents

The archive consists of the following:

Digital record

The project brief

Written scheme of investigation

The project report

The primary site record

Physical record

None retained

The archive currently is maintained by John Moore Heritage Services and will be transferred to an appropriate accepting body when one becomes available.

8 BIBLIOGRAPHY

- Advisory Panel on the Archaeology of Burial in England (APABE), 2017. *Guidance for Best Practice for the Treatment of Human Remains Excavated from Christian Burial Grounds in England*.
- Aultman, J. and Grillo, K. 2003. *DAACS Cataloging Manual: Buttons*.
- Anderson T, and Boston C. 2018. Human remains. In: Soden I, editor. *Excavation of the late Saxon and medieval churchyard of St Martin's, Wallingford, Oxfordshire*. Oxford: Archaeopress Archaeology. p 47-68.
- Aufderheide AC, and Rodriguez-Martin C. 1998. *The Cambridge encyclopedia of human paleopathology*. Cambridge: Cambridge University Press.
- Bailey, G. 1993. *Detector Finds 2*. Greenlight Publishing, Witham.
- Bailey, G. 2004. *Buttons & Fasteners 500BC-AD1840*. Greenlight Publishing, Witham.
- Bashford, L. and Sibun, L. 2007. Excavations at the Quaker Burial Ground, Kingston-upon-Thames, London, in *Post-Medieval Archaeology* **41/1**:100-154.
- Benson, H 1956. 'Church orientations and patronal festivals', *Antiquity Journal*, 36, 205–13.
- Boston, C., Boyle, A. and Witkin, A. 2006. *In the vaults beneath – Archaeological Recording at St George's Church, Bloomsbury*. Oxford Archaeology.
- Boston, C. 2008. *Rycote Chapel. Coffins in the Crypt*. *Archaeological Watching Brief Report*, Oxford Archaeology Report No. 3777.
- Brickley, M. & McKinley, J. I., 2004. *Guidelines to the Standard for Recording Human Remains*. Institute of Field Archaeologists Technical Paper 7, BABAO University of Southampton.
- Chartered Institute for Archaeologists, 2014. *Standard and Guidance for Archaeological Watching Briefs*.
- Clough, S. 2010. The coffins and coffin furniture, in McCarthy R, Clough S, Norton A, *Excavations at the Baptist Chapel Burial Ground, Littlemore, Oxford*. Archaeological excavation report.
- Cox, A. 1996a. Post-medieval dress accessories from recent urban excavations in Scotland, *Tayside and Fife Archaeological Journal*, vol. 2.
- Cox, M. 2001. *Crypt Archaeology: an approach*. Institute of Field Archaeologists Technical Paper 7. Reading.
- Cox, M. 1996. *Life and Death in Spitalfields 1700–1850*, York: CBA.
- Entwistle, R., 2002. *A Desktop Assessment, Geophysical Survey and Field Evaluation at St Mary's, Wargrave*. Unpublished Berkshire Archaeological Services Report.
- Gilchrist, R., & Sloane, B., 2005 *Requiem The Medieval Monastic Cemetery in Britain*. London: Museum of London Archaeological Services.
- Gray R, and Griffiths S. 1986. *The Book of Wargrave Wargrave Local*. History Society Publication;Oxford University Printing House.
- Harvey L., Denis S., and Williams G. 2014. *An archaeological excavation at All Saints' Church, Faringdon, Oxfordshire*. Wheatley, Oxfordshire: unpublished site report prepared by John Moore Heritage Services.

- Hinton, I., 2006. Church Alignment and Patronal Saint's Days. *The Antiquaries Journal*, 86, 206–26.
- Ives, R. and Hogg, I. 2012. *St John's School, Peel Grove, Bethnal Green, London Borough of Tower Hamlets: A Post-Excavation Assessment Report*. AOC Archaeology Group.
- Janaway, R. 1998. An introductory guide to textiles from 18th and 19th century burials, in Cox, M. (ed), *Grave Concerns: death and burial in England, 1700-1850*, CBA Research Report 113.
- Lambrick, G. 1984. Pitfalls and Possibilities in Iron Age pottery studies: experiences in the Upper Thames Valley. In Cunliffe, B., and Miles, G. (eds) *Aspects of the Iron Age in central southern Britain*, Oxford University Community Archaeology Monograph 2, Oxford, 162-77.
- Leivers, M. forthcoming. Excavations at Heathrow. Volume 2. Framework. PCRG 1997. *The Study of Later Prehistoric Pottery: Guidelines for analysis and publication*. Prehistoric Ceramics Research Group Occasional Papers 2, Oxford.
- Litten, J. 1991 *The English way of death - the common funeral since 1450*, Robert Hale, London.
- McCarthy, R., Clough, S. and Norton, A. 2012 The Baptist Chapel burial ground, Littlemore, Oxford. *Post-Medieval Archaeology* 46/2.
- McKinley, J. & Roberts, C. 1993. *Excavation and post-excavation treatment of cremated and inhumed human remains*. Institute of Field Archaeologists Technical Paper 13.
- Mellor, M., 1994, 'Oxfordshire Pottery: A Synthesis of middle and late Saxon, medieval and early post-medieval pottery in the Oxford Region', *Oxoniensia*, 59, 17–217.
- Miles, A. 2008 Coffins, in Cowie R, Bekvalac J and Kausmally T, *Late 17th- to 19th-century burial and earlier occupation at All Saints, Chelsea Old Church, Royal Borough of Kensington and Chelsea*. MOLAs Archaeology Studies Series 18.
- MoLA 2018. *Medieval and post-medieval pottery codes* [https://www.mola.org.uk/sites/default/files/resource-downloads/Medieval%20and%20post-medieval%20pottery%20codes%20in%20Word 0.doc](https://www.mola.org.uk/sites/default/files/resource-downloads/Medieval%20and%20post-medieval%20pottery%20codes%20in%20Word%200.doc) accessed 26/04/2018).
- Monkton, H. W., (ed.), 1903 *The Geology of the Country Around Reading (Explanation of Sheet 268)*, Memoirs of the Geological Survey of England and Wales.
- Reeve, J. and Adams, M. 1993, *The Spitalfields Project: Across the Styx. Volume 1: the archaeology*. CBA Research report 85. Council for British Archaeology.
- Richmond, M. 2007 The Coffin furniture, in Bashford, L, Sibun, L *Excavations at the Quacker Burial Ground, Kingston-upon-Thames, London*. Post-Medieval Archaeology 41/1.
- Rugg, J. 1999 From reason to regulation: 1760-1850, in Jupp, P, and Gittings, C (eds) *Death in England- an illustrated history*, Manchester University Press.
- Seetah, K. 2009 *The importance of cut placement and implement signatures to butchery interpretation* (http://www.alexandriaarchive.org/bonecommons/archive/files/archivefiles_downloadseetah_textimages_204_7cd9b26908.pdf (accessed 30/09/2015)).

- Shennan, S. 1981 Settlement history in east Hampshire in East Hampshire, in *The Archaeology of Hampshire from the Palaeolithic to the Industrial Revolution* (eds S J Shennan and R T Schada-Hall), Hampshire Field Club Archaeological Society Monograph 1, 106-21, Winchester.
- Sumbler, M.G., 1996. *British Regional Geology: London and the Thames Valley*, 4th edition. British Geological Survey, London.
- Webb, H. 2007 *St Clement's churchyard, The Plain, Oxford*. Oxford Archaeology Report No. 3782

APPENDIX 1: **Human Remains Report**

St Mary's Church, Wargrave: The human skeletal remains
by Dr Ceridwen Boston

Introduction

Eighty-nine articulated skeletons and a large quantity of charnel were excavated by John Moore Heritage Services in the northern churchyard of St Mary's Church, Wargrave, Berkshire, in 2018. The excavation and watching brief took place in advance of the construction of an extension to the existing church. The new construction rests on 12 concrete plinths or footings, which extend to the natural alluvium beneath the churchyard soil. Twelve test pits (the locations of the concrete plinths) and a large service trench for a waste pit were archaeologically excavated in advance of construction. The skeletons of past parishioners were recorded and then removed for processing and osteological analysis on site. They will be reburied within the churchyard (as stipulated in the Church of England faculty).

Dating of the burials

This osteological report describes the composition of the skeletal assemblage as a whole, in terms of age, sex, stature and skeletal and dental health, and compares demography of the assemblage to historical records, primarily parish burial records of St Mary's Church (1538- 1899). It is highly probable that the churchyard was used a place of burial from the foundation of the church on this site, sometime before 1121 AD (Gray and Griffiths 1986), and possibly as early as the 10-11th centuries. It is postulated that a Saxon predecessor (probably of timber) stood on or near the site of the present church or on adjacent Mill Green (John Moore Heritage Services 2017). Burial in the churchyard continues to the present day. Burials known to date to within the last 100 years were not archaeologically recorded or excavated (in accordance with conditions of the Human Tissue Act 2004) and were either left *in situ*, or were claimed by living relatives for reburial elsewhere. Thus, it is assumed that the skeletons excavated within the northern churchyard in 2018 show a temporal range of 800-1,000 years.

With the exception of coffins, very few graves contained dateable artefacts, and without radiocarbon dating it was very difficult to date individual burials. Crude dating of each burial was made from the presence or absence of a coffin (usually determined by coffin nails located around the skeleton). It is unusual for extramural burials of the late Saxon and medieval periods to be coffined- the overwhelming majority were buried naked within a shroud (Gilchrist and Sloane 2005). Burial within a coffin became more popular in Tudor times and by the 17th century burial within a plain trapezoid coffin was normative (Litten 1991). From the 1730s, the invention of die stamping metal plates enabled an elaboration of coffin decoration. From this period onwards, all but the most destitute's coffins were covered in cloth (usually baize or velvet), secured with upholstery studs (often in rows or elaborate patterns) and decorated with decorative stamped metal plates (escutcheons, grip plates and lid motifs), grips and/or *depositum* metal plates (most commonly breastplates) engraved or painted with the name, age and date of death of the deceased (Cherryson et al. 2012; Litten 1991). The number and the metal used in the coffin fittings broadly indicated the affluence and status of the deceased and/or mourners (*Ibid.*), with brass and lead fittings used in more expensive coffins, and iron in more modest ones. Completely unadorned coffins of this period generally represent the extremity of poverty, most commonly used in 'pauper burials' of those 'dying on the parish' in workhouses or in other institutions, such as asylums, or indigent strangers to the parish buried at the parish's expense.

On the basis of this broad schema, the 90 burials excavated in 2018 were broadly dated to late Saxon or medieval periods (c. 1100- 1485 AD) if uncoffined, to the early post-

medieval (1485-1730s) period if in plain coffins, and to the later post-medieval period (1730s- 1900) if in decorated coffins. The osteological analysis below presents the data by total assemblage and according to these three approximate time periods.

Historical background

Burial registers of St Mary's Church, Wargrave (1538-1899)

The Church of St Mary, Wargrave, is highly unusual and very fortunate in having an extant continuous record of baptisms, banns, marriages and burials within the parish dating from 1538 to the present day. These records are an invaluable resource with which to explore the social history of the parish, yet to date have not been systematically analysed. Unfortunately, in-depth historical analysis lies beyond the scope of this report. However, limited analysis of burial records dating from 1538 to 1899 was undertaken in order to answer specific questions raised by the osteological analysis. Peter Delaney of the Wargrave Historical Society has generously shared his research for the years 1538-1789. Analysis of the burial registers of 1790-1899 was undertaken by Ceridwen Boston. These data is presented below in Figure 20 and Table 7.

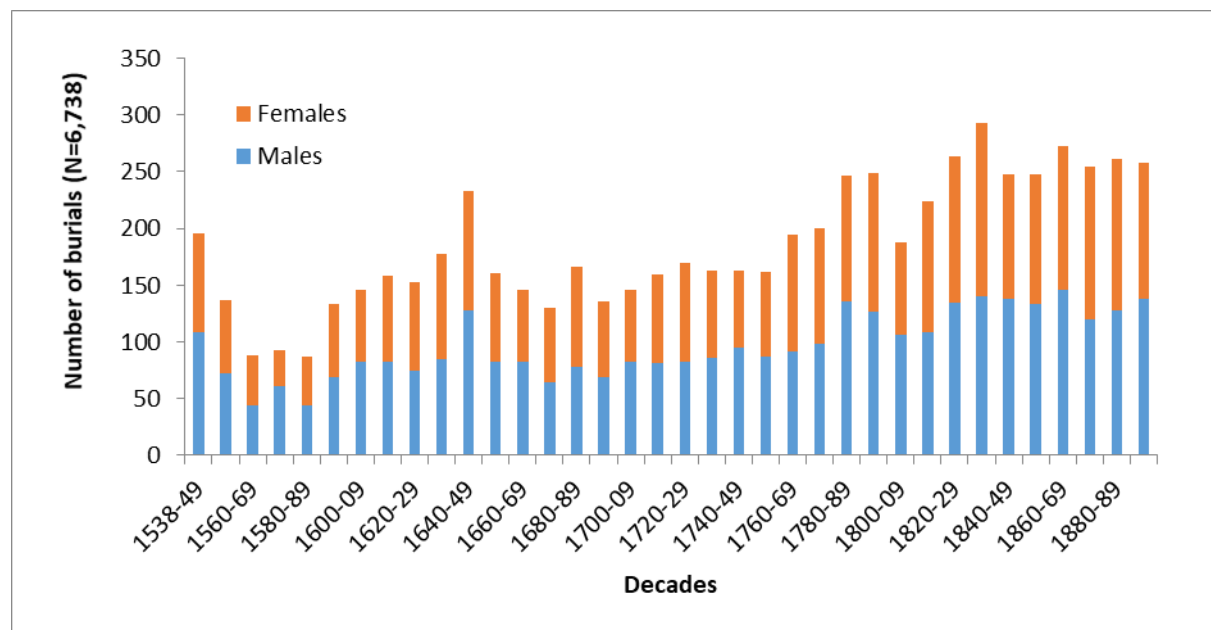


Figure 20: Burials recorded in the St Mary's Church records by decade (1538-1899); N= 6,738)

A total of 6,738 burials was recorded in this period. Unfortunately, no records survive to explore mortality patterns in the preceding late Saxon and medieval periods, during which it is assumed burial around the church building took place. Figure 20 shows the fluctuation in burial numbers and sex of the deceased by decade from 1538 to the end of the 19th century.

A peak in deaths is evident in the first two decades of records (1538-1549 and 1550-59), numbering 196 and 138 burials, respectively. This was followed by a decline in burial numbers (87- 93 per decade) until the end of the 16th century. The reason for the high mortality in the earlier part of the 16th century may well be associated with poor harvests and/or outbreaks of disease in both humans and farm animals. Noah Webster (1758-1843) collated historical evidence for natural disasters (such as volcanic eruptions, earthquakes, droughts and severe winters) with the outbreaks of disease in Europe from the Middle Ages

to the 19th century. He reported that in 1537, a wet summer and a hard winter had been associated with outbreaks of disease in the human population, and that in 1538 '*a mortal dysentery raged all over Europe*' (Webster 1758-1843, 154). In 1540, '*there was a terrible drouth. In England, a pestilential ague and a dysentery were epidemic and mortal*' (*Ibid.*). However, it was in the years 1542-45 that mortality rates in Wargrave were particularly high. Webster reported that 1543 was particularly wet and cold, with '*a great mortality amongst cattle*', whilst in 1543 plague raged in London and again in 1548. Given the busy river trade with London in this period, with Henley being an important centre of the grain trade, it is quite probable that epidemics in the metropolis readily spread up river to Henley and thence, to Wargrave. It is certainly true that a brief rise in mortality in Wargrave from 14 to 25 to 14 burials occurred in 1549. Church registers suggest that around this time the population of Wargrave parish numbered approximately 700 individuals (Berkshire Family History Society 2012).

In contrast to the above, the number of burials in Wargrave in the latter half of the 16th century in the reign of Elizabeth I dropped into single figures for many years- the lowest mortality figures throughout the post-medieval period. This was followed by a gradual rise in burial numbers in the early 17th century, rising steeply in the decade 1640-49. This decade included the English Civil War (1642-46), which wreaked tremendous hardship and death not just on soldiers, but also on the civilian population. There was a rise in mortality in Wargrave during these years, peaking in 1644 with 68 deaths. The year 1644 was a particularly turbulent one in the local area. In 1642, with London in the hands of Parliament, King Charles established his capital in Oxford. Geographically placed between the two cities, downriver on the Thames from the important towns of Abingdon and Wallingford and close to the strategic Goring Gap and Royalist-held Reading, Henley was an important local centre held by Parliament. It was also critically important in supplying grain and wood to London. In 1644, Royalist Reading and fortified riverside houses, such as Greenlands located slightly downstream from Henley and Wargrave, were seized by Parliamentarian forces (Townley 2009). Phyllis Court in Henley was fortified and manned by a Parliamentarian garrison '*to watch the garrison at Greenlands*' and Henley remained in Parliament's hands until the end of the conflict. Between 1642 and 1644, corporate minute books of Henley traders complain of the '*great peril caused by passing to and through our country of ... disorderly trains of armed men*' (Townley 2009; 87), including those of Prince Rupert. Soldiers on both sides of the conflict were often poorly paid and provisioned and 'lived off the land' by pillaging food supplies and livestock from townspeople and farmers alike. In Henley, the hungry Phyllis Court garrison became notorious for pillaging and mutinous behaviour (*Ibid.*). The combined effect of soldiers commandeering the food supplies of local people, the difficulties of harvesting crops with so many men away at war, and disruption to trade had catastrophic effects on communities in the region. In addition, soldiers in this conflict suffered high rates of infections (probably typhus and dysentery), (Barratt 2015) and spread these to the civilian population. Local centres, such as Abingdon further up the Thames, suffered near- and actual starvation, the year 1644 being most severe (Dils 1989). The effects of the Civil War on Wargrave's population is less well documented, but located between Henley and Reading, it is probable that its inhabitants suffered considerable hardship in those years. The Wargrave burial register records a rise in annual deaths from 11 in 1640 to 22 in 1642, then 37 in 1643, and 68 in 1644. Numbers then drop away steeply to 13 in 1645, and 16 in 1646. Most of the dead were probably civilians, as there was only slightly more males (n= 75) to females (n= 71) buried in the Civil War years. However, parish registers do record the burials of two soldiers in 1643 and one in 1646. Throughout the burial registers there are notes on

individuals who were not of the parish. Presumably these three soldiers were such strangers.

Following the Civil War, mortality in the parish fluctuated slightly over much of the later 17th and first half of the 18th centuries, but broadly stayed constant between 10 and 20 deaths per year, or 130 to 160 per decade. Interestingly, in 1666, when Londoners were dying in their thousands from the bubonic plague, no corresponding rise in mortality was noted in Wargrave, suggesting that the disease did not spread upriver to the village.

From the latter half of the 18th century, there was a steep rise in burial numbers from 140-160 per decade to approximately 200-250 (with the exception of 1800-1820, decades in which Britain was embroiled in the Napoleonic Wars). Numbers then plateaued at 250-270 burials in the Victorian period. A peak of 293 deaths occurred in the 1830s, affecting males and females alike. The first of four major outbreaks of the Asiatic cholera or *Cholera Morbus* occurred in Victorian Britain in this decade, causing hundreds of thousands of deaths across the country. Although the greatest mortality occurred in cities, cholera outbreaks did spread to rural areas. For example, a plaque on the north side of St Peter and St Paul's Church, Wantage, Oxon. (more remote than Wargrave), commemorates the burial of 19 parishioners who died of the Asiatic cholera in September and October 1832. Ascribing the raised mortality rate in Wargrave in this decade to cholera may be speculative and overly simplistic, but Wargrave's proximity to Henley and thence to London, makes a cholera outbreak in the village likely.

The later 18th and 19th centuries saw increasing hardship for agricultural workers, beginning with the enclosures of common land, on which parishioners grazed animals, collected firewood and sometimes planted crops. Although one enclosure in Wargrave is recorded in the 1770s, it was the 1814 Act for Enclosing Land in Wargrave that resulted in considerable common land being taken into private ownership. The year 1818 saw enclosure awards of at least 28 parcels of land in the parish (Berkshire Record Office consulted 2018).

Another factor causing tremendous rural hardship and probably affecting the health and survival in agrarian communities such as Wargrave, were the three consecutive years of poor harvests from 1828 to 1830, which raised the price of bread and increased unemployment (Chambers 1999). These crop failures, worsening rural poverty, reduced poor relief and agricultural mechanisation culminated in the Swing Riots of 1830, in which farm labourers banded together, demanding better pay and working conditions, and reform of the Poor Laws. Machine-wrecking, especially of threshing machines, was a major feature of the riots. This rural unrest flared up in many southern and eastern counties. In Berkshire, it concentrated in the west of the county, near Newbury and Hungerford. However, incidents of machine wrecking did occur in Waltham St Lawrence and Binfield near Wargrave (Chambers 1999). In the former, one Martha Davies reported that forty men came up from Kent to support rioters led by her neighbour Solomon Allen. They broke the machine and left when 'they had had as much beer as they wanted'. At Binfield, they broke a machine belonging to one Richard Glasspool (*Ibid.*).

On 22nd April 1831, Sir Morris Ximenes, Magistrate of Berkshire and of a prominent Wargrave family, stated before a Select Committee in the House of Lords looking into poor relief in England, that the average able-bodied labourer in Wargrave earned nine to 10 shillings a week- insufficient to support a family of five or six, and was reliant on poor relief to make ends meet (House of Lords 1831). By 1777, Wargrave had a workhouse on Wargrave Hill (now the site of Elizabeth Court), which housed 50 inmates. Sir Morris Ximenes stated that inmates were '*those who are old and decrepit, and children who have no persons to care for them, and if persons cannot find houses, which notwithstanding the*

number of houses is sometimes the case, we allow them to come in' (Ibid., 435). Although Sir Morris described the workhouse as clean and well-run, by 1846, Edwin Chadwick reported that it was overcrowded, damp and poorly ventilated, and lacked an infirmary or fever wards (King 2016). In 1835, the Wokingham Poor Law Union Workhouse was established, and in the following decade inmates of Wargrave's parish workhouse were gradually transferred there. The former building was subsequently converted for use as the Reading and Wokingham District School. The Wargrave parish burial records record the burial of many workhouse inmates, initially of the parish workhouse, and from 1849, of parishioners who died in the Wokingham Union workhouse, and presumably were returned to Wargrave for burial. In line with Sir Morris' description above, most workhouse burials were babies, children or older adults (many dying in their 70s and 80s). St Mary's burial register of 1850 records 11 burials from Wokingham Union workhouse- possibly due to a disease outbreak (e.g. smallpox). Children from Wargrave District School are also recorded in the registers from 1850. One Arthur Herbert Drive (buried 14 December 1866) of the 'school' was aged only two months.

The Domesday Book of 1086 indicates that the Manor of Wargrave was approximately 5,000 acres, with an estimated population of 250-300 inhabitants (Gray and Griffiths 1986). From baptism and other records of St Mary's Church, it is estimated that by the mid-16th century the population had grown to approximately 700. This number stayed fairly constant until the latter half of the 18th century, after which it gradually increased (Berkshire Family History Society 2012).

Nationally, there was an extremely steep, almost exponential national growth in population in Britain in the later 18th and 19th centuries. However, this growth was not evenly distributed across the country. In rural areas, the combined effects of the enclosure of common land, mechanisation of agriculture, the collapse of cottage industries (such as spinning and weaving) and low wages forced large numbers of agricultural labourers to leave the countryside for the burgeoning industrial centres of London, the Midlands and the North. Like other predominantly agricultural counties, Berkshire's population growth in the later 18th century was amongst the slowest in England: 13.1% from 1761 to 1801. This is in contrast to 51.7% in London and 74% in the industrial counties of the Black Country, Yorkshire, Lancashire and Cheshire (Wrigley 2007). More locally, the population of Wargrave parish in the 19th century has been estimated at 1,134 in 1801, rising to 1,423 in 1831 and 1,806 in 1861 (Wordie 2000).

If the above population estimates for Wargrave are accurate, it would appear that large-scale depopulation of the parish did not occur. Indeed, there was a gradual population growth over the 19th century. In concert, burial numbers also increase in this period. The construction of the Great Western Railway in the 1840s resulted in a falling-away of the Thames river trade with London, but opened up new opportunities, which probably contributed to the local economy of Wargrave. Rapid rail transportation facilitated trade in fresh produce to the metropolis. The railway also transported large number of holiday-makers from London, and Wargrave became a popular rural and riverside retreat for jaded Londoners seeking a bucolic idyll (Gray and Griffiths 1986). From the 1850s, many ancient farmhouses and workman's cottages in the village were demolished and replaced by fine new riverside houses and boarding houses, drastically altering the appearance of the village (*Ibid.*). Presumably, this tourist trade expanded the non-agrarian economy of the village, and rural depopulation, so widespread in Victorian Britain, may have been balanced or slowed in Wargrave as a result. However, population growth in Wargrave occurred much more slowly than the national population explosion, suggesting multiple forces at work in the parish.

Occupation and industry in Wargrave

Burial registers indicate the occupation of only a few parishioners interred within the churchyard, and are by no means representative of the whole community- mentioning mostly those of higher rank. These included army and naval officers, vicars, surgeons, an heiress, a taylor, a barrister, a parish clerk, a brazier, a bricklayer, soldiers, a former pew-opener, a tramp and two travellers. A detailed study of the marriage registers of St Mary's Church, in which the occupation of the bride and groom is given, would provide a much more detailed picture of occupations within the parish in the later post-medieval period, but sadly, lies beyond the scope of this report.

Until the mid-19th century, the economy of Wargrave was principally agricultural with farming and rural crafts as the principal occupation of the inhabitants (Gray and Griffiths 1986). One historical study on late 18th century Berkshire estimated that 45% of all adult men were directly engaged in farming (Wrigley 2007). The parish of Wargrave includes a wide floodplain, in which braided channels and marshes of the Thames and Loddon provided fish, wildfowl and grazing; steep wooded slopes that provided wood and grazing for pigs and cattle, and open fields for agriculture and sheep grazing above the flood plain and on the crest of the chalk hills.

Wargrave's proximity to the Thames and Loddon played an important role in the economy of the parish from earliest times. The rivers supported a mill in the village from Saxon and medieval times (believed to be located on the western edge of Mill Green), tanneries in the 18th- 19th centuries and from the mid-19th century, the tourist trade (Gray and Griffiths 1986). A document recording the ownership of Wargrave by Edith, wife of Edward the Confessor, describes that the Hundred of Charlton, which included Wargrave, supported three fisheries rendering 3,000 eels (*Ibid.*). The braided river channels at Wargrave continued to be important for fishing using weirs, fish- and eel traps for many centuries. In fact, the proliferation of such structures in the Thames upstream of Henley from the late 11th to 14th centuries made navigating the river increasingly difficult and expensive (Townley 2009). Mill ponds and later flashlocks also choked the river. Although it does appear that some sizeable craft sometimes penetrated as far upstream as Culham, even to Oxford, by the late medieval period, Henley became the highest navigable point on the Thames (*Ibid.*). Being located close to two major roads, goods hauled overland could be offloaded at Henley and shipped by barge to London- a much cheaper and less arduous form of transport. Thus, from the Middle Ages to the opening of the railways, Henley was a critical hub in the busy Thames Valley corridor trade, transporting grain, wood, wool and other essentials downstream to London, and bringing inland luxury items, such as wine, spices and silk, as well as iron, coal and herrings (*Ibid.*).

Vessels plying the Thames and inland waterways were generally large, flat-bottomed barges (known throughout the Middle Ages as 'shouts'). From the 17th to 20th century, the most common barge on the Thames was the 'Western barge', which became very much larger over time, some measuring nearly 130 feet long by 18½ feet wide, with a draught of no more than four feet (Townley 2009). It seems that journey times did not change from the late medieval period to the late 18th century. Travelling downstream from Henley to London took several days, using the craft's square-rigged sail and the river current, and required only two men to steer. The upstream journey was much slower (four to six days) and more arduous, requiring rowing, poling or hauling from the bank. Medieval illustrations suggest that towing a barge upriver was undertaken by men hauling on ropes slung over their shoulders. From the 1730s, horses and mules replaced this manpower (*Ibid.*). However, on difficult stretches of the river, back-breaking towing by 'haulers' or 'halers' was still necessary in the 18th century. Approximately six halers would drag the

barge upstream, each wearing a leather breast-strap with a small harness rope, which could be attached to the tow-rope. The largest 18th century barges required a crew of six men and a boy, the steersman assisting the bargemen, who with long ashen poles kept the boat in the proper navigation channel (*Ibid.*). A sail (initially square-rigged, later a triangular sprit-sail) was also used, when possible. Given its close geographic proximity to Henley, it seems highly probable that many inhabitants of Wargrave parish supplied agricultural produce to Henley traders, and some men may well have worked as bargemen in the busy river trade. Following the construction of the Great Western railway, river trade dramatically declined and many river-men in and around Henley were employed in recreational boating instead (*Ibid.*).

Demography of the burial population from parish registers

The sex of the deceased recorded in the Wargrave burial registers could be ascertained from the Christian name in all but 34 entries from 1538 to 1899. Uncertainty in those 34 cases was due to illegibility of the register, the name was not given, or the Christian name was not obviously male or female. One such was an infant, named only as 'Tiny'.

In total, 3,486 male and 3,218 female burials of all ages were recorded (a male: female ratio of 1: 0.92) (Figure 21; Table 7). In the 16th century, there were slightly more males to females (1:0.84), but in the rest of the post-medieval period, the proportion remained constant at 1:0.92- 1:0.94.

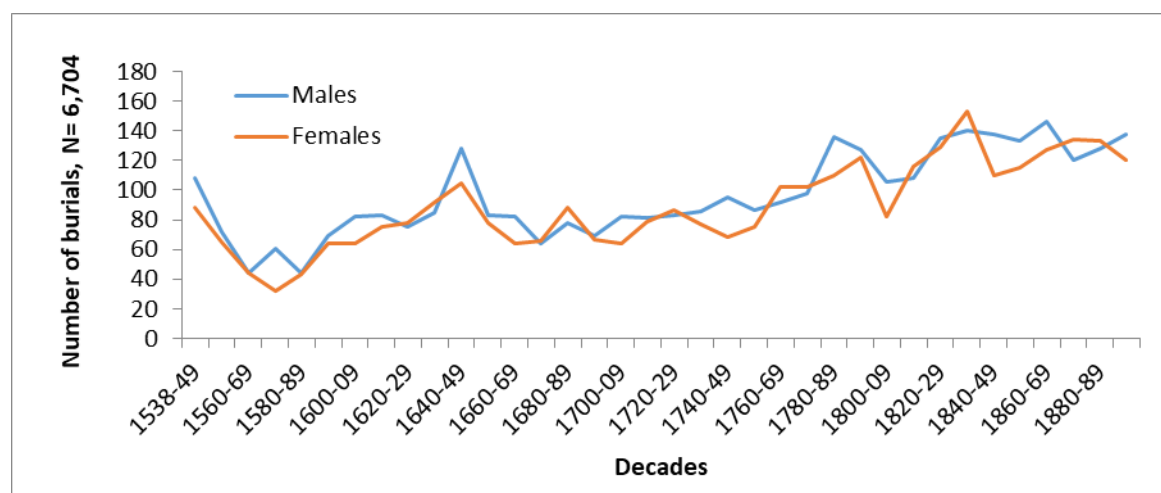


Figure 21: Number of male (in blue) and of female (in brown) burials in Wargrave parish by decade, calculated from burial registers of St Mary's Church, Wantage, 1538-1899, N= 6,704.

Years	Males	Females	Uncertain	Male: female ratio	Total
1538-1599	398	336	1	1: 0.84	735
1600-1699	829	777	12	1: 0.94	1618
1700-1799	967	886	10	1: 0.92	1862
1800-1899	1292	1219	11	1: 0.94	2521
Total	3486	3218	34	1: 0.92	6736

Table 7: Number and ratio of males and females of all ages by century (1538-1899); calculated from the burial registers of St Mary's Church, Wargrave; N= 6,736

Before 1813, the age-at-death of the deceased was not recorded, other than where the deceased was 'an infant'. Thus, it was not possible to determine the relative sex distribution in adults, adolescents or children.

It is not altogether clear at what age a baby ceased to be categorised as 'infant' in the earlier burial records. From 1813, the burial registers recorded age-at-death. When comparing the proportion of infant deaths in the parish from 1813-99 with earlier registers, it is assumed that in the latter 'infant' referred to any child younger than two years (the average age at which an infant is usually weaned, can walk and talk and has teeth). The proportion of infant deaths to all deaths in Wargrave in the years 1790-1899 ranged from 11.7% in the 1790s to 24.7% in the 1840s, with a mean proportion of 18.4% across this century. The proportion of infant deaths rose gradually in the earlier half of the 19th century, peaking in the 1840s, but then decreased over the second half of the century (Table 8). The reason for this pattern is unclear. However, infant mortality is widely used in modern medical anthropology and health provision as a fairly sensitive measure of the general health of a population. It is possible that rural poverty and ill health reached its lowest point in Wargrave in the

Decade	Infant burials	Total burials	%
1790-99	29	249	11.7
1800-09	30	188	16.0
1810-19	38	225	16.9
1820-29	46	265	17.3
1830-39	55	293	18.8
1840-49	63	255	24.7
1850-59	46	248	18.5
1860-69	62	273	22.7
1870-79	53	254	20.9
1880-89	42	261	16.1
1890-99	45	259	17.4
Total	509	2770	18.4

Table 8: Proportion of infant burials to total burials in Wargrave by decade (1790- 1899); n= 509, N= 2,770

1840s, but gradually improved latterly. Interestingly, this improved health coincides with the coming of the railways and the growth of Wantage as a recreational retreat for Londoners, and may reflect greater general affluence in the parish.

From 1813, it was possible to explore the age distribution of males and female burials in St Mary's churchyard (Table 9 and Figure 22). A sample of 600 entries broadly distributed across the 19th century was taken. Infant deaths comprised 18.9% of all deaths, of which males slightly predominated. After this age, there was very little difference in the number of males and females in each age category. Non-adults (aged <18 years) comprised just over a third (33.5%) of all deaths, of which infants (<two years) were by far the largest group. The lowest percentage of deaths (3.6%) was in young adults (aged 18-25 years) at 3.6%, followed by young children (aged 2-5 years) at 3.8% of the sample. The low proportion of young adult female deaths is initially surprising, given the dangers of childbearing, but may reflect slightly later marriage in country people (often in their mid-late twenties).

Years	Infant (<2y)		Young child (2-5y)		Older child (6-12y)		Adolescent (13-17y)		Young adult (18-25y)		Prime adult (26-35y)		Mature adult (36-45y)		Older adult (>45y)	
	M	F	M	F	M	F	M	F	M	F	M	F	M	F	M	F
1813-17	15	5	0	0	2	5	2	1	3	3	7	4	4	4	31	37
1833-37	11	17	4	4	8	4	1	5	0	2	4	7	4	6	30	28
1853-57	7	8	3	2	3	5	5	3	4	1	3	4	4	2	27	25
1873-77	12	10	1	5	4	3	2	0	2	5	6	6	7	2	27	28
1893-97	16	12	3	1	4	3	3	2	2	0	1	0	8	2	30	29
Total	61	52	11	12	21	20	13	11	11	11	21	21	27	16	145	147
%	10.2	8.7	1.8	2	3.5	3.3	2.2	1.8	1.8	1.8	3.5	3.5	4.5	2.7	24.2	24.5

Table 9: Age and sex distribution of burials in St Mary's churchyard in the 19th century by decade by numbers and by proportion of the total sample, (N= 600).

Both sexes show a proportional rise in mortality in their late twenties to forties. By far the largest age cohort in this sample comprised older males and females, who made up 24.2% and 24.5% of the sample, respectively. Given the manifold hardships of rural life outlined above, many parishioners lived into their 80s and even 90s. This included many inmates of the workhouse. One parishioner Sabrina Draper (buried 8 March 1859) is recorded as being 108 years old.

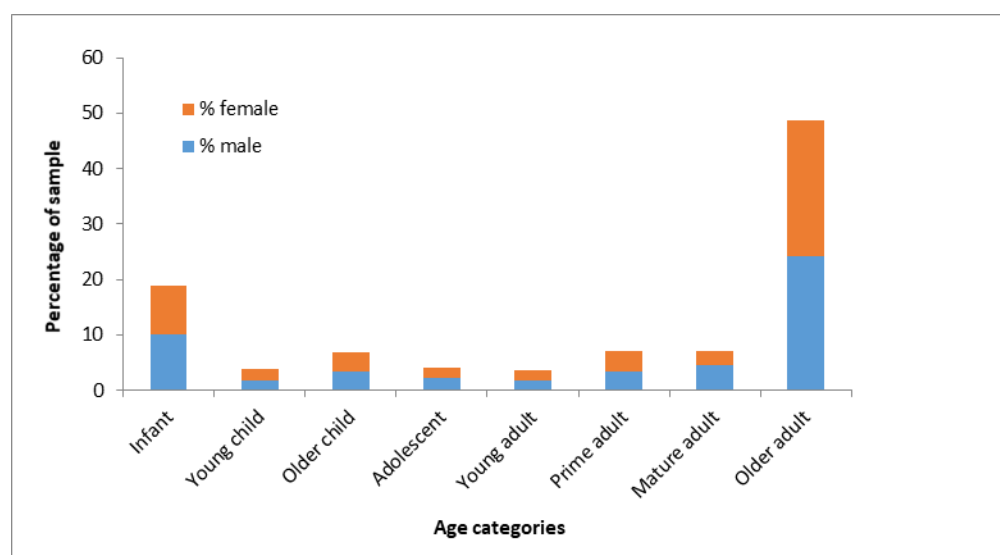


Figure 22: Age and sex distribution of a representative sample of entries in the St Mary's Church burial register 1813-1897 expressed as percentage of the whole sample; N= 600.

Cause of death

The cause of death is seldom given in the burial registers, with the exception of drowning of which there are several records, at least three involving children. On 5 July 1851, one Thomas Gerome of Shiplake (aged 24 years) was buried in St Mary's churchyard. A note in the margin of the burial register states '*suicide by drowning, buried this person under authority of Coroner's warrant. I was by no means satisfied that the coroner's warrant 'temporary insanity' is correct*'. The censorious tone of this note indicates the widespread Victorian disapproval and stigma attached to suicide, which in many cases resulted in exclusion from burial within consecrated ground. The incumbent here clearly was reluctant to bury Thomas Gerome. Suicides, like unbaptised babies and strangers to the parish, were often buried beyond the church walls or in the northern part of the churchyard- the so-

called 'devil's quarter' (May 1996). Thus, the skeletal assemblage described in this report, which were excavated from the northern churchyard, may well include such unfortunates.

Complications of pregnancy and childbirth undoubtedly caused the deaths of many women of childbearing age and their infants. This is strongly suggested in the case of Sarah Brown (buried 17 December 1850) in the same coffin as her infant Caroline Jane, who had survived only 10 days. Another tragic yet remarkable case was the joint burial within a single coffin of three brothers Henry, Robert and Walter Wiltshire (all aged three months) on 4 September 1896. The triplets were born to farm labourer George and his wife Elizabeth on 11 May 1896. Remarkably, given the rudimentary obstetrics of the day, all three triplets and Elizabeth survived the birth- no mean feat considering that even in modern Western obstetrics, neonatal mortality is 27% higher in triplet births (including Caesarean section). Presumably they were in good health immediately after birth, as Elizabeth and George waited a full month before they were baptised on 21 June 1896. Sadly, although living for three months, all three infants simultaneously succumbed, presumably to a childhood infection. Elizabeth lived on to deliver two more sons (who did reach adulthood), and was buried in the churchyard on 2 May 1934, aged 69 years.

Acute childhood infections were probably responsible for the deaths of many infants and children in the parish, particularly when they were already weakened by under- or malnutrition. Childhood mortality was particularly high was 1865, when 14 children under 12 years died (mostly aged 4-8 years), with several families losing two or more children. For example, in April and May, the Shaws of Kiln Green lost three children, aged four, six and eight years. The district school was also particularly hard hit, suggesting an outbreak of infection there too.

Other circumstances of death recorded in the burial registers were falling into a sawpit; one woman was found in extreme illness on the Reading Road and died in the Union workhouse in 1849, and one Sarah Benham (aged 44 years) died in Moulsoford asylum in 1885. One of Wargrave's most flamboyant and illustrious parishioners, Richard Barry, 7th Earl of Barrymore, accidentally shot and killed himself whilst escorting French prisoners-of-war from Rye to Dover, and was buried within St Mary's Church in February 1793 (Berkshire Family History Society 2012).

Osteological analysis

Bone preservation and completeness

Bone preservation and completeness have significant impact on the identification of pathological lesions, as well in the determination of demographic parameters, such as age, sex and stature. Post-depositional factors affecting bone preservation are multiple, complex and interacting. Most significant is the surrounding soil acidity, but also the pH of the immediate micro-environment around the corpse, and subsequent skeleton (Henderson 1987; Janaway 1996; Nawrocki 1995). In coffined burials, tannic acids released during coffin wood decomposition and the inclusion of other materials, such as wood shavings or sawdust in the base of the coffin, may adversely affect bone preservation (Garland 1989). Other major taphonomic factors are temperature, the quantity and ease of passage of water and oxygen through the burial soil and bioturbation (e.g. root damage, animal and human burrowing and digging) (Turner-Walker 2008).

Cortical bone surface condition of the Wargrave skeletons was recorded using McKinley's six-point scale ranging from pristine (0) to near-destroyed (5) (McKinley 2004). Although bone preservation varied considerably between individuals within the assemblage, the

graveyard soil of St Mary's Church was generally favourable to preservation. Although no skeletons could be described as pristine, 57 (63.3%) of skeletons had suffered only minimal to patchy surface damage (Grade 1), and 25% as slight to moderate damage (Grade 2). Only six (6.7%) showed more extensive damage, whilst maintaining the general morphology of the bone (Grade 3) and two (2.2%) showed more advanced damage (Grade 4). However, none were described as severely damaged or near destroyed.

The bones of the torso of two post-medieval skeletons showed near destruction whilst the preservation of the rest of the skeleton was fair to good. This differential preservation is probably due to the destructive effects of the metal breastplates of their coffins, which overlay this body part.

Due to the considerable intercutting of graves, many skeletal elements had been disturbed and fragmented during grave digging. These disturbed elements were often collected as charnel in the backfill of later graves. Truncation by later graves was a major factor in the incompleteness of so many skeletons. So too was the small area of many test pits, in which only parts of many skeletons were exposed. As those elements falling beyond the limit of excavation were left *in situ*, this resulted in very partial skeletons being osteologically analysed.

Skeletal completeness was rated as 0-25% (1); 26-50% (2); 51-75% (3); 76-95% (4), and near complete (5) (Mays et al. 2004), determined by the approximate proportion of body parts in the skeleton present (approximately 15% for the skull, 25% the torso, and 15% for each limb). In the Wargave assemblage, 36 skeletons (40%) were less than 25% complete, 23 (25.6%) were 25-50% complete, 18 (20%) were between 50-75% complete, and 11 (12.2%) were 75-95% complete. Only two skeletons (2.2%) were nearly complete.

Osteological methods

Age estimation

Osteological age and sex estimation was undertaken in accordance with accepted standards (Brickley and McKinley 2004; Buikstra and Ubelaker 1994). Both genetic and environmental factors affect the rate and nature of ageing, resulting in considerable intra- and inter-populational variation. Thus, all age-at-death estimates presented in this study are expressed as a range, and multiple ageing methods were utilised wherever possible. However, ageing methods are not without their limitations.

(a) Non-adult ageing methods

Non-adult ageing methods allow narrower age ranges than in adults, as the growth and maturation sequence is fairly predictable and uniform (Scheuer and Black 2000).

The following ageing methods were used in non-adults:

- deciduous and permanent dental development (Moorrees et al. 1963; Smith 1991)
- diaphyseal long bone length in children (Hoppa 1992; Maresh 1955)
- diaphyseal long bone length in foetus (Scheuer and Black 1990)
- epiphyseal fusion (Schaefer et al. 2009).

Dental development is less influenced by adverse environmental factors (such as disease and malnutrition) than skeletal development (Mays 1998), and hence is regarded as the most reliable ageing method for non-adults (Hillson 1996).

Similarly, diaphyseal long bone length in age-at-death determination was limited to pre-teen skeletons (the upper age limit of the method being 12 years).

Adolescent age-at-death determination was based principally on the timing of epiphyseal fusion. Late fusing epiphyses, such as the medial clavicle, sacral segments and superior iliac crest were also used to age adults up to the age of 27 years. Delayed cessation of longitudinal growth results in delayed epiphyseal fusion in chronically deprived individuals. In such individuals, under-ageing may be significant.

(b) Adult ageing methods

Adults were aged from stages in the degeneration of flowing joints in adult males and females

- iliac auricular surface (Buckberry and Chamberlain 2002; Lovejoy et al. 1985)
- pubic symphysis (Brooks and Suchey 1990)
- sternal rib ends (Iskan et al. 1984).

The auricular surface was the principle site employed for adult ageing in this study, as it survived much better than the pubic symphysis. In the current analysis, sternal rib end analysis was employed where possible, but identification of the fourth rib was problematic, due to rib fragmentation in most skeletons, markedly limiting the use of this method.

Ectocranial suture closure stages were recorded (Meindl and Lovejoy 1985), but this method was not used to determine age, as the accuracy and precision of this method is not high (Cox 2000). It was used only to broadly indicate a younger or older adult.

Other features taken as general indicators of older age include cross-sectional cranial thickening, arachnoid granulations, generalized degenerative joint changes and ossified cartilage.

Dental wear was not used as an age-at-death determinant, due to much slower rates of tooth wear in the medieval and post-medieval period compared to that of earlier agrarian societies on which ageing methods (Brothwell 1981; Miles 1963) were developed – probably the result of a less gritty diet with the advent of commercial milling and a more refined diet. Attrition models developed for post-medieval populations (e.g. Roden 1997) have not proved to be accurate or reliable when tested on named assemblages (Boston et al. 2009).

Age categories employed in this study are presented in Table 10 (below).

<i>Foetus</i>	<i>1- 36 weeks gestation</i>
<i>Neonate/ newborn</i>	<i>36 weeks gestation- 1 month</i>
<i>Infant</i>	<i>1 month- 2 years</i>
<i>Young child</i>	<i>2-5 years</i>
<i>Older child</i>	<i>6-12 years</i>
<i>Adolescent</i>	<i>13-17 years</i>
<i>Young adult</i>	<i>18-25 years</i>
<i>Prime adult</i>	<i>26-35 years</i>
<i>Mature adult</i>	<i>36-45 years</i>
<i>Older adult</i>	<i>45+ years</i>

<i>Non-adult</i>	< 18 years
<i>Adult</i>	>18 years

Table 10: Age categories used in this study

(i) Sex determination

Sexually dimorphic traits emerge after the onset of puberty and, hence, can only be ascribed with any degree of accuracy in skeletons aged greater than 16- 18 years. Standard sexually dimorphic skull and pelvic features were used in this study (Buikstra and Ubelaker 1994; Ferembach et al. 1980).

The pelvis is the most sexually dimorphic element, exhibiting features that directly relate to functional evolutionary differences between the sexes, most significantly childbirth (Mays 1998). Blind studies of known sex individuals reveal that sexing from the pelvis has an accuracy as high as 96 % (Meindl et al. 1985; Sutherland and Suchey 1991). The skull is the next most sexually dimorphic element, from which sex may be correctly inferred in up to 92% of cases (Mays 1998). Sex estimation from the cranium alone has an accuracy of 88%, whilst there is a 90% accuracy when the mandible is also present (Krogman and Iscan 1986). This observed sexual dimorphism arises as the result of the action of testicular hormones on the male skull, which is characterised by a general increase in robusticity and enlargement of muscle attachment sites. Blind studies undertaken on the named Christ Church, Spitalfields, assemblage revealed an accuracy as high as 98% in skeletons where both complete skulls and pelvises were present (Molleson et al. 1993).

As male skeletons are generally larger than females in a population, metrical analysis of specific landmarks, such as the femoral, humeral and radial heads, may be used to indicate sex. As there is considerable interpopulational variation in build, this method is not as accurate as sexing from the skull and pelvis. Due to considerable skeletal incompleteness, a high proportion of the Wargrave assemblage lacked either elements, and was sexed using metrics alone.

Osteologically, sex may be ascribed with differing levels of certainty, depending on the extent of sexual dimorphism present, and the number of sexually dimorphic sites available for study. Sex categories used in this study reflect this uncertainty: male or female where there was considerable certainty of the sex; probable male or female, where some ambivalence or uncertainty existed but where the sex of the individual could be ascribed with some confidence; and possible male or female, where there was only weak indication of sex. These are listed in the skeletal catalogue, but sex distribution was calculated by conflating these categories into 'male', 'female' and 'unknown'.

(ii) Stature estimation

Adult stature was calculated by applying maximum length measurements of complete long bones to regression formulae developed for white males and females (Trotter 1970).

In this study, all intact long bones were measured, as well as those that had suffered no more than one post-mortem break that could be readily reconstructed. Lower limb long bones are preferred over those of the upper limbs, as these directly contribute to stature and have been shown to be more accurate (Brickley and McKinley 2004), particularly the femur (Waldron 1998). Although stature was estimated from all complete major long bones, mean stature based on femoral measurements alone is presented separately to stature estimated from other long bones.

Pathology

Skeletal evidence of disease and injury was recorded with reference to general palaeopathological texts (e.g. Aufderheide and Rodriguez-Martin 1998; Ortner 2003; Roberts and Manchester 2005; Waldron 2009), and to other palaeopathological, modern medical and forensic literature specific to a particular condition. A written description of the appearance, location and distribution of each lesion, and the most probable diagnosis was made in a Microsoft Word document for each skeleton.

True prevalence rates (TPR) were calculated as a percentage of the number of affected parts of an element present (e.g. proximal, distal or shaft) of the sum of that part of the element present in the total assemblage (e.g. number of fractured femoral shafts times by 100, divided by total number of femoral shafts present). In this way, the incomplete elements could be included in the study without erroneously skewing disease prevalence. This approach was necessary as many elements were incomplete.

Crude prevalence rate (CPR) was calculated as the percentage of a particular lesion or condition *per capita* or per skeleton. This was utilised in conditions that affected multiple elements (e.g. scurvy and syphilis).

Results

Assemblage composition

Skeletal preservation and completeness

Overall, skeletal preservation was good, with one skeleton (sk 53) being in a pristine condition, whilst 62.9% of the assemblage was scored as very good, and 27% as showing slight to moderate taphonomic surface damage. More extensive damage was noted in 8.9% of the skeletons, but none were rated as very severely damaged (Table 11). This overall good preservation allowed the recognition of even subtle pathological changes, and greatly facilitated ageing, sexing and stature estimation.

Only those parts of the skeleton that fell within each trench were excavated- the rest being left *in situ*. As a result, a very large proportion of skeletons were incomplete. Only two were near complete, and another 11 (12.4%) were more than 75% complete. Almost two-thirds (66.1%) comprised only half of the skeleton or less, with 35 individuals (39.3%) represented by only a few bones (Table 11).

Preservation			Completeness		
Score	n	Percentage	Score	n	%
0	1	1.1			
1	56	62.9	0-25%	35	39.3
2	24	27.0	26-50%	23	25.8
3	6	6.7	51-75%	18	20.2
4	2	2.2	75-95%	11	12.4
5	0	0.0	near complete	2	2.2

Table 11: Preservation and completeness of the St Mary's Wargrave assemblage (N= 89)

Sex determination

No attempt to assign sex to non-adults was made, in accordance with accepted practice (O'Connell 2004). In some older adolescent and young adult skeletons, full sexual maturity had not yet been attained, and sexually dimorphic landmarks showed mixed traits or were only weakly diagnostic of sex. Uncertainty in assigning sex was largely due to skeletal incompleteness and fragmentation and/or the immaturity of six individuals. Inability to sex some adults was largely due to the absence or poor preservation of the skull and pelvis, and in a very few fully adult skeletons, a mixture of male and female traits, which rendered sex indeterminate.

Using only skull and/or pelvic traits, 26 skeletons of the total assemblage (N= 89), were sexed as definitely male (29.2%), seven as probably male (7.9%) and three (3.4%) as possibly male. Sixteen skeletons were definitely female (18%) and two possibly female (2.3%). Six were non-adults where sex could not be assigned (6.7%), one adolescent showed female pelvic traits (1.1%), and 30 adults (33.7%) lacked the skull and pelvis to assign sex. Thus, double the number of males to females was recorded.

This male predominance was conspicuous in uncoffined, plain and decorated coffined interments, appearing temporally to extend throughout the duration of use of the churchyard (Table 12). It was most pronounced in the early post-medieval period, with most plain coffins contained adult male skeletons. However, the sample was very small (N= 10). Most of the non-adults were uncoffined (four of six), suggesting either a Saxon or medieval date or low social status.

Dating	Male	Female	Adult unknown	Non-adult unknown	Total
Without coffin	15 (16.9%)	10 (11.2%)	20 (22.5%)	4 (4.5%)	49 (55.1%)
Coffin without fittings	8 (9.0%)	1 (1.1%)	0 (0%)	1 (1.1%)	10 (11.2%)
Coffin with fittings	13 (14.6%)	7 (7.9%)	9 (10.1%)	0 (0%)	29 (32.5%)
Unknown	0 (0%)	0 (0%)	0 (0%)	1 (1.1%)	1 (1.1%)
Total	36	18	29	6	89

Table 12: Distribution of sex and coffin type (sexing based on skull and pelvic traits alone); N= 89. Percentages given are the percentage of the total assemblage in each category (N= 89).

In addition, 17 adult skeletons that lacked the skull and pelvis for sex determination were sexed from the dimensions of articular surfaces of several long bones. Sex was ambiguous in four of these individuals. Six were assigned male sex, with varying degrees of confidence, whilst seven were sexed as female. Thus, when metrical analysis was used in sexing, there was a more even distribution of the sexes. This was in contrast to the marked predominance of male skeletons based on cranial and pelvic traits alone.

Age estimation

Osteological age estimation aims to establish the biological age of the skeleton. This age does not always concur with the chronological age (Cox 2000), because factors, such as

nutrition, lifestyle and genetic diversity, have an impact on the trajectory of skeletal growth and subsequent degeneration, and hence, on skeletal age estimation.

In the St Mary's assemblage, seven non-adults (7.9%) and 82 adults (92.1%) were identified (Table 13; Fig. 23). Five disarticulated long bones of a 24-week old foetus (sk 14) were recovered during the washing of mature adult female skeleton 8. If skeleton 8 was indeed the mother, she was a fairly old one (aged 40-50 years). She and the foetus that she was carrying died early in the pregnancy, possibly from obstetric complications (such as antenatal bleeding or infection) or from completely unrelated maternal disease or trauma, which were not evident on her skeleton. Although skeleton 8 showed evidence of stress in childhood (marked dental enamel hypoplasia) and well healed scurvy, the only bony lesion active at the time of her death was a halo of grey new bone surrounding the alveolar socket of upper right canine, indicating the spread of infection from a periapical abscess in that tooth to the surrounding maxilla (upper jaw) and soft tissue of the mouth. The abscess was one of several in adjacent teeth. Whilst her poor dental health may have caused her no more than toothache, the spread of bacteria from such abscesses into the general circulation has been widely implicated in endocarditis and heart valve failure in modern medicine. Although speculative, it is possible that the physical toll of pregnancy on a weakened heart and challenged immune system was implicated in her demise. We shall never know for certain.

Surprisingly, no newborns or infants were recovered during the excavation. The youngest children were aged 5-7 years (sk 17 and sk 68), followed by sk 45 (aged 6-8 years) and sk 32 (aged approximately 10 years) and sk 40 (aged 9-11 years). One adolescent (sk 28) was present, aged 14-16 years. Although not sexually mature, the pelvic morphology suggested a female. It is possible that several young females with fused long bone epiphyses were also in their teens, but were categorised as being skeletally mature, and were assigned to the young adult category. Conversely, the only adolescent skeleton (sk 28) may have suffered delayed epiphyseal fusion (delayed growth cessation) as a consequence of environmental stress in their growing years, and was categorised as adolescent when she was in fact in her twenties.

Age	Male	%	Female	%	Adult unknown	%	Non-adult	%	n	%
Foetus	0	0	0	0	0	0	1		1	1.1
0-24 m	0	0	0	0	0	0	0	0	0	0.0
2-5 years	0	0	0	0	0	0	0	0	0	0.0
6-12 years	0	0	0	0	0	0	5	5.6	5	5.6
13-18	0	0	0	0.0	0	0	1	1.1	1	1.1
18-25	1	1.1	2	2.2	1	1.1	0	0.0	4	4.5
26-35	6	6.7	4	4.5	0	0.0	0	0.0	10	11.2
36-45	8	9.0	3	3.4	0	0.0	0	0.0	11	12.4
45+	14	15.7	7	7.9	0	0.0	0	0.0	21	23.6
>18	7	7.9	1	1.1	28	31.5	0	0.0	36	40.4
Total	36	40.4	17	19.1	29	32.6	7	7.9	89	100.0

Table 13: Age and sex distribution in the Wargrave skeletal assemblage, as a number and a percentage of the total assemblage (N= 89)

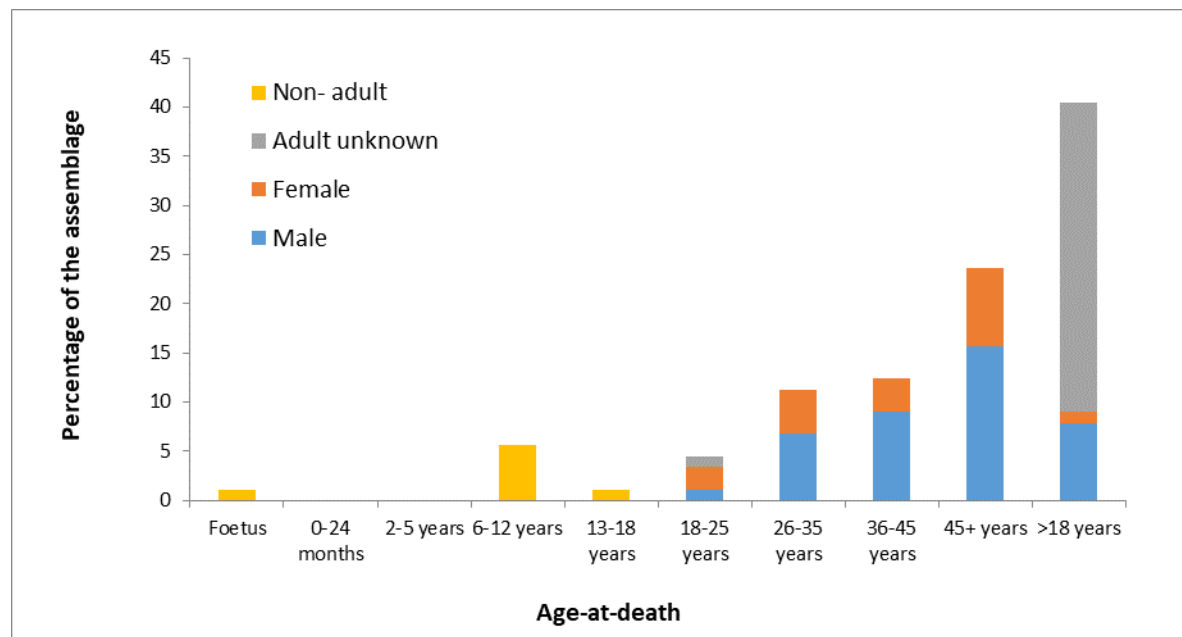


Figure 23: Age and sex distribution of the Wargrave assemblage (N= 89)

Only one male, two females and an unsexed adult were aged 18-25 years at death, but numbers did slightly increase in subsequent age categories. In many pre-modern populations, there is a small peak in young adults as a consequence of risk-taking in young adult males (the so-called 'testosterone surge') and the deleterious effects of childbearing in females. The slight increase in the 25-35 year category in Wargrave females may be the consequence of slightly later marriage and subsequent childbearing in rural communities in the post-medieval period. Mortality increased with increasing age, with the highest proportion of male and female deaths over 45 years (23.6%). However, almost a third of the assemblage (>18 years) could not be sexed or aged more precisely than > 18 years (adult). However, many individuals that could not be formally assigned an age range did display marked joint degeneration, suggestive of older age.

Stature estimation

Stature is regarded as one of the most reliable and comparable parameters by which to measure both the general health of individuals in their growing years, and the health and socio-economic well-being of populations (Floud et al. 1990; Larsen 1997; Tanner 1981; Tanner 1992). Attained stature is determined by the complex interplay of inherited and environmental factors (Silventoinen 2003). Although there is a strong genetic influence on an individual's growth and development (including final stature) (Preece 1996), environmental factors, such as physical and emotional stressors during childhood and adolescence, may prevent fulfilment of this potential (Jurmain et al. 2009; Lewis 2007; Silventoinen 2003; Tanner 1992). Environmental stressors affecting individuals for extended periods, such as malnutrition and chronic illness (particularly infections), will slow or stop normal growth. Following the stress episode, the individual may experience a period of accelerated growth ('catch-up growth'), which may compensate for this temporarily lost growth (Boersma and Wit 1997). However, if the stress episode is very severe or prolonged, or if adequate nutrition is not available for catch-up growth, the individual will be permanently stunted (Floud et al. 1990; Lewis 2007).

An adaptive response to maximise final stature in chronically disadvantaged individuals is the extension of the growth period into the third and even fourth decade of life (Humphrey 2000; Mays 1998). Termination of longitudinal growth occurs with epiphyseal fusion of the

major long bones, and osteologically distinguishes adults from non-adults. Delayed fusion results in the osteological under-ageing of young adults, an over-representation of adolescents, and an under-representation of young adults. This effect is unlikely to have been significant in the Wargrave assemblage where only one adolescent female was present (sk 28).

As stature estimation calculated from femoral length is regarded as most accurate, these data are presented separately from stature estimates that include calculations based on the length of other long bones of the upper and lower limbs. Due the small number of sexed skeletons in which stature could be estimated, it was not meaningful to divide the Wargrave sample into time periods, and the data below combines stature of both medieval and post-medieval skeletons. Adult stature was estimated from maximum femoral length in 17 male and seven female skeletons. Male stature ranged between 159.9 cm and 180.4 cm (5'3''-5'11''), with an average of 169.5 cm (5'6¾''). Female stature based solely on femoral length, ranged between 157.8 and 165.3 cm (5'2'-5'0''), with a mean of 160.4 cm (5'3''). When stature was estimated using all complete long bone lengths, the range was 159.2-190.5 cm (5'3''- 6'3'') in 28 males, with a mean of 169.5 cm (5'6¾''). In the 12 females with complete major long bones, stature ranged between 153.4- 168.4 cm (5'0''- 5'6''), with a mean of 159.9 cm (5'3'').

The average stature of males and females of the Wargrave assemblage is markedly lower than that of modern Britons (175.3 cm or 5'9'', and 161.6 cm or 5'3'', respectively). In their synopsis of health in Britain over time, Roberts and Cox (2003) estimated a mean male stature of 171 cm in both the later medieval and post-medieval periods. Mean female stature rose slightly from 159 cm to 160 cm over this time. However, these averages are very broad-brush and do not take into account the wide range of socioeconomic and environmental milieus in which people in the past lived and which undoubtedly influenced final stature.

The mean stature of 169 cm in male skeletons of the Wargrave assemblage is slightly lower than the figures calculated by Roberts and Cox (2003) above. There are relatively few meaningful published stature estimates of local medieval farming communities, but the Wargrave figure does compare closely with medieval small town and monastic lay cemeteries in the region. For example, male stature averaged 1.7 m in the St Martin's Church, Wallingford, skeletal assemblage (10-14th century AD) (Anderson and Boston 2018) and in the Abingdon Vineyard assemblage (11-16th centuries) (Wakely 2006), and was the same (167.01 cm) in the Littlemore Priory skeletons (1134-1540 AD) (Clough 2017). These figures were slightly lower than several urban and monastic assemblages of this period (Anderson and Boston 2018), but slightly higher than mean male stature of 168 cm estimated in the rural community of Wharram Percy, Yorks. (Mays 2007) .

The average stature of adult females of the Wargrave assemblage (160.4 cm) was considerably higher than that from medieval skeletons of the Littlemore Priory, Oxford (156.1 cm) and St Martin's churchyard, Wallingford (158 cm), but comparable with the Abingdon Vineyard medieval females (160 cm). It was higher than 10 other urban and religious medieval assemblages (Anderson and Boston 2018). This difference may be real, suggesting higher status of females in Wargrave, but given the small sample size, it may well not be an accurate representation of female stature in the parish. In addition, stature estimation in other reports is often based on multiple long bone measurements. That said, stature estimated from multiple long bones was still higher in the Wargrave females than in many other medieval assemblages.

At 169.5 cm, the mean stature of the Wargrave males compared closely with several working class assemblages of the post-medieval period, but was lower than several middle

class assemblages of that time (Table 14). Given the widespread poverty in rural England in the late post-medieval period (outlined above), the simple coffin furniture in most burials, and the social undesirability of interment in the northern churchyard, it would appear that the bulk of the Wargrave skeletons were working class. Certainly, male stature compares more closely with the working class norm in this period. Interestingly, male stature in Wargrave was lower than in contemporaneous assemblages from Faringdon parish churchyard, the very poor parish of St Peter-le-Bailey in central Oxford and the small 17th century possibly non-Conformist burial ground on West St Helen Street, Abingdon in nearby Oxfordshire (Table 14).

By contrast, mean female stature in Wargrave was slightly higher than stature in the above three largely post-medieval assemblages from Oxfordshire, and several other predominantly working class assemblages of the period. It compared more closely with contemporaneous middle class stature estimates (Table 14). Thus, mean female stature in both the medieval and post-medieval periods in Wargrave was slightly higher than expected. This may be an artefact of the small sample size of seven, or may indicate slightly higher status of women in the parish.

<i>Sites</i>	<i>Mean male stature (cm)</i>	<i>Male stature range (cm)</i>	<i>Mean female stature (cm)</i>	<i>Mean female range (cm)</i>	<i>Social background</i>	<i>Authors</i>
<i>St Mary's Church, Wargrave (all long bones)</i>	169.5	159.2–190.5	159.9	153.4-168.4	<i>Largely working class</i>	<i>This study</i>
<i>St Mary's Church, Wargrave (femur only)</i>	169.5	159.9-180.4	160.4	157.8-165.3	<i>Largely working class</i>	<i>This study</i>
<i>All Saints' Church, Faringdon</i>	170.7	159-189.3	159.2	147-168.7	<i>Largely working class</i>	<i>(Harvey 2014)</i>
<i>St Peter-le-Bailey Church, Oxford</i>	172	161-186	158	143-171	<i>working class</i>	<i>(Webb 2007)</i>
<i>West St Helen Street, Abingdon</i>	170	-	159	-	<i>unknown</i>	<i>(Brady et al. 2007)</i>
<i>Cross Bones cemetery, Southwark, London</i>	169	153- 180	158	142-172	<i>working class</i>	<i>(Brickley et al. 1999)</i>
<i>Baptist burial ground, Kings Lynn</i>	169	153- 181	160	152-166	<i>working class</i>	<i>(Boston 2009)</i>
<i>Baptist burial ground, Poole</i>	169	157- 186	158	140-174	<i>working class</i>	<i>(McKinley 2008)</i>
<i>Quaker burial ground, Kingston-upon-Thames</i>	169	154- 190	160	140-175	<i>middle class</i>	<i>(Bashford and Sibun 2007)</i>
<i>Quaker burial ground, Kings Lynn</i>	170	160- 179	161	159-164	<i>middle class</i>	<i>(Mahoney-Swales 2009)</i>
<i>Christ Church crypt, Spitalfields, London (femur only)</i>	170	155- 188	156	154-159	<i>middle class</i>	<i>(Molleson et al. 1993)</i>
<i>St Luke's Church Islington, London</i>	170	155-193	158	149-172	<i>middle and working class</i>	<i>(Boyle et al. 2005)</i>

<i>Newcastle Infirmary burial ground, Newcastle-upon-Tyne</i>	171	160-183	160	150-176	working class	(Boulter et al. 1998)
<i>St Martin's Church, Birmingham</i>	172	156-185	159.1	139-171	mostly working class	(Brickley et al. 2006)
<i>St George's Church, Bloomsbury, London</i>	172	152-185	160	149-172	middle class	(Boston et al. 2009)
<i>St Nicholas' Church, Sevenoaks</i>	173	162-183	161	149-172	middle class	(Boyle and Keevil 1998)

Table 14: Comparative adult male and female stature estimates from later post-medieval skeletal assemblages in England.

Non-metric traits and anatomic variants

A wide range of small anatomical differences are present between individuals within a population and may occur in different frequencies between populations. These minor variants or non-metric traits do not confer an obvious biological advantage on an individual. Some traits appear to be genetically inherited (e.g. metopism- non-fusion of the frontal bone of the skull along the midline), whilst others develop in response to environmental factors or activity, or are the result of the interactions of genes and environment. A selection of non-metric traits was recorded in only 51 adults of the Wargrave assemblage, as exigencies on site precluded full analysis of some of the skeletons.

The true prevalence (TPR) of each trait (the percentage of elements displaying a trait of the total number of landmarks present) is presented in Table 15. Discussion of each lies beyond the scope of this report, but suffice to say that as a group, there was fairly low rate of cranial vault ossicles, most sutures being very simple, no Inca bones and only two cases of metopism (sk 53 and sk 85). The largest ossicles by far were present in sk 91: bilateral lambdoid ossicles (Table 15). Most styloid processes of the temporal bone had been lost post-mortem, but in the six left and six right that survived, only one (sk 8) displayed a left styloid elongated beyond 30mm (the minimum length for diagnosis of Eagle's Syndrome (Raina et al. 2009)).

In the buccal cavity or mouth, tori or thickening or ridging of the hard palate and inner surface of both jaws were present in the minority of cases. There was one left maxillary torus (7.1%) but no right; no mandibular tori, but six palatal tori along the midline of the hard palate (37.5%). This bony thickening is thought to occur more often in individuals chewing on tough and fibrous foodstuffs.

	Left			Right			Axial		
Cranial traits	n	N	TPR (%)	n	N	TPR (%)	n	N	TPR (%)
Lambdoid ossicle							5	21	23.8
Ossicle at lambda							4	22	18.2
Inca bone							0	22	0.0
Sagittal ossicle							2	13	15.4
Ossicle at bregma							0	18	0.0
Metopism							2	19	10.5

Epiteric bone	3	10	30	2	11	18.2			
Ossicle at asterion	2	17	11.8	5	14	35.7			
Parietal notch bone	1	17	5.9	0	14	0			
Frontotemporal articulation	0	11	0	0	9	0			
Palatal torus							6	16	37.5
Maxillary torus	1	14	7.1	0	15	0			
Mandibular torus	0	21	0	0	20	0			
Eagle's syndrome	0	6	0	1	6	16.7			
Postcranial traits	Left			Right			Axial		
	n	N	TPR (%)	n	N	TPR (%)	n	N	TPR (%)
Humerus septum	0	14	0	0	14	0			
Humerus supracondylar notch	0	13	0	0	13	0			
Sternum foramen							0	12	0
C1 cleft neural arch							2		
Cervical rib							2		
Scapula supraspinous notch	0	13	0	0	13	0			
Scapula os acromiale	3	11	27.3	2	13	15.4			
Scapula acromial articular surface	2	9	22.2	1	10	10.0			
Ilium accessory facet	2	21	9.5	4	17	23.5			
Sacrum accessory facet	1	16	6.3	2	16	12.5			
Sacrum spina bifida occulta							2	22	9.1
Sacrum lumbarisation							0	36	0.0
Sacrum sacralisation							3	36	8.3
Additional sacral segment							2	147	1.4
Femur Allen's fossa	1	18	5.6	1	17	5.9			
Femur plaque	7	18	38.9	5	16	31.3			
Femur exostosis	8	18	44.4	3	12	25.0			
Femur third trochanter	9	17	52.9	9	17	52.9			
Femur hypotrochanteric fossa	1	18	5.6	3	18	16.7			
Patella vastus notch	1	10	10.0	1	11	9.1			
Tibia squatting facet medial	2	14	14.3	1	15	6.7			

Tibia squatting facet lateral	2	14	14.3	3	15	20.0			
Calcaneus double facet	8	12	66.7	6	10	60.0			
Calcaneus single facet	0	12	0.0	0	10	0.0			
Calcaneus peroneal tuberosity	2	6	33.3	4	6	66.7			
Foot phalanges symphalangia							2	96	2.1

Table 15: True prevalence of non-metric traits and anatomical variants in the part of the Wargrave assemblage (N= 51)

In the postcranial skeleton, several midline defects were present. Defects involving the incomplete fusion of neural arches posteriorly were seen in the first cervical or neck vertebra (the axis) along the midline in two adults (sk 38 and sk 60). Non-fusion of the neural arches of the first three sacral segments, known as *spina bifida occulta*, was noted in two Wargrave adults (sk 3 and sk 79). Unlike the more serious condition of *spina bifida cystica* (which involves the lumbar spine), *spina bifida occulta* rarely affects the neuromuscular system of the individual, and is usually asymptomatic. These are neural tube defects, which develop in the first month of embryonic development, and have been associated with low maternal folic acid intake in early pregnancy (Resnick and Niwayama 1995).

Other anomalies of the spinal column included **sacralisation** (where the lowest lumbar vertebra L5 fuses with the sacrum, creating a longer sacrum of six rather than five segments). This affected three skeletons (sk 26, sk 56 and sk 62). The sacra of sk 25 and sk 60 comprised six segments, but as there were the normal five lumbar vertebrae and the normal 12 thoracic vertebrae present, this was an **additional element**, and hence, cannot be described as true sacralisation. Interestingly, these two skeletons also displayed **sacroccygeal fusion**. One other skeleton (sk 62) with a fused sacrum and coccyx also showed sacralisation. There is no evidence of fracture in the coccygeal region in any of the three skeletons, and hence, this fusion is assumed to be congenital. There were no cases of lumbarisation (the reverse process where the first sacral segment forms a separate sixth lumbar vertebra), nor of spondylolysis of the lumbar vertebrae.

The seventh cervical or lowest neck vertebra of sk 4 and sk 59 displayed additional facets on the lateral processes, which indicated abnormal articulation with an extra bone- probably with a small extra rib or **cervical rib**. Cervical ribs may develop from the elongation of the lateral process of the seventh vertebra, but are separate element (Aufderheide and Rodriguez-Martin 1998). Cervical ribs are usually asymptomatic, but may affect the nerve and blood supply to the arms (*Ibid.*). The ribs themselves were not recovered.

Non-fusion of the tip or epiphysis of the acromial process of the scapula or shoulder blade beyond the age of normal fusion (approximately 21 years (Schaefer et al. 2009)) is known as *os acromiale*. This was present in the left and right acromial processes of male skeletons 25 and 67, but only in the left in male skeleton 64. *Os acromiale* is regarded by some as an inherited trait, whilst others believe that the failure of the epiphysis to unite is the result of repetitive overuse of the shoulder, particularly when engaged in overhead arm motions involving abduction and external rotation of the arm (Pecina and Bojanic 1993). The unfused acromial epiphysis may accommodate a greater range of elevation of the shoulder when the arm is externally rotated to an extreme extent (Knusel 2007). Overuse from a young age as a result of longbow archery was famously suggested in the *Mary Rose* assemblage (1511) (TPR 12.2%) (Stirland 1987), in medieval soldiers from the Battle of

Towton (1461) (TPR 8.6%) (Knusel 2007), and in late 18th century Royal Navy sailors (9%) (Boston 2017). It is unclear why the three Wargrave males were affected, but like the above groups, *os acromiale* may have been induced by repetitive shoulder use, possibly associated with the river trade.

One middle and distal foot phalange of skeleton 26 and of skeleton 62 were fused at the interphalangeal joint. In the absence of any evidence for trauma, it is probable that this fusion was inherited: the common variant known as **sympalangism**, which usually involves the fifth toe. Considerably different rates of sympalangism rates have been found across the globe, ranging from 84% in modern Japanese to 46.4% in early 20th century white Americans and 44% in Afro-Americans (Case and Heilman 2005). The low rate of this trait in archaeological skeletal assemblages is undoubtedly due to poor recovery of these tiny bones during rapid excavation, and hence, there is undoubtedly considerable under-representation of this condition in the archaeological record.

Pathology

Dental pathology

The teeth, alveolar sockets (tooth sockets) and jaws were examined for common dental pathologies, such as caries, periapical abscesses, periodontal disease, calculus, antemortem tooth loss (AMTL) and dental enamel hypoplasia (DEH). Extramasticatory wear and developmental anomalies, such as third molar agenesis and supernumerary teeth, were noted but are not discussed below. The presence of caries and calculus between the teeth (on the mesial and distal surfaces) was not always visible due to the accretion of dried mud, and hence, may be under-represented below.

Due to skeletal incompleteness, the permanent teeth and/or jaws were preserved in only 36 Wargrave skeletons (40.4%). As mandibles and maxillae were often incomplete or damaged and many teeth were missing post-mortem, all but periodontal disease rates are expressed per tooth or per alveolar socket (TPRs). The last was expressed *per capita* (CPR).

Of the above categories of dental pathology listed above, all but DEH are commonly the consequence of poor oral hygiene practices and carbohydrate consumption, particularly of simple sugars (such as sucrose). Food residues left on the teeth following consumption of carbohydrates rapidly become colonised by bacteria, and are broken down to form a corrosive acidic plaque. It is this plaque that is responsible for the development of carious lesions (holes) in the teeth (Hillson 1996). Plaque may also mineralise, forming a hard unmoveable coating of calculus on the tooth surface, colloquially known as tartar. Periodontal disease is the inflammation of the soft tissues of the mouth, namely the gums, and/or the periodontal ligament and alveolar bone of the jaws (Levin 2003). Retraction of diseased gums exposes the vulnerable root of the tooth to attack by acidic plaque, commonly resulting in caries, periapical abscesses (abscesses in the tooth socket) and AMTL.

Dental decay is closely associated with carbohydrate consumption. Commoners in the medieval period would have had extremely restricted access to sweeteners, relying largely on honey when available. In the post-medieval period, cane sugar was introduced into the British diet. In the 16th and 17th centuries, sugar was an expensive and high status luxury (Musgrave and Musgrave 2000), but the development of large sugar plantations in the West Indies in the 18th century generated a more ready and affordable supply to European markets. As sugar became cheaper, so consumption spread down the social classes, such

that by the mid-later 19th century it was available to all but the most indigent (*Ibid.*). Indeed, by the mid-Victorian period, refined sugar comprised a significant component of the diet of the working poor, in the form of sugared tea, jam and cheap confectionary (Mintz 1985). Annual *per capita* consumption of sugar in Britain rose from 4 lbs in 1704, to 18 lbs in 1800, and 90 lb in 1901 (*Ibid.*). Increased sugar consumption resulted in widespread dental disease, which spread down the social classes as the cost of sugar fell. Indeed, in Wargrave in 1909, medical inspectors of the District School for needy or abandoned children, noted that more than half the children needed treatment for teeth and poor eyesight, and commented that besides causing pain, bad teeth in the children prevented chewing of food, and as a result, the children became feeble and malnourished (Gray and Griffiths 1986).

The practice of oral hygiene was largely absent or, at best, rudimentary in medieval and post-medieval periods. Although by the 18th century, toothbrushes, tooth powder and even toothpaste contained within metal tubes were available (Hillam 1990), they were expensive, and it is unclear how widely they were actually used. Thus, it is improbable that good oral hygiene was practiced by many Wargrave inhabitants, laying them open to dental decay.

Dental caries

Dental caries involves the destruction of the enamel surface, the dentine (internal part of the tooth) and the cementum (outer layer of the roots). This is caused by the acid produced by bacteria present in dental plaque (Hillson 1996; Lukasc 1989).

In the Wargrave assemblage, the mean number of caries per skeleton with permanent dentition (N= 36) was 2.6, or a TPR per tooth of 30.9%. This rate is considerably higher than the mean of 11.2%, calculated in other 18-19th century British assemblages (Roberts and Cox 2003), and in the assemblages presented in Table 16. As caries are attritional, the high rates were undoubtedly influenced by the advanced age of many Wargrave inhabitants (based on parish burial records 1813-1899). Another important factor is accessibility to refined sugar in the mid- and later 19th century. The high rate of dental caries in Wargrave probably reflects this changing pattern of consumption. It outstrips all but the King's Lynn Quakers (an older middle class assemblage) in Table 16. This relatively higher rate may also be associated with the later end date of the burials at Wargrave compared with many of the assemblages below, and includes the late Victorian period when sugar consumption was a significant component of the diet of all strata of society.

Ante mortem tooth loss (AMTL)

The loss of permanent dentition before death (AMTL) is the end result of several disease processes. Calculus deposits irritate the soft tissue and the underlying bone, which may lead to periodontal disease and the loss of a tooth (Roberts and Manchester 1995) (Plate 4-B). Teeth also may be lost through periapical abscesses, caries, and excessive attrition. Dental decay was probably the most common reason for tooth loss, but others include the deliberate tooth extraction and trauma. As with caries, the AMTL rate in the Wargrave assemblage (43.6% of sockets) was the highest of the assemblages presented in Table 16, with the exception of the Kings Lynn Quakers (53.8%).

<i>Assemblages</i>	<i>Dates</i>	<i>Antemortem tooth loss</i>	<i>Periapical abscesses</i>	<i>Calculus</i>	<i>Caries</i>	<i>Dental enamel hypoplasia</i>	<i>Comments</i>
<i>St Mary's Church, Wargrave</i>	<i>11thC-1900</i>	<i>43.6% (365/837)</i>	<i>5.5% (43/778)</i>	<i>80.4% (222/276)</i>	<i>30.9% (94/304)</i>	<i>36.7% (91/248)</i>	<i>Largely working class</i>

<i>All Saints' Church, Faringdon</i>	1050-19thC	18.3%	<1%	14.3%	6.1%	2.7%	Largely working class
<i>St Peter-le-Bailley Church, Oxford</i>	10 th C-1855	30.3% (496/1636)	0.4% (7/1636)	-	7.8% (60/773)	6.1% (47/773)	Largely working class
<i>Newcastle Infirmary, Newcastle-upon-Tyne</i>	1753-1845	19.3% (604/3123)	0.9% (29/3123)	55.9% (718/1287)	11% (146/1327)	17% (219/1287)	working class, including many merchant seamen
<i>Baptist, Kings Lynn</i>	1773-1855	33.2% (135/407)	1.5% (6/407)	85.4% (18/212)	18.7% (39/212)	60.7% (119/196)	working class
<i>Crossbones, Southwark, London</i>	1800-1853	17.3% (211/1216)	2.3% (211/1216)	-	26% (161/621)	29% (adults)	very poor working class
<i>St Luke's Church, Islington, London</i>	1733-1853	35.4% (1726/4883)	1.8% (87/4883)	46.3% (1042/2249)	9.7% (219/2249)	10.3% (231/2249)	middle class
<i>St George's Church, Bloomsbury, London</i>	1804-1856	41% (669/1632)	2.8% (46/1632)	70.9% (592/844)	13.4% (110/844)	16.4% (138/844)	middle class
<i>Quakers, Kings Lynn</i>	1784-1835	53.8% (169/314)	0.3% (1/34)	74.2% (98/132)	74.2% (98/132)	36% (41/114)	middle class
<i>Christ Church, Spitalfields, London</i>	1729-1867	19.9% (324/1627)	-	-	19.1% (311/1627)	-	middle class

Table 16: The true prevalence of dental disease in the permanent dentition of the St Mary's Church, Wargrave, assemblage and other skeletal assemblages; in brackets are the number teeth or sockets affected/ number present.

Dental calculus

Calculus consists of mineralised plaque composed of microorganisms that accumulate in the mouth and become imbedded in a matrix of protein and saliva. Sugar in the diet accelerates this process (Hillson 1996), as does a diet high in protein. There are two types of calculus: calculus situated above the gum line (supragingival) and calculus (subgingival) found below the gum line on exposed roots. The latter occurs when the gums retract exposing the root, and hence, may be used as an indication of the presence of periodontal disease. More heavy calculus deposits are commonly seen on teeth nearest to the salivary glands (Roberts and Manchester 1995), such as on the buccal aspect of the molars, and the lingual aspects of the lower incisors (Hillson 1996). Regular tooth brushing removes plaque deposits, thereby inhibiting calculus formation. However, there are considerable differences in the propensity to lay down calculus between individuals.

Calculus deposits were recorded by tooth and an overall grade of slight, moderate to considerable was given per individual (Table 16). Calculus was present on 80.4% of teeth in the Wargrave assemblage. However, overwhelmingly the deposits were slight to moderate. Again, this probably reflects the older age distribution of the Wargrave assemblage.

Periodontal disease

Periodontal disease includes any ailment of the supporting structures of the teeth, including the gums (gingival), periodontal ligament and alveolar bone (Levin 2003). The principal predisposing factor in periodontal disease is the accumulation of calculus in dental pockets.

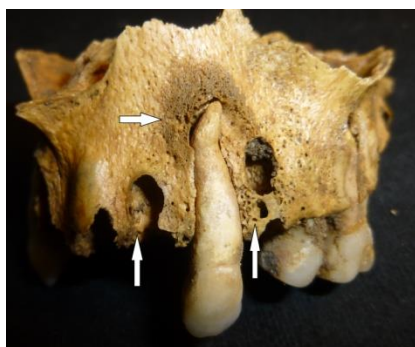

Plate 4-A: Active woven bone surrounding the right canine root apex (horizontal arrow) and periapical abscesses (vertical arrows) in the left maxilla of skeleton 8.

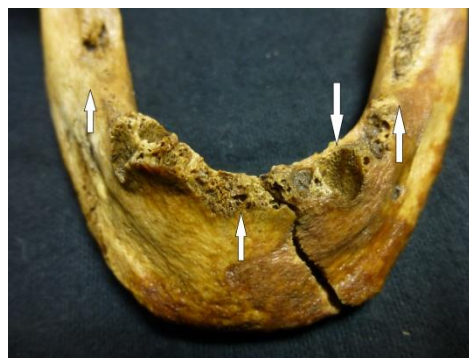

Plate 4-B: Mandible of skeleton 60 showing recent anterior AMTL and more advanced AMTL of molars (upwards arrows) and a periapical abscess (downwards arrow).



Plate 4-C: Considerable calculus deposits on multiple teeth of skeleton 89. The red colour of the far left tooth is due to rust from an adjacent coffin nail.

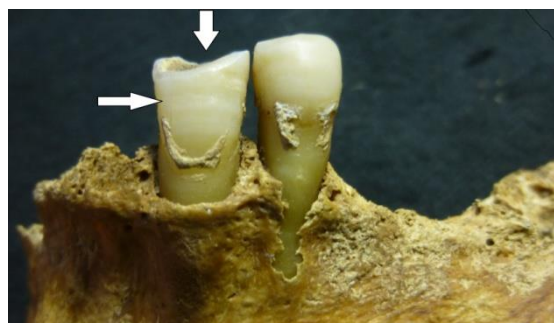


Plate 4-D: Pipe notch on the right lower canine of skeleton 54 (vertical arrow). The tooth also shows two lines of DEH (horizontal arrow). There is AMTL of the second premolar and first molar.

Plate 4: Selected dental pathological lesions in the Wargrave assemblage

The disease begins as gingivitis (an inflammation of the soft tissues), which is transmitted to the jaw itself. Resorption of the bone commences, followed by tooth loss. There are two different ways in which this disease expresses itself: as horizontal or vertical bone loss. In the former, more than one tooth are involved, often the whole of the dental arcade. All walls surrounding the teeth are lost uniformly. In the latter, the lesion is localised around one tooth or possibly two. The bone loss around the tooth is irregular and generally without horizontal bone loss (Hillson 1996). There is a strong link between the increase of age and prevalence of periodontal disease in modern and past populations. However, aetiology is multifactorial with genetic predisposition, environment, diet and dental hygiene being all predisposing factors in its development (*Ibid.*).

The location of periodontal disease was recorded by quadrant (left and right upper and lower). Severity was rated as mild, moderate or considerable (using Ogden 2008's scoring system). Periodontal disease was present in 22 Wargrave skeletons (N= 36): a TPR of 61.1%. Of these, nine were rated as slight, one as moderate and 12 as considerable.

Peri-apical abscesses

Abscesses in the sockets (peri-apical abscesses) are caused by bacteria entering the pulp cavity of a tooth through dental caries, excessive wear or trauma to the crown, as well following dental surgery. An abscess may also develop when a periodontal pocket forms by

the accumulation of bacteria within pulp cavity, and the infection tracks down to the root apex. As pus accumulates within the dental socket and surrounding alveolar bone, local pressure builds, and eventually precipitates the formation of a hole or sinus in the jaw, through which the pus drains into the overlying soft tissue of the gums (Roberts and Manchester 1995). In this advanced stage, the abscess is visible as a small hole on the surface of the maxilla or mandible (jaws).

Periapical abscesses were present in 5.5% of tooth sockets in the Wargrave assemblage. This is the highest of all assemblages presented in Table 16.

Dental enamel hypoplasia

Dental enamel hypoplasia (DEH) manifests on the buccal surface of the crowns of teeth as pits, horizontal lines or lines of pits. These defects are caused by thinning of the enamel, and reflect an interruption or slowing of the normal deposition of enamel during crown formation in the first six or seven years of life (Goodman and Rose 1990; Hillson 1996). DEH is thought to result from prolonged episodes of illness or malnutrition lasting at least three weeks (*Ibid.*), but food adulterations, used widely in the 18th and 19th century, may also have played a role in the interruption of normal tooth development (Roberts and Cox 2003). Such defects are most apparent when normal dental development recommences following such an environmental insult. Unlike bone, enamel does not remodel throughout life and so remains as a permanent indicator of such a stress episode in the early years of life.

In this study, the teeth with visible buccal surfaces were examined for DEH, and its general severity in each skeleton recorded (slight, moderate and marked). DEH was identified in 19 Wargrave skeletons (52.8%), but in 13 of these cases, DEH was rated as slight (Table 16). Five showed moderately marked defects, but in only one (sk 40) was the enamel severely affected. Patterning of the defects on early erupting teeth indicated that this individual had suffered marked and/or prolonged illness in infancy. Poor health and failure to thrive appeared have dogged in this child, such that at death, aged 9-11 years, she/he had only attained the growth of a seven year old. However, no skeletal pathology was present to indicate dietary deficiency or other chronic disease.

There is considerable variation in the rates of DEH recorded in contemporaneous skeletal assemblages (Table 16), probably due to inter-observer differences in recognising more subtle defects. This complicates meaningful comparison between the DEH rate of 36.7% of observable crowns in the Wargrave assemblage and other contemporaneous assemblages, in which rates ranged widely from 2.7% to 60.7%.

Pipe notches

The dentition of three Wargrave adults (older adult male sk 52, older female sk 59 and prime adult female sk 81) showed notching of the tooth crowns, most probably caused by abrasion from habitual clay pipe smoking (Plate 4-D). These U- or V-shaped notches are commonly found in the canines and premolars, where the shaft of a clay pipe was gripped between the teeth. They are not uncommon in post-medieval skeletal assemblages, and are usually found in males. The Wargrave assemblage is unusual, but not unique in having two female pipe smokers. Clay pipes were used from the mid-17th to early 20th centuries. Although no coffin evidence was recovered from the three burials, the presence of pipe notches does suggest a post-medieval date for these burials. However, it remains possible that this tooth wear developed as a result of other repetitive but unknown activities in which the mouth was used as a 'third hand'.

Deciduous or milk teeth

Three non-adults (sk 17, sk 45 and sk 68, aged 5-7 years, 6-8 years and 5-7 years) retained deciduous or milk teeth (N= 19 teeth). Calculus was present on all the deciduous crowns of sk 45, but was absent on the teeth of the other two children. No periapical abscesses were noted in the associated alveolar sockets. However, 10 of the 19 teeth showed caries, in most cases, very severe. Such dental decay is rarely marked in archaeological populations in the absence of DEH until the Victorian period. Like the Wargrave District School children described above, these three children had 'bad teeth' early in life and probably suffered toothache as a result. There were no cases of DEH in the deciduous crowns, suggesting that none of the three children had suffered severe or prolonged stress whilst in the womb- the time when the crowns of the deciduous teeth develop (Hillson 1996).

Skeletal pathology

Trauma

Trauma or injury may occur to any tissue of the body, but in osteology, only injury involving bone, joints and sometimes muscle, tendon and ligaments may be identified. The overwhelming evidence for trauma in osteological remains is fractures. Joint injuries usually take the form of chronic dislocations and labral tearing (damage to the cartilaginous ring just within the margin of the shoulder and hip joints). Tearing of muscle fibres, tendons and ligaments where they insert into bone (known as enthesopathies or enthesal changes) may manifest osteologically as bony ridges or enthesophytes (when the damaged tissue ossifies) or as indentations in the bone surface, where strenuous tendon or ligament pulling causes a small localised area of bone to be sheered or pulled away from the surface. The latter is sometimes known as a cortical defect.

Enthesal changes were not systematically recorded in this project. The general impression, however, was that most males and females showed defined muscle insertion sites in elements of the shoulders and arms, and to a lesser extent, the legs. This would suggest that most were engaged in repetitive, strenuous physical activity- probably manual labour. This finding is consistent with the coffin fitting evidence, which indicates that the overwhelming majority of the assemblage, at least in the post-medieval period, was of lower socio-economic status.

Fractures

There was clear macroscopic evidence of 73 healed and two healing fractures in the Wargrave assemblage (0.85 fractures *per capita*). Radiography was not undertaken. Twenty-three individuals (all adult) displayed one or more fracture. The fracture count per person ranged from one to 19. The highest was found in older adult male sk 38. The next highest fracture count per person was seven- found in older adult male sk 7 and sk 73. Fractures are summarised by skeleton in Table 17 and true prevalence by element is presented in Table 18.

Fractures were overwhelmingly found in males (n= 18). Only three females (sk 18, sk 59 and sk 83) displayed fractures, as did two adults of unknown sex (sk 2 and sk 44).

As fractures are attritional (accumulate over a lifetime), it is not surprising that 14 of the 23 skeletons that displayed fractures were older adults (>45 years), whilst two were mature adults (36-45 years) and one a prime adult (26-35 years). Six individuals were adults of unknown age.

In keeping with most skeletal assemblages, the **ribs** were the most frequently fractured element in the Wargrave skeletons. Seven skeletons displayed a total of 28 healed and united fractures. Most affected was older male sk 38, who had sustained 13 rib fractures, both left and right. The fracture location on the ribs varies, with some being anterior, others posterior and several at different points along the shaft, including the angle of the rib. However, several consecutive ribs showed both anterior and posterior fractures occurring at the same point on the shaft (in a vertical line). This suggests that they may have occurred simultaneously in a single traumatic event (e.g. crushing by a cart or large livestock), and may have resulted in a flail segment of the chest wall. This is potentially extremely dangerous as the rib cage may collapse inwards during breathing out (expiration), often resulting in respiratory failure. However, the well healed calluses uniting the rib fractures in sk 38 indicate that he survived his injuries for years, possibly decades. Well healed new bone overlay the normal bone surface on the visceral or inner surfaces of several left and right ribs of this skeleton, indicating an inflammatory process in the adjacent pleura or lungs. This rib periostitis may well have been associated with the above chest trauma, developing in response to a haemothorax or pleural effusion (a collection of blood or other fluid in the pleural space around the lungs), lung contusion (bruising) and/or a secondary chest infection. Rib fractures in modern subjects are commonly the result of falls and of interpersonal violence (especially when located anteriorly) (Brickley 2006), and may well be the cause of many of the Wargrave fractures in other skeletons.

Other fractures commonly associated with **interpersonal violence** were present on the crania of male sk 7, sk 50 and sk 85. The last skeleton showed several well healed facial fractures: markedly displaced comminuted fractures of the left and right **nasal bones**, which caused depression of the bridge of the nose and deviation to the left of the midline; an united but depressed left **zygomatic arch** (cheek bone) fracture, and an enigmatic discrete, sharp-edged lesion on the superior maxilla, just below the left eye, which appears to be **sharp force trauma**, probably caused a thin blade, such as a knife, or shard of glass. The location of these injuries on the left side of the face is consistent with attack by a right-handed assailant facing the subject. A second lesion also caused by sharp force trauma was present on the left side of the frontal bone of the same skeleton. This lesion comprised a linear depression in the bone (21 mm in length), in which a spall of bone had been incompletely separated or sliced from the bone surface. Smooth edges of the lesion indicated that the injury occurred long before death. Due to the advanced state of healing, it is impossible to determine whether these injuries occurred in a single or in multiple assaults. The skeleton comprised only the skull and upper neck vertebrae, so it was not possible to explore evidence of trauma on the rest of the skeleton.

Skeleton	Sex	Age	Total fractures	Comments ¹
1	M	OA	1	R hand PP2 or 3 #
2	?	A	2	R talus Shepherd's #; R calcaneal #
3	M	OA	3	L posterior rib # x 1; T7 & 8 bodies crush #s
7	M	OA	7	L & R nasal x 2, L & R tali x 2 Shepherd's #s, rib, R MC3; R MC5 (healing) #s
9	M	OA	5	TV x 4 & LV x 1 wedge #s
10	M	OA	1	R MC3 #
18	F	OA	1	R clavicle healing #
26	M	MA	2	2 x unsided anterior rib #s

33	M	A	2	R patella & R talus #s
34	M	OA	3	L5 crush #; R acetabular crush #; L humerus greenstick #
37	M	OA	2	Rib x 2 #s
38	M	OA	19	Ribs x 13, acetabular, CV & TV #s
44	?	A	1	L talus Shepherd's #
50	M	OA	1	L parietal sharp force trauma
54	M	MA	2	L anterior iliac crest Sprinter's avulsion #; R MC3 #
59	F	OA	1	L Shepherd's #
62	M	PA	3	R Rib1, R MC3, R capitate #s
67	M	A	1	R humerus transcolumnar #
73	M	OA	7	Rib #s x 6, L MC3 incomplete styloid #
82	M	OA	1	R femur intertrochanteric #
83	F	OA	2	TV x 2 wedge #s
85	M	?	5	L & R nasal, R zygoma & R maxilla #s, frontal bone sharp force trauma
87	M	?	3	L rib x 3 #s

Table 17: Fractures present in the Wargrave assemblage (23 individuals, 75 fractures), M= male, F= female, ?= unknown sex; A= adult; MA= mature adult, OA= older adult; PA= prime adult; #= fracture

<i>Fractures</i>	<i>L temporal</i>	<i>L parietal</i>	<i>L maxilla</i>	<i>L nasal</i>	<i>Vomer</i>	<i>L Sphenoid</i>	<i>L zygoma</i>
<i>n</i>	0	1	0	2	0	0	0
<i>N</i>	29	34	26	10	5	22	18
<i>TPR</i>	0	2.9	0	20	0	0	0
<i>R parietal</i>	<i>R temporal</i>	<i>R Sphenoid</i>	<i>R maxilla</i>	<i>R nasal</i>	<i>R zygoma</i>	<i>Mandible</i>	<i>Frontal</i>
0	0	0	1	2	1	0	1
36	32	27	27	10	22	34	30
0	0	0	0	0	0	0	3.3
<i>Occipital</i>	<i>Sternum</i>	<i>L scapula</i>	<i>R scapula</i>	<i>L clavicle</i>	<i>R clavicle</i>	<i>L ribs</i>	<i>R ribs</i>
0	0	0	0	0	1	17	11
34	22	41	33	31	35	400	354
0	0	0	0	0	2.9	4.3	3.1
<i>CV</i>	<i>TV1-6</i>	<i>TV7-12</i>	<i>LV</i>	<i>Sacrum</i>	<i>Coccyx</i>	<i>L ilium</i>	<i>L ischium</i>
2	3	7	2	0	0	0	0
225	230	220	185	147	8	38	36
0.9	1.3	3.2	1.1	0	0	0	0
<i>L pubis</i>	<i>L acetabulum</i>	<i>R ilium</i>	<i>R ischium</i>	<i>R pubis</i>	<i>R acetabulum</i>	<i>L humerus P</i>	<i>L humerus S</i>
0	1	1	0	0	2	0	1
13	36	37	36	27	37	28	33

0	2.6	2.7	0	0	5.4	0	3
<i>L humerus D</i>	<i>R Humerus P</i>	<i>R humerus S</i>	<i>R humerus D</i>	<i>L Radius P</i>	<i>L Radius S</i>	<i>L Radius D</i>	<i>R Radius P</i>
0	0	0	1	0	0	0	0
34	25	28	23	28	36	25	26
0	0	0	4.3	0	0	0	0
<i>R Radius S</i>	<i>R Radius D</i>	<i>L Ulna P</i>	<i>L Ulna S</i>	<i>L Ulna D</i>	<i>R Ulna P</i>	<i>R Ulna S</i>	<i>R Ulna D</i>
0	0	0	0	0	0	0	0
30	27	29	45	24	26	31	23
0	0	0	0	0	0	0	0
<i>L carpals</i>	<i>L metacarpals</i>	<i>L hand phalanges</i>	<i>R carpals</i>	<i>R metacarpals</i>	<i>R hand Phalanges</i>	<i>Unsided hand phalanges</i>	<i>L Femur P</i>
0	1	0	1	5	1	0	0
81	147	137	94	145	126	200	31
0	0.7	0	1.1	3.4	0.8	0	0
<i>L Femur S</i>	<i>L Femur D</i>	<i>R Femur P</i>	<i>R Femur S</i>	<i>R Femur D</i>	<i>L Patella</i>	<i>R Patella</i>	<i>L Tibia P</i>
0	0	1	0	0	0	1	0
32	27	31	33	26	18	16	31
0	0	3.2	0	0	0	6.3	0
<i>L Tibia S</i>	<i>L Tibia D</i>	<i>R Tibia P</i>	<i>R Tibia S</i>	<i>R Tibia D</i>	<i>L Fibula P</i>	<i>L Fibula S</i>	<i>L Fibula D</i>
0	0	0	0	0	0	0	0
32	27	31	35	30	17	31	22
0	0	0	0	0			
<i>R Fibula P</i>	<i>R Fibula S</i>	<i>R Fibula D</i>	<i>L Tarsals</i>	<i>LTalus</i>	<i>L Metatarsals</i>	<i>L foot phalanges</i>	<i>R Tarsals</i>
0	1	0	3	3	1	0	4
15	31	24	95	15	78	36	103
0	3.2	0	3.2	20	1.3	0	3.9
<i>RTalus</i>	<i>R metatarsals</i>	<i>R foot phalanges</i>	<i>Unsided foot phalanges</i>	<i>Hyoid</i>	<i>Total</i>		
3	0	0	0	0	77		
21	79	29	29	9	4331		
14.3	0	0	0	0	1.8		

Table 18: True prevalence of fractures by element or part of element in the Wargrave assemblage; n= number of fractures, N= number of that element present; L= left, R= right, p= proximal, d= distal, s= shaft N= 89)

There was also a small, well healed depressed lesion with a narrow base on the left side of the frontal bone of older male sk 50, which was probably **sharp force trauma** made by the tip of a sharp object, like a knife or spear. The lesion was completely healed.

Later post-medieval older male sk 7 displayed several pathological changes, including healed scurvy (see below), marked enthesal changes (muscle tears) to the upper arms and shoulders, healed rib periostitis, possible tertiary syphilis, and multiple fractures, including both nasal bones, one rib, left and right tali (ankle bones) and the third and fifth metacarpal bones of the right hand. All but the **fifth metacarpal (MC5)** fracture showed advanced remodelling. In contrast, the fractured shaft of MC5 was united but still healing: the callus still being large, porous and disorganised. This indicates a recent injury within months of death. In modern populations, fifth metacarpal fractures are colloquially known as 'street-fighter fractures', as they are most commonly sustained when punching an opponent. They are also common modern boxing injuries (Galloway 1999). The suite of pathological lesions in sk 7 was common in late Georgian Royal Navy sailor skeletons (Boston 2014), and it is quite possible that sk 7 was one of tens of thousands of Royal Navy veterans serving in Britain's many wars of the 18th century.

Fracture of the styloid process of the **third metacarpal (MC3)** of the hand is very rare in both modern and past populations, yet in the Wargrave, there are five examples (in male sk 7, sk 10, sk 54, sk 62 and sk 73). In the first four skeletons, fracture of the styloid process was complete and sustained on the right hand, whereas in sk 73, a deep groove (an incomplete fracture line) separating the styloid process of the left MC3 from rest of the proximal metaphysis crossed the proximal joint surface, and could just be made out on the anterior aspect of the element. All were well healed and, in the complete fractures, densification and remodelling of the exposed trabecular bone of the fracture surface was well advanced. This bony remodelling distinguished these fractures from congenitally absent styloid processes.

MC3 styloid fractures are avulsion fractures, caused when the *Extensor carpi radialis brevis* muscle of the wrist suddenly contracts, tearing off the styloid process to which it is attached. The mechanism of injury is very specific involving simultaneous contraction of the muscle with flexion of the wrist, with the elbow in full extension and the fist clenched (Tsiridis et al. 2001). Modern medical cases include a badly placed punch by an amateur boxer, a cyclist striking the side of a vehicle with the hand clenched on the handlebar, and a fall onto an outstretched hand (Boles and Durbin 1999; Breeze et al. 2009; Rofman and Pruitt 1993; Tsiridis et al. 2001). High prevalence of this injury was noted in late Georgian seamen- possibly the consequence of brawls and falls, but may well have been incurred when pulling on ropes whilst reefing sails, when heaving on the capstan when raising anchor, and possibly, when rowing jollyboats (Boston 2014). There was a marked right-sided fracture distribution in both the Royal Navy and Wargrave assemblages. Why there were so many MC3 fractures in the Wargrave assemblage is unclear, but may well be associated with strenuous rowing, punting or even steering a boat or barge on the Thames for trade or recreation.

Another uncommon fracture noted in the Wargrave assemblage was **Shepherd's fracture of the talus** or ankle bone. Often mistaken for a developmental anomaly *os trigonum*, Shepherd's fractures are fractures of the medial tubercle of the posterior process (Steidl's process) of the talus. These fractures are rarely reported in either the modern medical or osteoarchaeological literature. The eponymous fracture occurs during forceful hyperplantar flexion (pointing) or forced inversion (turning in of the foot (Judd and Kim 2002), in which the posterior process is crushed between the distal tibia (shin bone) and the calcaneus (heel bone). Colloquially known as 'nutcracker fractures', these fractures have been recognised in modern ballet dancers and footballers (Hillier et al. 2004), and have a high osteological prevalence in 18th century sailors and 19th century female cotton weavers (Boston and Sinnott 2014). In the Wargrave assemblage, five were present in four skeletons: one right (female sk 2), two left (skeleton of unknown sex sk 44 and female sk 59) and bilateral

fractures in male sk 7. The left Shepherd's fracture in sk 7 was incomplete, but the others involved complete severance of the Steidl process. All the fractures were well healed, showing advanced remodelling of the fractured surface. Although the number of Shepherd's fractures is too low to draw firm inferences, it is nevertheless interesting that two of the three adults of known sex were female. In both skeletons, the left talus was fractured, whilst the right talus was unaffected. Like the female handloom weavers from Darwen, Lancs., mentioned above, it is possible that these fractures developed as fatigue fractures from repetitious dorsiflexion of the left foot operating a treadle during spinning or weaving.

There were few **major long bone fractures** in the Wargrave assemblage. Exceptions were a greenstick fracture of the left humeral shaft of sk 34 (an incomplete childhood injury), and transcolumar fracture of the distal right humerus of sk 67, just above the elbow joint (also commonly a childhood injury), and a right femoral intertrochanteric fracture of older male sk 82. The last involved shortening of the right femur by 10 mm, and abnormal bowing of the shaft, consistent with bony buttressing, as a consequence of altered gait. It is highly probable that this individual walked with a marked limp. The extent of healing and the bony adaptations present indicate that this injury occurred many years before death. The most common cause of such injuries is direct impact, or when landing on an outstretched leg when falling from a height (Galloway 1999). No other trauma was observed on this skeleton.

The mid-shaft of the right **clavicle** or collar bone of older female sk 18 was fractured and displayed a thick callus of porous disorganised bone that had largely, but not completely, knitted the broken ends together by the time of her death. The early stage of remodelling of the callus indicated that the fracture had happened within months of her death. The large size of the callus suggests poor immobilisation of the right shoulder during healing. Clavicular fractures classically occur from a fall onto an outstretched hand (Galloway 1999)- a not uncommon accident in the elderly.

Older female sk 83 also displayed fractures common in elderly females: **wedge fractures of the thoracic vertebrae** (Roberts and Manchester 2005). The vertebral bodies of T5 and 7 had collapsed asymmetrically creating wedge-shaped bodies. This resulted in a slight kyphosis of the spine- a so-called 'dowager's hump'. The injury was associated with osteophytosis or bony outgrowths, which serve to stabilise the spine. Vertebral body fractures are not uncommon in the elderly, particularly in women, as they are often associated with osteoporosis. Three male individuals (sk 3, sk 9, and sk 34) had also suffered vertebral body fractures. In sk 3, there were crush fractures of T7 and 8, whilst in

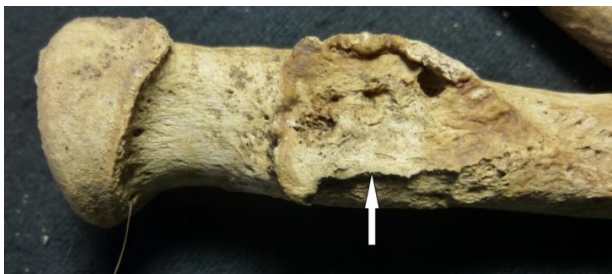

Plate 5–A: Right radius of the forearm of sk 8 showing bony ridging at the insertion site of the Biceps brachii muscle (enthesal change or muscle tear)(arrow).



Plate 5–B: Healing fracture of the right clavicle of sk 18 (arrow). Note the spongy disorganised nature of the callus (early stage of healing).

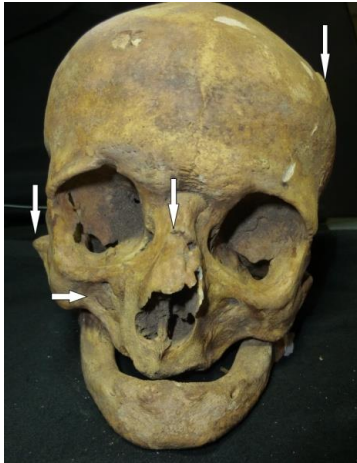

Plate 5-C: Skull of older male sk 85, showing fractured nose, cheek bone and sharp force trauma to his right maxilla and left frontal bone (arrows)- all probably due to interpersonal violence.

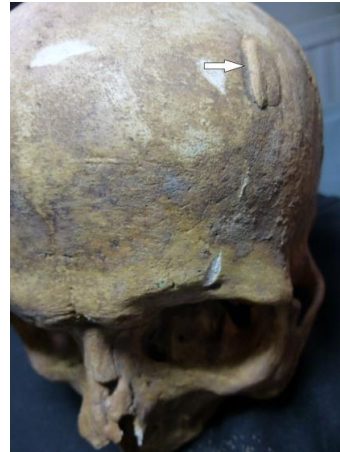

Plate 5-D: Left side of the frontal bone of sk 85 showing healed sharp force trauma (arrow).

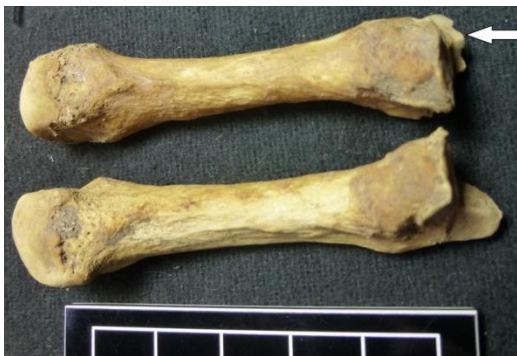

Plate 5-E: Fracture of the styloid process of the right third metacarpal of sk 7 (arrow).



Plate 5-F: Close-up of proximal joint surface of the right third metacarpal of sk 6, showing a complete fracture of the styloid process (arrow).



Plate 5-G: Shepherd's fracture of the left talus of sk 44 (arrow).

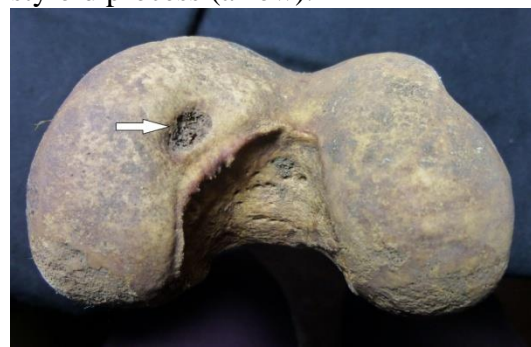

Plate 5-H: Osteochondritis dissecans (arrow) of left femoral condyle of the knee joint of sk 64.

Plate 5: Selected traumatic lesions on skeletons of the Wargrave assemblage

sk 9, anterior wedging of four consecutive thoracic bodies (T8-12) and one lumbar (L3) were present. The fifth lumbar vertebra of sk 34 showed vertical collapse of the lumbar body. This individual had also suffered impaction fractures and labral tearing in his acetabula (hip joints), with secondary osteoarthritis. It is possible that his spinal injury may

have been traumatic rather than the result of bone weakening and collapse secondary to osteoporosis.

Osteochondritis dissecans

Osteochondritis dissecans is localised damage in a joint, osteologically manifesting as a small, usually circular depression in the joint surface. This is the result of either repeated micro-trauma or a single activity involving strenuous use of the joint, which causes localised sheering of the blood vessels supplying the joint, leading to localised cartilage and bone necrosis (tissue death). *Osteochondritis dissecans* occurs most commonly in childhood and adolescence (Frederico et al. 1990; Smillie 1965; Waldron 2009). Two male skeletons displayed such lesions: in the left knee joint of young adult sk 64 (on both the medial aspects of the femoral condyle and corresponding tibial plateau), and in the right elbow of sk 67. In the latter, the well healed lesion was located on the capitulum of the humerus, and may have occurred in the same traumatic event that caused the transcolumar fracture of that element, just beyond the joint surface.

Periostitis

Periostitis is a non-specific inflammatory reaction in the periostium (the thin outermost layer of bone), which covers most bones of the skeleton (except the skull). Osteologically, this is visible as a layer of new bone deposited on the normal bone surface. When fully healed, fine periostitis may be difficult to see with the naked eye. New bone may be laid down in response to localised infection, injury, venous ulceration, or bleeding beneath the periosteum or into soft tissue immediately adjacent to the bone surface (haematoma)(Weston 2008). As this is a generic inflammatory response, unpicking the specific cause of this new bone deposition is often problematic and sometimes impossible. In some conditions, periostitis does show some characteristic patterning, in terms of its distribution across the skeleton (e.g. in chronic pulmonary disease and scurvy, below), whilst in others, characteristics of the deposited bone itself may suggest a specific condition or infection (e.g. syphilis, below).

Thirty-eight individuals, all adult, in the Wargrave assemblage displayed periostitis on the post-cranial skeleton (42.7%). Included in this group were 12 cases of rib periostitis, one definite and one possible case of syphilis, and one of tuberculosis (see below). When these more specific cases were excluded from the analysis, 28 skeletons (31.5%) displayed periostitis on one or more element. These lesions were exclusively located on the bones of the lower limb: the femur, tibia, fibula, tarsals and metatarsals. Their location on the skeleton and on individual long bones (proximal third, shaft and distal third) is presented in Table 19.

In most skeletal assemblages, the overwhelmingly most common site of periostitis on the skeleton is the tibia (shin bone), especially the anteromedial aspect, where the bone surface lies very close to the body surface, being overlaid only with skin. This lack of soft tissue protection and its location on the lower leg, makes the tibia vulnerable to trauma, infection and circulatory disorders, such as venous ulcers. Like most other archaeological assemblages, this distribution held true in the Wargrave assemblage. In addition, the proximal posterior surface of the femur was overlaid with well healed bone in at least six individuals (sk 53, sk 59, sk 62, sk 77 and sk 79). This is a much less exposed location, protected by large muscle masses. The occurrence to periostitis on this location is more probable due to scurvy (see below). Localised infection, ulceration or trauma may account for other cases in which only one element was involved, or where the tibia and fibula of one leg was affected (as anatomically they are found very close together).

Endocranial new bone

Areas of the endocranial or inner surface of the cranial vault of four Wargrave skeletons (sk 59, sk 74, sk 76 and sk 82) were overlaid by well healed plaques of new bone (CPR 4.5%). Overwhelmingly, the most common location of the lesions was overlaying the cruciate eminence of the occipital bone, followed by a linear deposit along the midline of the cranium on either side or overlaying the sagittal suture.

Like periostitis, endocranial new bone occurs as a non-specific bony response to localised inflammation, and may have many causes, including infection (such as meningitis and encephalitis), tumours or intracranial bleeding from trauma, coagulopathies (clotting disorders) or other disease processes (Lewis 2004). Sk 59 showed evidence of healed scurvy on the skull and multiple long bones, and it is possible that the endocranial new bone deposition on the occipital bone in this skeleton was a reaction to scorbutic bleeding in and around the brain (see below). Young adult possible male sk 74 also displayed healed new bone overlaying the cruciate eminence of the occipital bone. This may well have been due to a childhood injury or disease. The only other pathological lesion present was healed periostitis on a single midthoracic rib. Mature adult male sk 76 displayed no skeletal pathology. In sk 82, the endocranial new bone deposition may have been associated with the advanced frontal sinusitis infection spreading to the meninges or brain, or may be related to neurosyphilis. However, due to the advanced state of healing, it is impossible to be certain that the endocranial new bone deposition in the above four skeletons were associated or part of the above chronic conditions, or developed from a completely separate injury or disease process at another point in the individual's lifespan.

Skeleton	L femur	R femur	L tibia	R tibia	L fibula	R fibula	L Tarsals	R Tarsals	L Metatarsals	R Metatarsals	L Phalanges
7	?	?P	P,S,D	P.S.D	S,D	S.D	-	-	-	-	-
8	-	?P,?S	-	-	-	-	-	-	-	-	-
12	-	-	-	S,D	-	-	-	-	-	present	-
20	-	-	S,D	S,D	-	-	-	-	-	-	-
21	-	-	-	-	-	-	-	-	-	-	-
24	-	-	S	P	-	S	-	-	-	-	-
26	-	-	-	S,D	S	-	-	-	-	-	-
26	-	-	S,D	S,D	-	S	-	-	-	-	-
27	-	-	S,D	S,D	D	D	-	-	-	-	-
28	-	-	S,D	S,D	S,D	D	-	-	-	-	-
33	-	-	-	S	-	S	-	-	-	-	-
35	-	-	-	S	-	S	-	-	-	-	-
36	P	-	S,D	S,D	-	S	-	-	-	-	-
44	-	-	S	S	-	-	-	-	-	-	-
47	-	-	-	S	-	-	-	-	-	-	-
51	-	-	-	-	-	P,S,D	present	present	present	-	present
53	P,S	?P	-	S	-	--	-	-	-	-	-
54	-	-	S	S	S	S	-	-	-	-	-

59	P	P,S	S,D	S,D	S	S	-	-	-	-	-
60	-	-	D	P,S	-	-	-	-	-	-	-
62	P,S	P,S	S,D	-	S	-	-	-	-	-	-
64	-	-	S	-	S	-	-	-	-	-	-
72	-	-	S	S	-	-	-	-	-	-	-
77	P,S	-	S	-	S	-	-	-	-	-	-
79	-	P,S	-	S,D	-	P,S,D	-	-	-	-	-
80	-	-	P,S,D	-	P,S	-	-	-	-	-	-
82	-	-	S,D	S,D	S,D	-	-	-	-	-	-

Table 19: Periostitis in the Wargrave assemblage (excluding rib, tuberculosis and syphilis). ?= uncertain, P= proximal, S= shaft, D= distal.

Infection

Chronic sinusitis

Chronic infection of the frontal and maxillary sinuses manifests osteologically as new bone laid down on the walls and base of the sinuses, often with the appearance of lace or cobwebs (Plate 5–A). In the Wargrave assemblage, only 16 fragmented maxillae with visible sinuses were available (i.e. endoscopic examination was not undertaken). Healed new bone deposits were present in six individuals (37.5%). This is a very small and possibly unrepresentative sample, but a true prevalence of 37.5% is significantly higher than the 15% and 6.8% quoted for the medieval and post-medieval periods in Roberts and Cox (2003). Interestingly, of the six Wargrave skeletons displaying chronic maxillary sinusitis, four were female (sk 8, sk 55, sk 83 and sk 84), whilst the remainder (sk 1 and sk 91) were male.

Much more uncommon was the evidence of chronic infection in the frontal sinus of sk 82. Both the left and right sinus showed deposits of well healed new bone. This infection appeared to have been particularly severe or very prolonged in the left sinus, with thinning of the anterior wall and penetration by three smooth-walled holes or clocae. Like periapical dental abscesses, this suggests a build-up of pus, which eventually forced its way out of the sinus under pressure onto the ectocranial surface of the frontal bone.

The causes of chronic frontal and maxillary sinusitis are multifactorial, and include allergies, smoky air and upper respiratory tract infections (Roberts and Manchester 2005). The industrialising cities of England, such as London, were infamous for heavy smogs from coal fires. Presumably, Wargrave did not suffer such severe air pollution, but many earlier or poorer rural abodes lacked a chimney (Gray and Griffiths 1986), undoubtedly resulting in poor ventilation of the smoke from domestic fires, and consequently, smoke inhalation by the inhabitants. This may well have contributed to cases of chronic sinusitis seen in several skeletons, and may explain its higher frequency amongst women, who were more tied to the home with child-rearing and domestic duties (including cooking), and hence, were more exposed to the smoky atmosphere indoors.

Chronic respiratory disease

Although the overwhelming majority of respiratory diseases do not affect the skeleton, and hence, are osteologically invisible, occasionally longstanding inflammation of the soft tissue of the lungs and enclosing pleura may precipitate new bone formation on the visceral

or inner surfaces of adjacent ribs. This rib periostitis is thus indicative of chronic respiratory disease. Most commonly associated with tuberculosis, it is not specific to that disease, and may occur in other chest infections, pleurisy, emphysema and lung cancer (Roberts et al. 1998), thoracic trauma, and is usually present in adult scurvy (Boston 2014).



Plate 6-A: Healed maxillary sinusitis (arrow) in sk 8.



Plate 6-B: Three perforations of the frontal bone penetrating to the frontal sinus- marked healed frontal sinusitis in sk 82.



Plate 6-C: Abscess (arrow) surrounded by active grey woven bone on the left second rib of child sk 17- possible tuberculosis.



Plate 6-D: Sabre shins of tertiary syphilis in the tibiae of sk 2. The fibulae also show longstanding infection. The arrow identifies a typical gummatous lesion of syphilis.

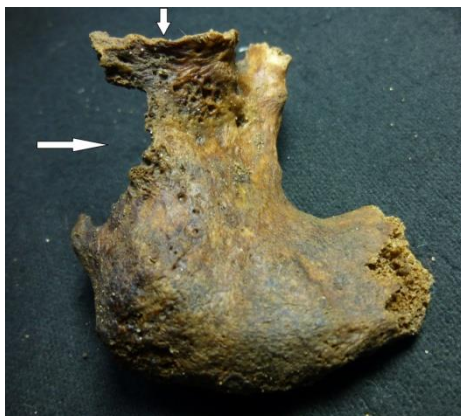

Plate 6-E: Destruction of the acetabulum and ischium of the hip (arrows)- possible tuberculosis.



Plate 6-F: Posterior aspect or back of the cranium of skeleton 82 showing multiple depressions in the ectocranial surface suggestive of caries sicca of syphilis.

Plate 6: Selected cases of infection in the Wargrave assemblage

Twelve skeletons of the Wargrave assemblage displayed rib periostitis (CPR 13.5%). The lesions were healed in all but one skeleton (sk 17). Associated pathological lesions in sk 17 suggested that this periostitis was tuberculosis (see below). Specific causes of the healed lesions in the other 11 skeletons are unclear, but three skeletons (sk 37, sk 38 and sk 73) had suffered rib fractures, and periostitis on the ribs shafts may have developed secondary to this trauma, or may be unrelated. Sk 7, sk 38, sk 73 and sk 90 displayed healed rib periostitis and pathological lesions elsewhere on the skeleton tentatively suggestive of healed scurvy. The association between rib periostitis and adult scurvy was noted in 18th century sailors (*Ibid.*). The former may develop in response to haemothorax or pleural effusions as a result of the increased tendency to bleed in scurvy, or may reflect secondary infections in these immune-compromised individuals (see below). In sk 34, sk 50, sk 88, sk 92 and sk 93, there were no other pathological changes to suggest trauma or systemic causes of this periostitis, and it is assumed that they indicate past chest infections or other chronic pulmonary conditions.

The rib periostitis rate in the Wargrave assemblage (13.5%) was higher than several other post-medieval assemblages. For example, St Luke's Church, Islington, was 3.3% (Boyle et al. 2005), the Baptists assemblage from Poole was 6.6% (McKinley 2008), the Quaker assemblage from Kings Lynn was 8.8% (Mahoney-Swales 2009), and the middle class assemblage of St George's Church, Bloomsbury was 10% (Boston et al. 2009).

Tuberculosis

In humans, tuberculosis (caused by the bacterium *Mycobacterium tuberculosis*) most commonly affects the lungs, but may spread via the lymphatic system and blood supply to other internal organs, skin, joints and bone. Pulmonary tuberculosis is an airborne disease, passing from one individual to the other through expectorated plegm. Bovine tuberculosis is another strain that is contracted through drinking infected milk, and may lead to tuberculosis of the gastrointestinal tract and adjacent tissue. The tubercular bacillus may lie latent in the body for many years, but may develop into an active infection if the host's immune status is compromised by other diseases (e.g. scurvy (Hess 1920)) or by poor nutrition (Roberts and Buikstra 2008).

Bony involvement occurs only in the minority of cases of tuberculosis- before the advent of antibiotics, as low as 5-7% (Aufderheide and Rodriguez-Martin 1998). Thus, tubercular lesions on the skeleton represent the tip of a very significant iceberg. Most commonly affected are the ribs and then thoracic spine (so-called Pott's spine), as the bacterium spreads from the lungs to adjacent tissue, but almost any tissue of the body may be infected. Rib periostitis is the most common skeletal manifestation of tuberculosis, but is not specific to this disease (see above). In joints, tuberculosis most commonly affects the hip, followed by the knee joint. Tuberculous lesions are predominantly lytic or resorptive rather than proliferative (i.e. when new bone is laid down). Weakened joints may collapse and eventually fuse (ankylose).

Tuberculosis (TB) has infected humans and other animals for tens of thousands of years. In the late medieval and post-medieval periods, increasing social stratification and rapid urbanisation resulted in high population density, poor nutrition and housing. These factors greatly facilitated the spread of tuberculosis (Roberts and Cox 2003), such that by the late 18th and early 19th centuries, the London Bills of Mortality record that 25% of all deaths in the metropolis were attributed to this disease (*Ibid.*). In rural areas, rates of TB were lower than in cities, but rural poverty and inadequate nutrition left many agricultural workers vulnerable to developing the disease, particularly amongst the young (Greaves 2018).

Periostitis of the ribs was present in twelve skeletons of the Wargrave assemblage (13.4%). Although some of these lesions may well have been tuberculous, rib periostitis is not pathognomic of the disease, as it may be attributable to other causes (see above). That said, rib lesions on sk 17 (aged 5-7 years) had other features that suggest tuberculosis. The left second and third ribs and the right first rib displayed active woven bone on the visceral surfaces of the posterior and lateral shafts. Slight smoothing of the lesions indicated that they were in the process of healing at the time of death. The second rib showed a smooth-walled oval sinus or abscess surrounded by woven bone, which penetrated the table to the trabecular bone beneath (Plate 6–C), possibly a tuberculous abscess. In addition, the inferior surface of the medial right clavicle (collar bone) showed a thick layer of active new bone deposition. This reactive new bone may be a bony response to local inflammation associated with cervical tuberculous lymphadenitis (tuberculous infection of the lymph glands) in the supraclavicular fossa at the base of the neck, which is bounded on one side by the clavicle. In TB, the cervical lymph nodes are the most commonly infected lymph nodes in the body, the bacillus being disseminated by lymph flow from the nearby lungs. This process is particularly rapid in children (Schaaf and Alimuddin 2009), such as sk 17. In cervical lymphadenitis, the lymph nodes enlarge and become tender, progressing from softening, to rupture and sinus formation, and the spread of the infection to the overlying skin. In the past, this chronic red, weeping sore was known as scrofula or the 'King's Evil' (*Ibid.*).

The right hip joint of near complete older adult female sk 36 showed severe bone destruction of the acetabulum (the cup of the hip joint) and adjoining ischium (part of the pelvis), which may be attributed to tuberculosis or other destructive processes, such as metastatic carcinoma (secondary cancer). The posterior and inferior aspects of the acetabulum (lower half of the socket) showed marked lysis (loss) of the bone such that the joint margin and part of the joint surface and ischium had been completely lost (Plate 6–E). Approximately a third of the ischium on the posterior aspect had similarly disintegrated. The edges of the lesion had a lacy, moth-eaten appearance, due to bony resorption, but also to the formation of multiple smooth-walled cysts penetrating the outer bone surface. These may be tuberculous abscesses or foramina (holes) of hypervascular tissue. The former is more probable, given that similar, more superficial lesions were also found medial to the main lesion, and may indicate the spread of infection more widely in the pelvic region. Although there is some remodelling, the bony response was overwhelmingly lytic (destructive) in nature.

The cause of this severe destruction is unclear. Strangely, the right femoral head (the ball of the hip joint) and neck appear normal. Sk 36 showed well healed rib periostitis and very fine, largely remodelled striated periostitis on the tibiae (shin bones), but otherwise no other pathological lesions that were suggestive either of tuberculosis or of metastatic carcinoma.

Venereal syphilis

The treponematoses are a group of infections caused by the bacterium *Treponema pallidum*, which include venereal syphilis, bejel, jaws and pinta. (Rothschild and Rothschild 1995). In Europe, treponemal disease was largely venereal syphilis. Today, venereal syphilis, the sexually transmitted form of treponematoses, has a global spread, is by far the most debilitating of the four and the only one to have a potentially fatal outcome.

Although the origins of syphilis are not well understood, its presence was first felt in Europe in the late 15th century, rapidly spreading, such that by the 18th century it was endemic in the population. In post-medieval Europe, venereal syphilis was a major health concern and a source of moral outrage, with prostitutes bearing the brunt of blame for its spread (Barnett 2014). It was referred to variously as the Great Pox, in England as the

French Pox, and in medical discourse as *lues venerea* (Arrizabalaga 2003). Prevention of infection using early condoms, and draconian treatment of mercury and guaicum were largely ineffectual. It was really only with the availability of penicillin in the 1930s that serious inroads were made into its control (Arrizabalaga 2003).

Syphilis is spread either by sexual contact (venereal syphilis) or from an infected mother to her foetus during pregnancy (congenital syphilis). Given the endemic nature of syphilis in post-medieval England, it is perhaps surprising that there was no dental evidence of the characteristic mulberry molars or Hutchinson's incisors of congenital syphilis (Hillson et al. 1998) in the Wargrave assemblage.

Sexually transmitted syphilis was often referred to as 'the Great Imitator', reflecting highly variable course and symptoms (Barnett 2014). Untreated syphilis is characterised by a primary, secondary and tertiary stage, separated by very varying and often prolonged latent phases. In primary syphilis, a small painless sore or chancre appears on the genitals within 2-6 weeks of infection. In most cases, after a brief latent phase the disease progresses to the secondary stage, in which widespread, very painful skin lesions erupt across the body, and fever, malaise and deep bone ache ensue. These symptoms usually disappear after a few weeks, but recur in the first two years in 25% of sufferers. A third of individuals progress to the tertiary stage, in which the disease affects profound damage to multiple body tissues, resulting in gross disfigurement, insanity and death. Skin, mucous membranes, the heart, blood vessels and nervous system are all affected. Nervous system involvement results in locomotor ataxia (the classic stumbling, high-stepping gait of a syphilitic) and bouts of insanity, known as general paresis of the insane (Arrizabalaga 2003), whilst the rupture of aneurysms and heart valve failure are often fatal. Progression from infection to tertiary syphilis is highly variable, but often takes decades.

As bone is only infected in the tertiary phase of syphilis, only this most advanced form is osteologically visible. However, bony involvement only occurs in 20% of cases (Roberts and Manchester 2005). Thus, the osteological evidence grossly under-represents the true prevalence of the disease in archaeological populations. Syphilis manifests as often thick deposits of periostitis on the surface of multiple bones, and may progress to deeper infection: osteitis and osteomyelitis. Hard rubber-like lesions or gumma are characteristic of syphilis, and are often visible as round indentations in the bone surface. The tibia is the often most affected element, with gross swelling of the shaft manifesting as a so-called sabre shin. Erosive lesions in varying stages of healing are commonly present on the cranial vault, forming stellate or purse-string-like scars when healed- so-called *caries sicca*. On the face, bony erosion usually concentrates around the nose and mouth. According to Waldron (2009), syphilis may be diagnosed by either *caries sicca* or sabre shins.

Adult sk 2 of the Wargrave assemblage was very incomplete, comprising only the lower legs and feet. The tibiae and fibulae (lower leg bones) showed gross thickening of the proximal and midshafts of both legs. This was due to longstanding or repeated episodes of infection (periostitis or osteitis), which result in sabre shins diagnostic of syphilis (Figure 26–D). Other features of these lesions were small areas of eroded tissue, and well as smooth-walled indentions in the tibial bone surfaces consistent with gummatous lesions.

There was no unequivocal *caries sicca* or facial involvement of the skulls of the other Wargrave skeletons to indicate tertiary syphilis. Older adult female sk 82 (75% complete) did display considerable unevenness of the ectocranial or outer surface of the parietal bones of the cranial vault (Plate 6–F), as a result of multiple shallow, broadly circular depressions (5-15 mm in diameter), and small areas of reduced density and also of healed new bone deposition. These may be evidence of healed sores of syphilis, but the lesions lacked the classic purse-string appearance of *caries sicca*. Unfortunately, the facial region had not

survived to be examined. The tibiae and left fibula of the legs showed widespread healed periostitis on the shafts, which was thick enough to show multiple linear invaginations of blood vessels in the surface, but there was not the gross thickening seen in sabre shins.

An alternative explanation for this very unusual bumpy appearance of most of the back and sides of the cranium is trauma: the depressions being the result of multiple blows to the head causing crushing of the outer layers of the skull. This may be evidence of childhood, domestic or even self-abuse. However, there were no other fractures usually associated with interpersonal violence on the skeleton (e.g. parry or rib fractures), but this female had suffered an intertrochanteric fracture of the right femur- often associated with falling (Galloway 1999).

Metabolic diseases

Scurvy

Scurvy has become synonymous with seamen of the post-medieval period, but also affected terrestrial populations seasonally, particularly in winter and early spring when fresh fruit and vegetables were not readily available (Carpenter 1986; Harvie 2002). Scurvy develops in humans in the protracted absence of Vitamin C or ascorbic acid over several months, which is principally obtained from a dietary intake of leafy green vegetables and fruit.

Vitamin C has multiple biochemical functions in the human body, and is integral to the normal functioning of the immune system, clotting, mood regulation and collagen synthesis. Collagen is the basic building block protein of many tissues, including muscle, ligaments, skin, gums, intervertebral discs and bone, and is essential in maintaining the integrity of blood vessel walls and lymphatic ducts (Fain 2005; Popovich et al. 2009). Because of its many functions, the absence of Vitamin C in the diet adversely affects multiple systems of the body, eventually leading to death.

The first signs develop after 1-3 months without Vitamin C, when sufferers begin to experience weight loss, pallor, lassitude, low mood or nervous excitability, and physical weakness (Barnes et al. 1953; Crandon et al. 1940). As Vitamin C levels continue to fall, defective collagen leads pathological changes in multiple tissues, not least to friable capillaries and the tendency to bleed spontaneously or in response to minimal trauma. Petechiae (pinprick bleeds beneath the skin), hyperkeratosis (dry, rough skin) and perifollicular haemorrhages (a halo of bleeding around hair follicles and sweat glands) begin to appear after one to two months without Vitamin C, followed by ecchimoses (larger areas of bleeding resembling bruises), particularly on the lower limbs. By the third to sixth month without Vitamin C, blood loss becomes more severe, with bleeding into multiple tissues, including the joints (haemarthrosis), most commonly the knee and ankle. This causes severe pain and joint stiffness, curtailing mobility and weight-bearing. Bleeding also occurs within muscles and beneath them, with large clots accumulating beneath the ham strings and calf muscles, in particular (Hess 1920; Lind 1772; Sharman 1981). Bleeding in the upper limbs in scurvy was much less common, but most often occurs around the elbow and wrist joints.

Modern autopsy and pathological examinations have revealed widespread haemorrhages in multiple tissues and organs. In the eyes, retinal and conjunctival bleeding is common, as well as bleeding between the eyeball and orbital plate (eye socket), producing orbital protuberance (bulging eyes) (Hess 1920; Hirschmann and Raugi 1999). Subperiosteal bleeding may occur in any bone, including the cranial vault, ribs and scapula. Radiography done on survivors indicates that this coagulated blood begins to turn to bone within weeks (Hess 1920). Endocranial bleeding within the brain and spinal cord and meninges has been

noted in several 20th century autopsies (*Ibid.*). Swollen, bleeding gums and tooth loss are commonly associated with this disorder.

Despite the terrible physiological consequences of scurvy, once the sufferer receives Vitamin C again, recovery is extremely rapid and dramatic. Clinical improvement is apparent within two days. Many symptoms resolve within three to four days, and signs by two weeks (Pimental 2003).

Osteologically, bleeding in scurvy elicits an inflammatory reaction on the bone surface if there is subperiosteal bleeding (beneath the outer layer or periosteum) or when clots of blood are trapped under soft tissue (particularly large muscles masses) adjacent to bone. Recent osteological reports on adult scurvy note this multi-element periostitis, particularly on the femur and tibia, as well as several cranial lesions (Brickley et al. 2016; Geber and Murphy 2012; Van der Merwe et al. 2010).

An analysis of scurvy in 18th century Royal Navy sailor skeletons noted that porosity or new bone deposition on the greater wing of the sphenoid was not common in adult scurvy, as it is in children, and that AMTL was no greater in scorbutics than non-scorbutics (Sinnott 2013). Scurvy was recognised by the presence of multiple lesions on the skeleton: periostitis on specific locations on the long bones (especially the lower limb bones) and around the elbows, wrists and ankle joints, ectocranial orange-peel-like porosity on the cranial vault, new bone deposition in the orbits, on the posterior maxilla and on the mandibular condyles, thickening and increased porosity of the hard palate, and new bone at the nutrient foramen of the tibia and at the myelohyoid foramen of the mandible. These lesions were used to identify scurvy in the Wargrave assemblage. Due to the incompleteness of many Wargrave skeletons, it was often not possible to observe the distribution of lesions across the entire skeleton. In addition, all lesions were well healed, making it impossible to be certain that they occurred simultaneously in one episode of scurvy, and had not developed in response to several unrelated diseases or injuries over the course of the individual's lifetime. This made diagnoses of scurvy uncertain. That said, particular attention to the location of the lesions on the long bones and skull made the diagnosis of scurvy more clear. In the Wargrave assemblage, 13 skeletons showed multiple lesions suggestive of scurvy (Table 20). The distribution of periostitis on the skeleton is presented separately in Table 20. Coarse orange peel-like porosity was present in several skeletons where periostitis was not identified. This occurred even in sk 73, which displayed the most convincing features of scurvy. Interestingly, older male sk 7, whose fracture patterning tentatively suggested a seafaring career, also displayed several lesions that may be scorbutic. In this group, there was considerable antemortem tooth loss (TPR 45.8%, N= 288 sockets), but this rate was only very slightly higher than in the Wargrave assemblage as a whole (43.6%). This probably reflects more the older age distribution and carbohydrate-rich diet of the assemblage than tooth loss due to scurvy.

Skeleton	Periostitis on multiple elements	Ectocranial orange peel porosity	Orbital lesions	Posterior maxilla	Great wing of sphenoid porosity	Hard palate porosity	Other lesions
7	1	1	-	-	-	?	rib periostitis
8	-	1	1	NP	-	-	-
10	-	1	1	NP	-	NP	-
38	-	1	-	-	-	-	rib periostitis
53	1	?	-	-	-	-	-

55	-	1	1	1	-	-	-
59	1	-	1	1	-	-	endocranial new bone
62	1	1	-	-	-	1	
73	-	1	1	1	-	1	
77	1	1	-	NP	NP	NP	-
79	1	NP	NP	NP	NP	NP	-
85	NP	1	-	-	-	1	infra-orbital new bone
91	-	1	-	1	-	-	-

Table 20: Pathological lesions that may be associated with healed scurvy in the Wargrave assemblage (N= 13); 1= present; ?= uncertain; NP= bone not present for observation.

Rickets

Rickets develops in childhood from a deficiency of Vitamin D, principally due to inadequate exposure to ultraviolet rays in sunlight, but has also been associated with a dietary lack of calcium, together with genetic, hormonal and other nutritional factors in vulnerable children (Brickley and Ives 2008; Holick 2002; Thacher et al. 2000). First recognised in the 17th century, by the 18th- early 20th centuries rickets was a widespread health problem in the crowded, smoggy cities of industrialising Britain, particularly amongst poor children (Steinbock 2003). Presumably because of a more outdoors existence, rickets was very much less common in rural areas. In the Wargrave assemblage, only two cases of slight residual rickets (skeletons 16 and 26) were osteologically identified from medial bowing of the tibiae and fibulae of the lower leg (using criteria set out by Brickley et al. 2010).

Orbital lesions

Iron-deficiency anaemia (Brickley and Ives 2008) and megaloblastic anaemia from folic acid or Vitamin B12 deficiency (Walker et al. 2009) in childhood may manifest osteologically as *cribra orbitalia* in the orbits, porotic hyperostosis on the cranial vault and/or *cribra femoris* of the femoral neck (Aufderheide and Rodriguez-Martin 1998). Only the first lesion was present in the Wargrave assemblage. *Cribra orbitalia* manifests osteologically as thinning of the outer table of the roof of the orbit and hypertrophy or overgrowth of the underlying spongy bone or *diploë*, such that in severe cases this protrudes through the outer table.

Four individuals (sk 8, sk 55, sk 59, sk 73 and sk 82) displayed increased porosity in the roof of the orbits, suggestive of a mild form of the disease (Stage 1-2) (CPR 4.5%; TPR 17%, N= 47 orbits) (Figure 27). However, distinguishing between mild *cribra orbitalia* of anaemia and orbital changes in other deficiency diseases, such as scurvy, is often difficult. All but skeleton 82 showed lesions elsewhere on the skeleton suggestive of healed adult scurvy, and may well be a bony reaction to bleeding behind the eyeball, which is a feature of the disease. Indeed, the lesions in sk 73 and sk 82 appeared more as hypervascular plaques of new bone overlaying the outer table of the roofs of the orbits that as thinning of the outer table exposing underlying trabeculae (spongy bone), as is found in *cribra orbitalia* of anaemia. Thus, a definitive diagnosis is highly problematic in these cases.

Possible gout

The head of the first metatarsal of the left foot of female sk 5 (aged 30-40 years) displayed lesions suggestive of gout. The juxta-articular region just medial to the joint margin showed three to four smooth-walled cysts penetrating the outer table into the trabecular bone beneath (Plate 7–D). Erosion of the margin of the joint was minimal, but there were subtle changes, such as increased porosity just beyond the joint margin on the superior and inferior aspects of the head, and a small semi-circular cyst immediately adjacent to the dorsal joint margin. The changes were unilateral, with the right metatarsal appearing normal. The location of the lesions on the first metatarsal head and the presence of smooth-walled cysts does suggest gout. However, this individual does not fit the common epidemiological profile for gout- that of older males. Differential diagnosis was attempted but no alternative diagnosis was forthcoming. The lack of joint surface erosion and the formation of cysts makes seronegative arthropathies, such as rheumatoid or psoriatic arthritis, improbable. There was no periostitis formation to suggest Reiter's syndrome. Cysts may also occur on the first metatarsal head in *Hallux valgus* (bunion or hammer toe). However, there was no lateral deviation in the articulation of the phalanges of the big toe to suggest this condition.



Plate 7–A: Porosity and new bone deposition in the roof of the left orbit of skeleton 82- probable scurvy;



Plate 7–B: Ectocranial orang-pee-like porosity of adult scurvy on the cranial vault of skeleton 7- healed scurvy



Plate 7–C: Four vertebrae of skeleton 75 showing the smooth dripping candlewax-like osteophyte formation of DISH.

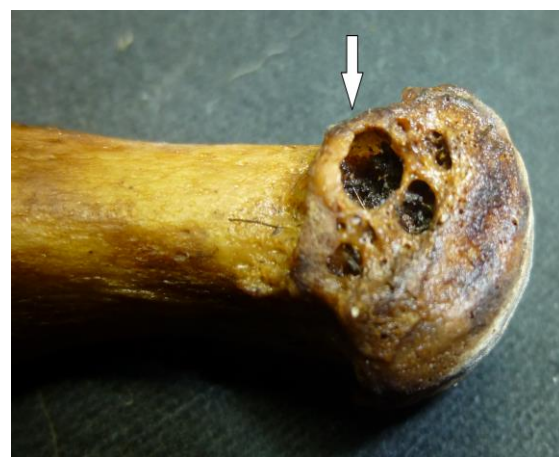

Plate 7–D: The left first metatarsal of the big toe of skeleton 5 showing several small-walled cysts-like juxta-articular lesions (arrow) suggestive of gout.

Plate 7: Selected metabolic pathological lesions in the Wargrave assemblage

Hyperostosis frontalis interna

Hyperostosis frontalis interna (HFI) is an asymptomatic condition characterised by a single or multiple bony nodules on the inner table of the frontal bone of the cranium. The condition is extremely common in elderly females in both modern and archaeological assemblages. For example, in the St Bride's Church, Fleet Street, London, assemblage (AD 1676- 1853), 21.6% of named females displayed HFI, of which 75% were older than 60 years (Bekvalac and Western 2014). Rates in males are very much lower- an approximate male: female ratio of 12:1 (Wliczak and Mulhern 2012) or 5-8% (She and Szakacs 2004). HFI is thought to be hormonally mediated, particularly in relation to changing oestrogen levels following the menopause, but has also been associated with diabetes mellitus, obesity and some inherited disorders, such as Morghagni-Stewart-Morel and Troell-Junet Syndromes (She and Szakacs 2004). The cranium of one older adult female (sk 59) of the Wargrave assemblage displayed a mild form of HFI.

Diffuse idiopathic systemic hyperostosis (DISH) or Forestier's Disease

Diffuse idiopathic systemic hyperostosis (DISH) is another condition most commonly found in older adults, but often more in males than females: 4% and 2.5%, respectively, in modern subjects over the age of 40 years (Waldron 2009). As the name suggests, the cause of DISH is poorly understood, but does appear to be metabolic, possibly hormonal in nature, and in modern subjects, has been associated with obesity, diabetes mellitus and a rich diet. Archaeologically, it was first identified in medieval monks, who often enjoyed a much more lavish diet than their lay counterparts, and in higher status individuals, who also dined too well. In modern subjects, DISH has been associated with increased risk factors for cardiovascular disease, such as strokes (*Ibid.*).

DISH involves an exaggerated systemic tendency to ossify or turn soft tissue to bone (so-called 'bone-forming'). Tissues include cartilage (most commonly of the costal rib ends, thyroid and tracheal rings), muscles, tendons and ligaments, and most characteristically, the longitudinal ligaments of the spine. Osteologically, this last manifests as large smooth osteophytes with the appearance of melted candle wax, which fuse contiguous thoracic vertebrae together along the right side of the spinal column (Roberts and Manchester 2005; Waldron 2009). Fusion of at least four contiguous vertebrae is required for a definitive diagnosis of DISH, but bone-formers showing this general pattern of vertebral fusion may well represent less advanced cases. Ragged bony ridging often demarcates the insertion of muscles, tendons and ligaments on multiple bones of the skeleton. Calcified cartilage, particularly costal and thyroid cartilage, are often recovered with the skeleton.

Although there were at least six skeletons of the Wargrave assemblage showed a general tendency to bone-forming, this pattern was only pronounced enough in three (older adult males sk 3, sk 50 and sk 75) to consider DISH. In sk 50, thoracic vertebrae 6-9 were fused by candle wax-like osteophytes on the right side, with the intervertebral disc spaces maintained. Enteseal changes were pronounced at muscle insertion sites, as was costal cartilage ossification. Smooth candle wax-like osteophytes fused together thoracic vertebrae 9 and 10 (T9 and 10) on the right side of sk 75 (Plate 7-C), maintaining the intervertebral disc spaces. Large smooth osteophytes on T7 and 8, and T8 and 9 articulated but had not yet fused. Medium to large osteophytes were present on several other mid-thoracic and lumbar vertebrae. There was a general bone-forming tendency across the skeleton, with pronounced ridging at multiple muscle insertion sites. A large smooth osteophyte fused together the right ilium and sacrum of the pelvis, surrounding but not including the sacroiliac joint itself, which remained unfused. Although four contiguous vertebrae had not fused in this skeleton, the general appearance and patterning of these pathological changes is undoubtedly DISH. In sk 3, a similar pattern of smooth, candle-wax-like ankylosis (fusion) of T9 and T10, and articulation but not fusion of osteophytes,

was present between T7 and 8, and T10 and T11. These bony outgrowths all occurred on the right side of the bodies. The intervertebral disc spaces had been maintained- features characteristic of DISH. However, differential diagnosis was complicated by co-existing degenerative changes and osteoarthritis in the spinal column, including cervical spondylosis, eburnation in the neck and lower lumbar spine (L5 and S1), and osteophytosis throughout, as well as marked Schmorl's nodes and crush fractures of the bodies of T7 and 9. It would appear that this older male suffered from two simultaneous conditions of DISH and osteoarthritis, which rendered his back stiff and probably painful.

Interestingly, none of the three Wargrave males with DISH showed archaeological evidence of higher status, such as elaborate coffins. Skeleton 3 was buried in a plain coffin with no fittings, sk 50 in a modest coffin with iron grips and grip plates, but which was otherwise plain, and sk 75 was buried uncoffined. It is possible that sk 3 and sk 75 predated the fashion for elaborate coffin fittings, but the coffin of later post-medieval burial 50 was consistent with lower socioeconomic status.

Calculi (possible gall stones or bladder stones)

Two small, round 'balls' of ossified or calcified tissue were discovered during the washing of post-medieval mature adult male sk 58. Their location in the body is unknown. The balls measured 6 mm and 9 mm in diameter. Both were broadly spherical, but with several slight undulations in the surface, which was penetrated by a few isolated foramina (holes). The balls were the same colour of the skeleton, and had the dense, smooth appearance of cortical bone. However, the composition of the tissue is unknown, as chemical and histological analysis was not undertaken. Without this analysis, it is problematic to determine the nature of these 'calculi' or stones. Possibilities are gall, bladder or kidney stones, or ossified soft tissue, such as lymph nodes. Modern examples are very varied in size and appearance, making comparison with and diagnosis of archaeological examples problematic. However, the roundness and surface density (almost sclerotic) appearance of the 'balls' compares most closely to gall stones (Biehler-Gomez et al. 2019). They have a very similar appearance to two gall/ kidney stones discovered in an older female from the Baptist cemetery in Poole, Dorset (McKinley 2008).

Sk 58 was very incomplete, comprising the left side of the torso, left arm and femur only. No other pathology, bar slight spinal degenerative joint disease, was noted on the skeleton.

Joint disease

Degenerative joint disease and osteoarthritis

Degenerative joint disease (DJD) and osteoarthritis are the most common pathological skeletal conditions in both modern and past populations. As the name implies, DJD involves the degeneration of the cartilage and bone of any joint surface of the skeleton, but is most common in the spine, hips, shoulders and knees. DJD develops with advancing age, through general wear-and-tear of the joint over life (Rogers and Waldron 1995). However, degenerative changes may be accelerated by repetitive activities involving a particular joint (e.g. the elbow), ultimately leading to osteoarthritis (OA). There is also a strong genetic component in the development of OA in particular joints, especially the hip, which has strong familial associations and occurs overwhelmingly in individuals of European ancestry (Hoagland and Steinbach 2001). Genetic predisposition, body mass index and sex may influence disease development in other joints (Weiss and Jurmain 2007). In addition to the above primary osteoarthritis, osteoarthritis may develop secondary to altered body mechanics following trauma (e.g. malaligned fracture), developmental anomalies (e.g. hip dysplasia or slipped epiphyses) and metabolic diseases (e.g. osteoporosis).

A joint under stress initially develops bony outgrowths on the joint margins (osteophytosis), or new bone deposition on the joint surface (spondylosis). Bony resorption often also occurs below the cartilaginous surface of the joint, resulting in porosity of the bone surface and the development of subchondral cysts, which fill with synovial fluid from the joint capsule (Roberts and Manchester 2005; Waldron 2009). In advanced joint degeneration, the joint cartilage is eventually worn away, exposing the underlying bone. Bone-on-bone articulation results in densification (sclerosis) and then polishing (eburnation) of the bone of the joint surfaces. This eburnation is regarded as pathognomic of OA, and has been used to diagnose OA in this report.

Degenerative joint changes were identified in 54 skeletons of the Wargrave assemblage (CPR 60.7%). Thirty-eight skeletons had at least one vertebra present to assess for **spinal DJD and OA**. All but four displayed some SDJD (primarily in the form of osteophytosis) (89.5%). Porosity of the joint surfaces was also sometimes present. The severity of these changes was only slight in ten of the skeletons, moderate in nine, and marked in 12 individuals. Marked DJD was accompanied by eburnation in eight individuals (sk 3, sk 9, sk 38, sk 42, sk 50, sk 67, sk 73 and sk 91) - diagnostic of osteoarthritis. Interestingly, seven of these individuals were male, whilst gracile sk 42 was of unknown sex. All were adult, and all four that could be aged more precisely were older adults.

DJD affecting the joints of the skeleton other than the spine is referred to as extra-spinous degenerative joint disease (ESDJD). Table 21 presents the rate of ESDJD in those joints where at least one joint surface was sufficiently well preserved to observe for osteophytosis, porosity, subchondral cysts and/or eburnation. The rates given are true prevalence rates per joint present, with the exception of the ribs, metacarpophalangeal, metatarsophalangeal and interphalangeal joints, which are *per capita* rates.

As with SDJD, most ESDJD manifested as minor or moderate marginal lipping, but in some joints, such as the temporomandibular joint of the jaw, and the acromioclavicular joint of the shoulder, osteophytosis was often accompanied by porosity, in some cases marked. Eburnation was present on one right acromioclavicular joint. The hips were also more affected than other joints, with marginal lipping, subchondral cysts and porosity being marked in three cases. Eburnation was present in two left and one right hip joint, including those of older male sk 66 where advanced osteoarthritis was bilateral. Overall, ESDJD of the knee joint was confined to slight marginal osteophytosis. The exception was

Joint	Left				Right			
	n	N	Prevalence (%)	Eburnation	n	N	Prevalence (%)	Eburnation
Temporomandibular	11	17	64.7	0	10	20	50	0
Acromioclavicular	11	19	57.9	0	19	21	90.5	1
Shoulder	17	24	70.8	0	19	24	79.2	0
Elbow	6	23	26.1	1	13	23	56.5	1
Metacarpophalangeal	3	21	14.3	1	3	25	12.0	0
Hand phalangeal	2	22	9.1	0	1	24	4.2	0
Rib	15	30	50.0	0	16	26	61.5	0
Hip	16	27	59.3	2	11	25	44.0	1
Knee	4	17	23.5	1	4	15	26.7	0

Ankle	0	9	0.0	0	0	12	0.0	0
Metatarsophalangeal	3	12	25.0	0	3	12	25.0	0
Foot phalangeal	0	9	0.0	0	0	12	0.0	0

Table 21: Extraspinous degenerative joint disease in the major joints (CPR of those with preserved joints) and frequency of eburnation (osteoarthritis) in the Wargrave assemblage; n= number of affected joints; N= total number of joints present.

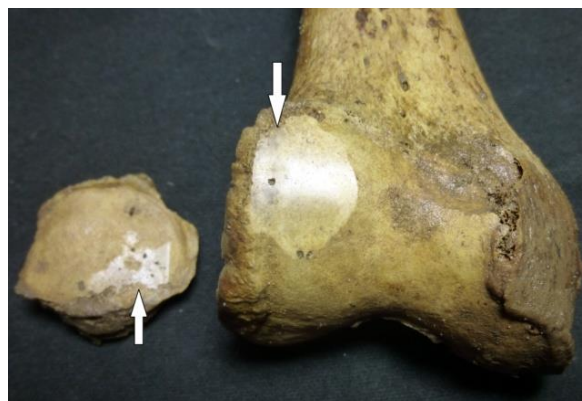

Plate 8–A top left: Marked Schmorl's node on the inferior end plate of a lumbar vertebra of skeleton 73 (arrow). Note the moderate marginal osteophytes also present.

Plate 8–B top right: Osteoarthritis of the right knee of skeleton 12, showing eburnation of the lateral condyle and patella (knee cap) (arrows).

Plate 8–C bottom left: Marked osteoarthritis of the right hip joint of skeleton 66, showing eburnation, porosity, osteophytosis and subchondral cyst formation on the femoral heads.

Plate 8: Selected joint disease in the Wargrave assemblage

the right knee of unsexed adult sk 12 (comprising only the right lower limb), which showed marked eburnation of the femoral (thigh bone) and patellar (knee cap) joint surfaces (Plate 8–C). In the Wargrave assemblage, few joints of the hands and feet showed degenerative changes. The exception was skeleton 38, where multiple joint surfaces of the wrist (radial, ulnar and carpal joints) showed marked eburnation and osteophytosis of advanced OA.

Thus, whilst marginal lipping of many joint surfaces was extremely common, reflecting the older age of this assemblage, only seven joints displayed eburnation of osteoarthritis. With the possible exception of OA of the elbow in probable older male sk 82 and older female sk 83, there is no strong evidence for occupationally- induced ESDJD. Degenerative changes in the spine were more marked than in the rest of the skeleton, but here too only seven showed eburnation of OA. Given the historically attested advanced age of many individuals buried in St Mary's churchyard, and their predominantly working class, agricultural lifestyle, it is perhaps surprising that a higher prevalence of OA was not present.

Schmorl's nodes

Schmorl's nodes are a vertebral condition thought to develop primarily in youth, and are associated with strenuous activity involving axial loading of the spine in childhood or adolescence, when the end plates of the vertebral bodies are still supple (Resnick and Niwayama 1995). They manifest as depressions in the superior and inferior end plates, and are due to compression of the end plate by adjacent intervertebral disc herniation (Plate 8–A) (Faccia and Williams 2008; Resnick and Niwayama 1995). Overwhelmingly, they are found in the mid-thoracic to lumbar vertebrae.

The vertebral bodies largely comprise trabecular (spongy) bone and preserve less well archaeologically than compact bone. Hence, many vertebral bodies of the Wargrave skeletons had suffered partial damage or complete destruction. Only those superior and inferior end plates (the upper and lower surfaces of the vertebral bodies) that survived sufficiently well enough to observe Schmorl's nodes were included in the analysis. Only 46 skeletons had one or more preserved T1-S1 vertebral end plates, of which only seven individuals did not display at least one Schmorl's node, of which one was sk 40, aged 9-11 years. However, due to skeletal incompleteness and variable preservation, it is more meaningful to calculate Schmorl's node prevalences per end plate rather than per individual. These data are presented as a percentage of each surviving end plate and not by the individual or by the vertebra (Figure 24 and Table 22).

There were no Schmorl's nodes in the cervical (neck) vertebrae or in the uppermost four thoracic vertebrae (T1-4). Overall TPR in the spinal regions is given in Table 22 below, and by end plate in Figure 24. Rates increased down the spinal column from the fifth to the tenth thoracic vertebra, peaking at 60.6% of inferior T10 end plate. Rates then steadily dropped off in the lower two thoracic vertebrae and lumbar spine to the first sacral end plate (7.4%). The inferior or lower end plates were very much more affected than the superior end plates. The above pattern is broadly typical of Schmorl's node distributions in other archaeological assemblages.

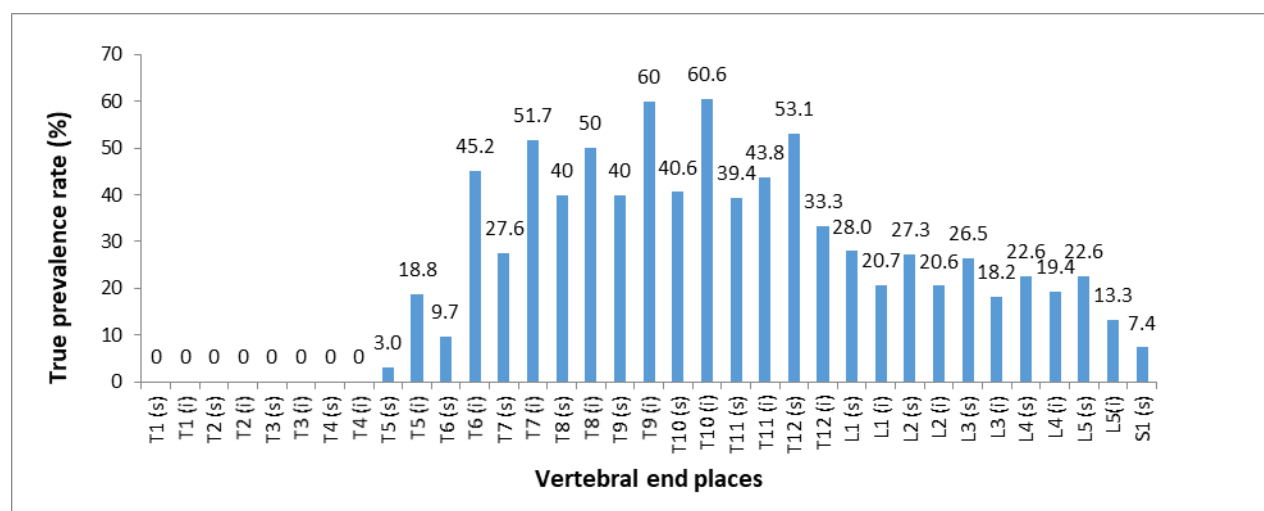


Figure 24: True prevalence of Schmorl's nodes in thoracic, lumbar and first sacral end plates (s= superior end plate; i= inferior end plate); N= 1,092 end plates. Percentages given in the graph are the TPR of each end plate.

Vertebrae	n	N	TPR (%)
T1-6	24	381	6.3
T7-12	168	373	45
L1-5	68	311	21.9
S1	2	27	7.6
Total	262	1092	24

Table 22: True prevalence of Schmorl's nodes in the end plates of the upper (T1-6) and lower thoracic vertebrae (T7-12), the lumbar vertebrae (L1-5) and first sacral segment (S1); n= number of Schmorl's nodes present; N= number of end plates present; TPR= true prevalence rate.

The prevalence of Schmorl's nodes is high in the Wargrave assemblage when compared with the maximum per vertebra rates in post-medieval working class skeletal assemblages from St Martin's-in-the Bullring, Birmingham (47%) (Brickley and Buteux 2006) and the Crossbones burial ground, Southwark, London (39%). This may reflect very strenuous occupational activities involving loading of the spine from an early age in the rural community of Wargrave.

Neoplasms

Ivory osteomata

Ivory or button osteomata are common benign neoplasms or tumours, which are found on the outer or ectocranial surfaces of the frontal and parietal bones of the cranial vault of older adults. They appear as small, raised, round bumps with a sclerotic (dense) texture (Roberts and Manchester 2005), and are clinically insignificant. They were present on three crania of the Wargrave assemblage (male sk 7, sk 60 and sk 85). Sk 7 and sk 60 were older adults, but the age of sk 85 is less clear due to skeletal incompleteness. However, advanced ectocranial suture closure and alveolar recession from long-standing antemortem tooth loss suggests that he too was an older adult.

Discussion

The assemblage of 89 individuals excavated in the northern churchyard of St Mary's, Wargrave, is a very small sample of the total burial population, which temporally spans at least 800 years of the settlement of Wargrave. Parish burial registers of AD 1538-1899 record over 6,700 interments. Burials in the medieval and possibly late Saxon periods are additional to this number. Thus, the skeletal assemblage discussed in this report is a tiny proportion of the whole. It is difficult to assess how representative this assemblage is of the whole population, but artefactual evidence from coffins, strongly suggests that many buried in this part of the churchyard comprised the poorer section of Wargrave's population, at least in the post-medieval period. Bony definition at muscle insertion sites on multiple long bones in most adult skeletons supports the general picture that the skeletal assemblage largely comprised working class individuals of the parish. The superstitious aversion to burial within the dark, cold northern part of the churchyard resulted in it being the burial location of the poor and the dispossessed (such as suicides, strangers and workhouse inmates) until well into the Victorian period.

When the demography of burials recorded in parish records is compared with that of the skeletal assemblage, considerable differences are apparent. Throughout the post-medieval period, the burial registers record a consistent pattern of slightly more males to females

(1:0.9). This includes individuals of all ages. From 1813, when the name and age of the deceased was given, it was possible to calculate the proportion of adult males to females (204: 195 or 1: 0.96, respectively). Osteologically, it is not possible to sex non-adults, but overall, they comprised less than 10% of the total assemblage. Fifty-two adult skeletons could be sexed from skull and pelvic morphology, and these revealed almost twice as many males than females. The reason for this major disparity between the historical and osteological data is unclear. One possible factor is the tendency for the skulls of older females to appear more masculine in character, as a consequence of hormone changes associated with the menopause. Careful checking revealed that very few Wargrave skeletons were sexed solely skull morphology, so this is unlikely to be a significant factor in the overrepresentation of adult males in this assemblage.

Another very evident disparity is the underrepresentation of infants and young children in the skeletal record. Burial records of the 19th century indicate that infants below two years comprised almost one in five (18.4%) of all interments. It is unclear if this held true for earlier centuries, but certainly, for most working class women and their infants in the past, childbirth was potentially a very hazardous undertaking. Weaning was another critical and dangerous period in an infant's life. Malnutrition and infection were major factors limiting the survival of many infants and children in the past, as in many non-Western societies today. Thus, the high historical infant mortality in Wargrave is unsurprising. What is unexpected is the complete absence of infants and children below the age of five years in the skeletal assemblage. Together with the dearth of adult females, this absence strongly suggests zoning within the churchyard: that many mothers and their infants were buried elsewhere in the churchyard and were not archaeologically excavated in this project.

When considering the age distribution of Wargrave skeletal assemblage, it was clear that a very substantial portion of the population had survived beyond the age of 45 years. Indeed, historical analysis of the 19th century burial records revealed that, in this period at least, there were a significant number of septogenarians and a few surviving into their 90s. The high rate of degenerative joint disease may probably be explained by this older demographic, but activity undoubtedly contributed to joint wear-and-tear.

Similarly, many pathological lesions on the skeleton are attritional, and hence, are more common in older populations. For example, the very high rates of dental disease, especially antemortem tooth loss, is probably in part due to this older demographic. The dental disease rates in the Wargrave assemblage compared much more closely with middle class assemblages of St George's Church, Bloomsbury, and the King's Lynn Quakers- both older assemblages. However, it should be noted that dental disease was present in all age groups at Wargrave, including children's milk teeth, suggesting that tooth decay and loss began early in life. This probably reflects poor oral hygiene and a diet rich in carbohydrates. In the later post-medieval period, the culprit was probably cane sugar.

In terms of general health of the Wargrave population, the osteological evidence is slightly contradictory. Final adult stature is widely used as a yardstick of the general health of populations, both past and present. With a mean stature of 169.5 cm, Wargrave males were slightly shorter than several small-town medieval populations in the region. Male stature fell between values noted for multiple working class and middle class assemblages of the 18th and 19th centuries. In contrast, mean female stature was considerably higher than other medieval assemblages, and slightly higher than many post-medieval ones. This would tentatively suggest a slightly higher status of females in Wargrave, especially in earlier centuries. However, all interpretations must be tempered by the reflection that these means are based on very small sample sizes, which may well result in unrepresentative data.

Another measure of the health of a population is the health and survivorship of infants and children. The parish burial records indicate that, like many populations in the past, there was a high rate of infant and child deaths in Wargrave, at least in the post-medieval period. This was not reflected archaeologically (see above). None of the non-adults in the skeletal assemblage displayed bony lesions suggestive of chronic ill health or malnutrition, such as scurvy, rickets, anaemia or periostitis. However, one child had experienced considerable growth stunting, strongly suggestive of chronic ill-health. Similarly, in adults osteological evidence for malnutrition was slight. Possible scurvy was the most common, but diagnosis was tentative, and may reflect seasonal shortages of green vegetables and fruit in winter and early spring.

Most adult skeletons, both male and female, displayed defined muscle insertions, especially on the arm bones, suggestive of a lifestyle that involved strenuous, repetitive physical activities of the upper body. Bony evidence of spinal loading in childhood or adolescence (such as carrying heavy loads in the arms or on the head), suggests that work started early in life for many parishioners. This is may also be true of the two individuals with *osteochondritis dissecans*, although it must be acknowledged that such lesions may be incurred during sport or play activities as well as work.

Two unusual fractures seen in the Wargrave assemblage may also be occupationally-related: Shepherd's fractures of the talus and third metacarpal styloid fractures. High prevalences of both fractures have been observed in 18th century Royal Navy skeletons, and of the former, in female Lancashire handloom weavers. It is probable that Shepherd's fractures in the females in Wargrave were also related to driving a treadle during cottage-industries of weaving or spinning. Although, fanciful, the presence of bilateral Shepherd's and other fractures and possible scurvy in sk 7 tentatively suggests that at one time in his life, he was a sailor. All third metacarpal fractures were noted in the right hand of five males, and are likely to be activity-related injuries. This high prevalence in Wargrave may reflect the engagement of many Wargrave men in the river trade, with these injuries incurred during rowing, poling or sailing river craft. Alternatively, these riverine activities may have been recreational. Chronic sinusitis appeared to affect females more than males, and may reflect greater exposure to smoke and soot of domestic fires, particularly during cooking.

There was relatively little osteological evidence for chronic infectious disease. Of the 13 individuals with periostitis, several may have been scorbutic rather than infective in origin. There were two probable tuberculosis, one definite and one probable syphilis case. One other individual had tibial periostitis thick enough to tentatively suggest a third syphilitic in the assemblage, but this may well have been non-specific infection. There were no other cases of osteitis or osteomyelitis.

Conclusion

Although numerous small archaeological excavations have been undertaken in country churchyards across Britain, many skeletal assemblages from these excavations are too small for meaningful analysis. Although not large by urban excavation standards, the 89 Wargrave skeletons in this analysis constitute a fairly large and therefore, significant assemblage when exploring country life and health in the past. Whilst documentary sources may tell us much about past societies, their record is often biased towards the literate and the affluent, and our understanding of the lives of more humble country people is partial and probably inaccurate. Archaeology and osteology carry with them their own limitations, but are different but valuable complementary approaches to studying the past. This osteological study had provided a window into the lives health and activities of the common people that lived in Wargrave in the past, and has demonstrated some new insights

into how the lifestyle, occupation and activities of past parishioners impacted on their health and longevity.

References

- Anderson T, and Boston C. 2018. *Human remains*. In: Soden I, editor. *Excavation of the late Saxon and medieval churchyard of St Martin's, Wallingford, Oxfordshire*. Oxford: Archaeopress Archaeology. p 47-68.
- Aufderheide AC, and Rodriguez-Martin C. 1998. *The Cambridge encyclopedia of human paleopathology*. Cambridge: Cambridge University Press.
- Barratt J. 2015. *Cavalier capital- Oxford in the English Civil War 1642-1646*. Solihull: Helion and Company.
- Berkshire Family History Society. 2012. *Parish registers from 1538 onwards for the Parish Church of St Mary's, Wargrave, Berkshire, Archdeaconry of Berkshire Diocese of Oxford*. Records transcribed, checked and indexed by the Berkshire Family History Society; available on CD
- Berkshire Record Office R. consulted 2018. *Enclosures in Berkshire*. Online database of record office holdings. p http://www.berkshireenclosure.org.uk/find_via_parish_details.asp?parish=Wargrave.
- Boersma B, and Wit JM. 1997. *Catch-up growth*. *Endocrine Reviews* 18(5):646-661.
- Boston CV. 2017. *Boys at sea: an osteological and historical analysis of ships' boys in the late eighteenth to early nineteenth century British Royal Navy*. In: Crawford S, Shepherd G, and Hadley D, editors. *Oxford Handbook of the Archaeology of Childhood*. Oxford: Oxford University Press.
- Boston CV, Boyle A, Gill J, and Witkin A. 2009. *'In the vaults beneath' - archaeological recording at St George's Church, Bloomsbury*. Oxford: Oxford Archaeology Monographs No. 8.
- Boyle A, and Keevil G. 1998. *'To the praise of the dead and anatomie': the analysis of post-medieval burials at St Nicholas' Church, Sevenoaks, Kent- archaeological recording* In: Cox M, editor. *Grave concerns: death and burial in England 1700-1850*. York: Council for British Archaeology Research Report 113. p 85- 96.
- Brady K, Smith A, and Laws G. 2007. *Excavation at Abingdon West Central Redevelopment: Iron Age, Roman, medieval and post-medieval activity in Abingdon*. *Oxoniensia LXXII*:107-201.
- Brickley M, and McKinley J. 2004. *Guidelines to the standards for recording human remains* Reading: BABAO and the IFA.
- Brooks ST, and Suchey JM. 1990. *Skeletal age determination based on the os pubis: a comparison of the Acsadi-Nemerskeri and Suchey-Brooks method*. *Human Evolution* 5:227- 238.
- Buckberry JL, and Chamberlain AT. 2002. *Age estimation from the auricular surface of the ilium: a revised method*. *American Journal of Physical Anthropology* 119:23-29.
- Buikstra JE, and Ubelaker DH. 1994. *Standards for data collection from human skeletal remains*. Research Series No 44. Arkansas USA: Arkansas Archaeological Survey.
- Case DT, and Heilman J. 2005. *Pedal symphalangism in modern American and Japanese skeletons*. *Homo* 55(3):251-262.
- Chambers J. 1999. *Berkshire machine-breakers- the story of the 1830 riots*. Letchworth: J. Chambers.
- Cherryson A, Crossland Z, and Tarlow S. 2012. *A fine and private place- the archaeology of death and burial in post-medieval Britain and Ireland*. Bristol: Leicester Archaeology Monograph No. 22.

- Cox M. 2000. Ageing adults from the skeleton. In: Cox M, and Mays S, editors. *Human Osteology in Archaeology and Forensic Science*. London: Greenwich Medical Media. p 61-82.
- Dils JA. 1989. Epidemic, mortality and civil war in Berkshire 1642-6. *Southern History* 11:40-52.
- Ferembach D, Schwidetsky I, and Stloukal M. 1980. Recommendations for age and sex diagnosis of skeletons. *Journal of Human Evolution* 9:517- 549.
- Floud R, Wachter K, and Gregory A. 1990. *Height, health and history- nutritional status in the United Kingdom 1750-1980*. Cambridge: Cambridge University Press.
- Galloway A. 1999. *Broken bones- anthropological analysis of blunt force trauma*. Springfield, USA: Charles C Thomas Publisher Ltd.
- Garland AN. 1989. The taphonomy of inhumation burials. In: Roberts CA, Lee F, and Bintliff J, editors. *Burial archaeology: current research, methods and developments*. Oxford: British Archaeological Review British Series 211. p 15-37.
- Gilchrist R, and Sloane B. 2005. *Requiem: the medieval monastic cemetery in Britain*. London: Museum of London Archaeological Services.
- Goodman AH, and Rose J. 1990. Assessment of systemic physiological perturbations from dental enamel hypoplasias and associated histological structures. *Yearbook of Physical Anthropology* 33:59-110.
- Gray R, and Griffiths S. 1986. *The Book of Wargrave* Wargrave Local History Society Publication; Oxford University Printing House.
- Harvey L. 2014. Human remains. In: Harvey L, Denis S, and Williams G, editors. *An archaeological excavation at All Saints' Church, Faringdon, Oxfordshire*. Wheatley, Oxfordshire: unpublished site report prepared by John Moore Heritage Services.
- Henderson J. 1987. Factors determining the state of human remains. In: Boddington A, Garland AN, and Janaway RC, editors. *Death, decay and reconstruction- approaches to archaeology and forensic science*. Manchester: Manchester University Press. p 43-54.
- Hillam C. 1990. *The roots of dentistry*. London: British Dental Association Publications.
- Hillson S. 1996. *Dental anthropology*. Cambridge: Cambridge University Press.
- Hoppa R. 1992. Evaluating human skeletal growth- an Anglo-Saxon example. *International Journal of Osteoarchaeology* 2:275- 288.
- House of Lords. 1831. *Minutes of Evidence taken before the Select Committee of the House of Lords appointed to consider of the Poor Laws, December 1830 and March-April 1831*. London: available free online via google books. p 431-436.
- Humphrey L. 2000. Growth studies of past populations: an overview and an example. In: Mays S, and Cox M, editors. *Human osteology in archaeology and forensic science*. London: Greenwich Medical Media. p 23- 38.
- Iskan MY, Loth SR, and Wright RK. 1984. Age estimation from the ribs by phase analysis: white males. *Journal of Forensic Science* 29:1094- 1104.
- Janaway RC. 1996. The decay of buried human remains and their associated materials. In: Hunter J, Roberts CA, and Martin A, editors. *Studies in crime: an introduction to forensic archaeology*. London: Routledge. p 58-85.
- John Moore Heritage Services. 2017. *St Mary's Church, Wargrave desktop assessment, geophysical survey and field evaluation*. Wheatley, Oxfordshire: unpublished archaeological report.
- Jurmain R, Kilgore L, and Thravathen W. 2009. *Essentials of physical anthropology*. 7th ed. Belmont, USA: Wadsworth Cengage Learning.
- King P. 2016. *Late Victorian Wokingham*. Wokingham: The Wokingham Society.

- Knusel CJ. 2007. *Activity-related skeletal change*. In: Fiorato V, Boylston A, and Knusel CJ, editors. *Blood red roses- the archaeology of a mass grave from the Battle of Towton AD 1461*. Oxford: Oxbow Books. p 103-118.
- Krogman WM, and Iscan MY. 1986. *The human skeleton in forensic medicine*. Springfield, USA: Charles C. Thomas.
- Larsen CS. 1997. *Bioarchaeology- interpreting behavior from the human skeleton*. Cambridge University Press.
- Levin J, editor. 2003. *periodontal disease (pyorrhea)*. Cambridge: Cambridge University Press. 244-247 p.
- Lewis M. 2007. *Bioarchaeology of children- perspectives from biological and forensic anthropology*. Cambridge: Cambridge University Press.
- Litten J. 1991. *The English Way of Death- the common funeral since 1450*. London: Robert Hale Publishers.
- Lovejoy CO, Meindl RS, Pryzbeck TR, and Mensforth PR. 1985. *Chronological metamorphosis of the auricular surface of the ilium: a new method for determination of adult skeletal age-at-death*. *American Journal of Physical Anthropology* 68:15- 28.
- Lukasc JR, editor. 1989. *Dental pathology: methods for reconstructing dietary patterns*. New York: Wiley Liss. 261- 286 p.
- Maresh MM. 1955. *Linear growth of the long bones of the extremities from infancy through adolescence*. *American Journal of the Diseases in Childhood* 89:725- 742.
- May T. 1996. *The Victorian Undertaker*. Princes Risborough, U.K.: Shire Publications.
- Mays S. 1998. *The archaeology of human bones*. London and New York: Routledge.
- Mays S. 2007. *Wharram: a study of a settlement on the Yorkshire Wolds*. York: Department of Archaeology, University of York.
- Mays S, Brickley M, and Dodwell N. 2004. *Human bones from archaeological sites- guidelines for producing assessments and analytical reports*. Swindon: English Heritage and BABAO.
- McKinley J. 2004. *Compiling a skeletal inventory: disarticulated and co-mingled remains*. In: Brickley M, and McKinley J, editors. *Guidelines to the standards for recording human remains*. Southampton: IFA Paper NO. 7, Institute of Field Archaeologists. p 9-13.
- Meindl RS, and Lovejoy CO. 1985. *Ectocranial suture closure: a revised method for the determination of skeletal age based on the lateral-anterior sutures*. *American Journal of Physical Anthropology* 68:29- 45.
- Meindl RS, Lovejoy CO, Mensforth PR, and Carlos LD. 1985. *Accuracy and direction of error in sexing of the skeleton* *American Journal of Physical Anthropology* 68:79- 85.
- Mintz S. 1985. *Sweetness and power: the place of sugar in modern history*. New York: Penguin.
- Molleson T, Cox M, Waldron HA, and Whittaker DK. 1993. *The Spitalfields Project- the anthropology. The middling sort*. York: CBA Research Report No 86.
- Moorrees CFA, Fanning EA, and Hunt EE. 1963. *Age variation of formative stages for ten permanent teeth*. *Journal of Dental Research* 42:1490- 1502.
- Musgrave T, and Musgrave W. 2000. *An empire of plants- people and plants that changed the world*. Cassell Illustrated.
- Nawrocki SP. 1995. *Taphonomic processes in historic cemeteries*. In: Grauer A, editor. *Bodies of evidence- reconstructing history through skeletal analysis*. New York: Wiley-Liss. p 49-66.

- O'Connell L. 2004. *Guidance on recording age at death in adults*. In: Brickley M, and McKinley J, editors. *Guidelines to the standards for recording human remains*. Reading: Institute for Archaeologists Paper 7. p 18-21.
- Ogden A. 2008. *Advances in the palaeopathology of teeth and jaws*. In: Pinhasi R, and Mays S, editors. *Advances in human palaeopathology*. Chichester, U.K.: John Wiley and Sons Ltd.
- Ortner DJ. 2003. *Identification of pathological conditions in human skeletal remains*. London and San Diego: Elsevier Academic Press.
- Pecina M, and Bojanic I. 1993. *Overuse injury of the musculo-skeletal system*. London: CRC Press.
- Preece MA. 1996. *The genetic contribution to stature*. *Hormone Research in Paediatrics* 45:56-58.
- Raina D, Gothi R, and Rajan S. 2009. *Eagle syndrome*. *Indian Journal of Radiology and Imaging* 19(2):107-108.
- Roberts CA, and Cox M. 2003. *Health and disease in Britain from prehistory to the present day*. Stroud: Sutton Publishing.
- Roberts CA, and Manchester K. 2005. *The archaeology of disease*. 3rd ed. Stroud: Sutton Publishing Ltd.
- Roden B. 1997. *Dental attrition and age in the Newcastle Blackgate and Newcastle Infirmary populations*. Sheffield: University of Sheffield.
- Schaefer M, Black S, and Scheuer L. 2009. *Juvenile osteology: a laboratory and field manual*. London, Buringdon and San Diego: Elsevier.
- Scheuer L, and Black S. 1990. *Developmental juvenile osteology*. San Diego: San Diego Academic Press.
- Scheuer L, and Black S. 2000. *Development and ageing of the juvenile skeleton*. In: Cox M, and Mays S, editors. *Human osteology in archaeology and forensic science*. London: Greenwich Medical Media. p 9-22.
- Silventoinen K. 2003. *Determinants of variation in adult body height*. *Journal of Biosocial Science* 35:263- 285.
- Smith BH. 1991. *Standards of human tooth formation and dental age assessment*. In: Kelley MA, and Larsen CS, editors. *Advances in dental anthropology*. New York: Wiley-Liss. p 143-168.
- Soden I. 2018. *Excavation of the late Saxon and medieval churchyard of St Martin's, Wallingford, Oxfordshire*. Oxford: Archaeopress Archaeology.
- Stirland AJ. 1987. *A possible correlation between os acromiale and occupation in the burials from the Mary Rose*. *Proceedings of the 5th European meeting of the Palaeopathology Society, Sienna, Italy*:324- 334.
- Sutherland LD, and Suchey JM. 1991. *Use of the ventral arch in pubic sex determination*. *Journal of Forensic Science* 36:501- 511.
- Tanner JM. 1981. *Foetus into man*. second ed. Ware: Castlemead.
- Tanner JM. 1992. *Growth as a measure of the nutritional and hygienic status of a population*. *Hormone Research in Paediatrics* 38(Suppliment 1):106-115.
- Townley S. 2009. *Henley-on-Thames- town, trade and river*. Chichester: Phillimore & Co. Ltd.
- Trotter M. 1970. *Estimation of stature from intact long bones*. In: Stewart TD, editor. *Personal identification in mass disasters*. Washington, USA: Smithsonian Institute. p 71- 83.
- Turner-Walker G. 2008. *The chemical and microbial degradation of bones and teeth*. In: Pinhasi R, and Mays S, editors. *Advances in human palaeopathology*. Chichester: John Wiley and Sons Ltd. p 3-30.

- Wakely J. 2006. *The human skeletal assemblage. Unpublished osteological report on excavated medieval skeletons from the Vineyard, Abingdon, Oxfordshire. Oxford: University of Leicester and Oxford Archaeology.*
- Waldron T. 1998. *A note on the estimation of height from long bone measurements. International Journal of Osteoarchaeology* 8:75-77.
- Waldron T. 2009. *Palaeopathology. Cambridge: Cambridge University Press.*
- Webb H. 2007. *The 18th- 19th century skeletal assemblage. In: Norton A, editor. A medieval and post-medieval graveyard at Bonn Square, Oxford. Oxford: unpublished specialist report. p 64- 101.*
- Webster N. 1758-1843. *A brief history of epidemic and pestilential disease: with principal phenomena of the physical world, which precede and accompany them, and observations deduced from the facts stated. USA: Evans Early American Imprints Collection.*
- Wordie R. 2000. *Enclosure In Berkshire 1485-1885. Reading. p 182-185.*
- Wrigley E. 2007. *English county populations in the later eighteenth century. The Economic History Review* 60(1):35-69.

APPENDIX 2:
Coffin Furniture Report

Coffin Furniture *by Simona Denis*

From the early 18th century it was common to decorate the coffin with upholstery and elaborated metal fittings. After 1730, the production of coffin furniture by stamping machines became power assisted, allowing mass production and a reduction in cost. The financial investment in funeral furnishing grew over the course of the 18th and into the 19th century, reaching its zenith in the 1840s (Rugg 1999). After that date, a taste for a simpler funeral became the norm.

More elaborated coffin furniture is therefore likely to be dated to the late Georgian-early Victorian times (Boston 2006); however, in this period coffins varied considerably in construction, materials and decoration, ranging from simple wooden coffins held together by joinery to heavily decorated, upholstered examples, as confirmed by the evidence from St Mary's.

Wargrave funerary custom

Over 46% of the 90 individuals buried at Wargrave had a coffin. 36 of the graves had metal objects indicating the presence of a wooden coffin; no remains of lead shells were recovered. Four graves presented traces of decayed coffin wood, visible as a darkening of the grave fill, although no associated metalwork was found. Two additional graves, not investigated, showed traces of wood staining.

The vast majority of the coffins were much degraded and in fragmentary condition, with only coffin furniture such as studs, fasteners, and grips being recoverable. Coffin 1/10 for SK5 was the only example that partially preserved the original wooden planks, to a maximum length of 530mm; smaller fragments were also found in the graves for SK24 and SK82. Traces of wood were also observed on the reverse of some upholstery pins.

The poor state of preservation of the coffin furniture, severely affected by oxidation, prevented from the full observation of design details; grips decoration was only partially visible. The degradation had particularly affected the thin, tin-dipped elements of the furniture (grip and breast plates, lid motifs), obliterating any decorative detail and, in most cases, reducing the items to fragments concreted around the reverse of the terminals.

All of the coffin furniture recovered during the excavation was made of iron and tin, with a single example (coffin (1/10) for SK5) of copper alloy. Iron and tin were the two cheapest materials available in the 18th century, usually associated with working class coffins in the later Georgian and Victorian eras (Boston 2008). On the other hand, the practice of painting tin grip plates in black was an expansive variant (Litten 1991), possibly to disguise the fact that the grips were made of cheap materials (Webb 2007). Black laquer was observed on 20 of the grips recovered during the excavations; a number of upholstery studs, found in association with SK2, SK36 and SK61 also preserved traces of paint.

Only 3 of the graves (SK20, SK55 and SK73) contained buttons, suggesting burial in everyday clothing. Additionally, SK82 was buried with a pocket watch and seal, positively indicating the body was clothed.

The single copper alloy shroud pin collected during the excavation was found with SK7, indicating the presence of clothes or a shroud, while the grave for SK5 contained a safety pin.

Verdigris stains caused by the presence of copper alloy pins were recorded on the skeletal remains of 8 additional individuals (SK38, SK55, SK58, SK64, SK67, SK72, SK73, SK82), although none of the items was recovered during the excavation.

Generally, the absence of any kind of clothes fastening in earlier burials suggests the body rested unclothed, wrapped in a shroud (Boston 2006).

Coffins (Table 23)

66.6% of the 41 excavated coffined burials preserved a combination of elements (coffin furniture and fittings *in situ*, remains of coffin wood, decayed wood traces) sufficient to suggest a specific coffin type.

The standard coffin shape in the 19th century was the single break, tapered towards the feet, with a flat lid; this was in fact the most common shape recorded at St Mary's. A single break coffin was positively identified in 11 instances, and suggested for an additional 13 examples (57.1% of the total), while a rectangular shape was suggested for 4 of the burials, representing 9.5% of the group. The coffin type for the remaining 15 individuals (38%) remains undetermined; in a number of cases, only limited observations were possible.

The state of preservation of the wooden planks was extremely poor; all but 5 of the recorded coffins consisted exclusively of decayed wood stains. 11 fragments of wood from the side panels were recovered from Coffin (1/10) for SK5; seven of these fragments preserved the affixed grip plates. The largest fragment measured 590x230mm. Three small wooden fragments, weighing 7.8g in total, were also recovered from coffin (13/58) for SK82. Two additional examples, of a combined weight of 4.1g, were retrieved from (1/13), backfill of the grave for SK24.

Small fragments of coffin wood were also preserved on the reverse of upholstery studs associated with SK30 and SK83.

Nineteen of the recorded coffins, representing 45% of the group, were decorated with grips and grip plates.

In most cases, these elements were associated with tinned plate fragments of undetermined function; these might have originated from degraded grip plates or additional coffin decoration, such as lid motifs and escutcheons, depicting funerary symbols.

Remains of a *departum* plate were positively identified in a single instance (SK36), although the object was too corroded to allow any further observation. A large number of tinned plate fragments, associated with traces of oxidation found on the remains, was observed for SK60, SK62 and SK73, possibly indicating the presence of breast plates. Additionally, SK82's ribs and vertebrae were found to be severely affected by the presence of a large iron plate, although only two fragments of plate were recovered.

Upholstery studs (Plate 9) were found in 25 of the burials, and in 13 instances in association with grip plates or plate fragments, in quantities comprised between 1 and 305 (SK36). The studs were used to hold textile lining (velvet or baize) in place, as well as decorative elements *per se*, arranged in patterns and, in a number of instances, covered in black laquer. Stud work is also recorded to provide biographical information (Bashford, Sibun 2007), like initials and year of death of the individual.

Upholstery pins became a common occurrence during the late 18th and early 19th century, and started to decline with the introduction of French polishing in the 1850s but survived for a century in more conservative areas (Janaway 1988).

None of the textile associated with burials was preserved, although traces of fabric were observed on the reverse of SK36 breast plate fragments, imprinted in the rust.

Due to the almost complete decaying of the coffin wood, none of the studs was recovered in its original position, with the exception of SF15, a group of 14 copper alloy studs retrieved from SK70's coffin (13/36) (Plate 9), and a second group of 24 examples (SF6

and SF7, Plate 9), found in association with SK30. Although the studs were found *in situ*, no decorative arrangement or pattern was identified.

Grip types (Plates 10-13)

A total of 80 grip plates and grips were recovered during the excavation. 8 of the examples were too corroded to allow any identification of the style or design; the remaining 72 grips preserved enough details to be grouped into 7 different types, based on the shape and decoration of both grips and grip plates, where possible. Five of the identified styles were found to be variants of known types; the remaining two designs may not be known within contemporary assemblages.

The state of preservation of the pressed tin grip plates was extremely poor; no decorative details were recorded, and in a number of cases the plate survived exclusively as oxidised residue concreted to the grip fittings. Cast iron plates, as observed in Wargrave type 1 (WASR1), were better preserved.

Although precise dating is often impossible, particularly when no *depositum* plate is recovered, a number of elements and trends in the furniture decoration can be broadly dated based on similarities with dated examples.

- WASR1 (SF1, Plate 10)

The symmetrical, slightly diamond-shaped cast iron plate presented sub-rectangular ends and was pierced in its central area by two mirroring, horizontal, heart-shaped cut-outs. The associated cast iron grip had a plain, square design with right-angle returns and a bulbous central section. Wargrave type 1 was found to be extremely similar to Kingston-upon-Thames type IVb (Bashford 2007), a less elaborate variant of Coffin 68 recovered at Rycote Chapel, dated to 1699 by its memorial plate (Boston 2008). The simple, plain rounded handle with no embellishment seems to have been most popular between the latter part of the 18th and the first half of the 19th century (Miles 2008).

17 examples of this grip type were recovered during the excavation; 8 of these were not associated to inhumations. SK7, SK30, SK55 and SK58 had one grip each, while SK36 and SK38 had two and three examples respectively.

- WASR2

A plain, cast iron grip with curved cut, very similar to Spitalfields type CCS2a (Reeve 1993). None of the associated tinned grip plates was recovered. In 6 instances, traces of black paint were observed. The type was dated between 1814 and 1845 based on the occurrence of the type at St Luke's, Islington, St Bartholomew's, Penn and St George's, Bloomsbury (Boston 2006).

This grip was the most common at Wargrave, consisting in 22 examples, associated with 7 different inhumations. A single example was recovered from SK15's grave, while SK36, SK50 and SK60 had 2 examples each; SK18 had 3 grips, SK82 had 4 and a set of 5 identical objects was associated with SK62. The remaining 2 grips were not associated with burials.

- WASR3

8 of the grips showed a plain, sub-rectangular cast iron design. Traces of a corroded pressed tin plate, although too poorly preserved to allow any observation on the decoration, were recorded for a single example. Traces of black paint were preserved on 3 of the items. This grip's design was similar to Spitalfields type CCS2b, dated to the 1839-1845 (Reeve 1993).

4 of the recovered grips were associated with SK29; a single example was found with SK4, while the remaining 3 items were not related to burials.

- WASR4 (SF2, SF10 and SF14, Plate 11)

This grip type was composed of a sub-triangular or sub-trapezoidal pressed tin plate and a decorated, black-painted square-cut grip. The severe oxidation prevented from any observation on the grip plate; the cast iron grip showed a complex decoration, with a central shield and a twisted ribbon extending toward the mounts, ending in a bow on either end. No reference for this grip design was found in the literature; however, Christ Church, Spitalfield type CCS6, dated to 1783-1852, showed a similar combination of decorative elements, although on a curved cut grip.

All of the 10 grips with decorated grip plates forming this group were recovered from coffin 9/11, associated with SK36.

- WASR5 (SF12, Plate 12)

A copper alloy, sub-rectangular grip plate with no apparent decoration associated with a curved cut, cast iron grip. The grip presented three central vertical elements and a 6-petals rosette cross-section. This grip design had no exact reference in the literature; however, its general aspect was found to be similar to St George's, Bloomsbury BBM1 and BBM2 types, dated to 1836 and 1813-1842 respectively. WASR5 appears to be slightly later than the Bloomsbury examples, as a copper alloy safety pin was recovered grave fill (1/09).

The five examples of this grip type were associated exclusively with SK5.

- WASR6

Rectangular, square-cut cast iron grip, with central bulbous section and no visible decoration. This design shows some similarities to the grip style OXTHPL1 recovered at St Clement's, Oxford and dated to the late 18th-early 19th century (Webb 2007).

Two of the recovered examples were associated with SK83, while a single grip was found with SK64. The remaining 4 items were not related to burials.

- WASR7 (SF13, Plate 10)

This type is represented by a single, unstratified cast iron grip. The curved-cut item presented a symmetrical, floral decoration in the centre and was painted black. No reference for this grip design was found, and the object remains undated.

Generally, a single grip style was recorded for each individual coffin, with the notable exception of the coffin for SK36. The recovered metalwork for coffin (9/11) comprised 83 fasteners, 305 upholstery studs, a *depositum* plate and 12 grips of two different styles (WASR2 and WASR4), making it the most elaborately decorated among the Wargrave coffins.

Fasteners

Iron fasteners were the most common find at St Mary's, with 262 examples found in association with 29 graves. With the exception of SK81, where a single nail was not found to be associated with any other metalwork or wood stain, and might therefore be residual, the presence of fasteners in combination with other elements confirmed the existence of coffins for 28 of the burials.

The advanced oxidation of the material prevented from the observation of manufacturing details for a considerable part of the assemblage; however, basic features like cross-section and head type were recorded where visible.

Two different types of fasteners were registered; the vast majority (254 objects, or 97%) of the collection was identified as general purpose nails with a rectangular cross-section, and either flat round or T-heads, generally dated to the 19th century. The remaining 9 items were found to be joiner's dogs.

The quantity of fasteners associated with individual burials varied between 1 (SK50) and 83 (SK36) items; however, it is highly probable that recovery of nails during excavation was not complete, and may account for the wide variation between the number of nails found in different graves. It is possible, of course, that joinery or wooden pegs rather than nailing was used to secure the planks of the coffin, and nails only used to secure the lid (Boston 2006).

Discussion

The Wargrave coffin furniture assemblage seems to generally conform to the trends registered for many other contemporary burial grounds. The material recovered has several parallels with collections from various sites across Southern England, with the minor variations in style probably representing different (possibly local) centres of production.

A notable characteristic of the assemblage found at St Mary's is the general absence of *depositum* plates. The widespread use of deposition plates starts after the 1750s; previously, from the late 17th to the mid-18th C the studs on the coffin lid were used to spell the initials, age and date of death of the buried individual (Bashford 2003), which could either suggest a generally earlier date for the Wargrave assemblage, or a generally lower level of income of the local population.



Plate 9. Upholstery studs




Plate 10. Wargrave grips type WASR1 and WASR7

WASR4, Coffin (9/11), SK36



SF2



SF10



SF14

Plate 11. Wargrave grip type WASR4

WASR5, SF12, Coffin 1/10, SK5



Plate 12. Wargrave grip type WASR5

Grave fill (13/57), SK82



Plate 13. Pocket watch and seal

SF5, Coffin fill (2/24), SK20



Plate 14. Tombac buttons

Table 23: Coffin remains by burial

Skeleton	Coffin	Grave Fill	Wood remains/traces	Coffin shape	Fastener	Upholstery Stud	Grip Plate	Grip	Grip Type	Plate Fragments	Undetermined	Small Find No.
SK1	1/06		Left side panel	Rectangular	4					8		
SK2	2/14		Floor panel, lower right side panel	Single break	3	12				10	3	
		2/09					1					3
SK3		3/08		Undetermined	3							
SK4	10/07		Floor panel	Single break	7	1		1	WASR3	1	1	
SK5	1/10		Lid	?Single break				7	WASR5			SF12
SK6	2/13		Floor panel, lower side panels	Single break	4							
SK7	3/11		Floor panel	Undetermined	9		1	2	WASR1	1	3	
SK9	10/12			Undetermined	5							
SK15	2/23			Single break	1	7	1		WASR2	14	3	SF3
		2/22			2	3					1	
SK16		12/03		Undetermined		10						
SK17		12/05		Undetermined	4							
SK18	12/08		Lid	Undetermined	14	45		3	WASR2	7	1	
	12/07											
SK20		2/26		?Single break	6	8					10	
SK24		1/13	Floor panel	?Single break	7					2	1	
SK29	12/17		Lid, lower side panels	?Single break	11	12	1	3	WASR3	69	3	
SK30	12/20		Lower side panels	?Single break	2	24	1	1	WASR1			SF6, SF7
SK36	9/11			Single break	83	305	8	4	WASR1, WASR2, WASR4	204	75	SF2, SF10, SF14
		9/10										
SK37		13/17		?Single break	5				WASR1		1	
SK38	13/07		Floor panel	Single break				3				
SK43	12/25		Head piece, upper side panels	Rectangular				1		7		
SK44	12/28		Lid	?Single break	9	18						
SK50	12/34			Single break	1	1	1	1	WASR2	1		
SK55	13/28			?Single break	2	1	1		WASR1	5		SF1

Skeleton	Coffin	Grave Fill	Wood remains/traces	Coffin shape	Fastener	Upholstery Stud	Grip Plate	Grip	Grip Type	Plate Fragments	Undetermined	Small Find No.
SK58	13/27			?Single break			1		WASR1			
		13/22				2						
SK60	3/31		Floor panel	Undetermined	4	3	1	2	WASR2	73	2	
SK61	9/14			Undetermined	2	5						
SK62	8/04		Lower left side panel	?Rectangular	2	4		5	WASR2	28		
SK63	9/17			Undetermined	7	1					1	
SK64	13/45		Lower left side panel	?Single break		1		1	WASR6			
SK67		13/38		Undetermined	1						1	
SK68	13/41		Floor panel	Single break								
SK70	13/36		Floor panel	Single break		14						SF15
SK72	5/06		Lower side panels	Single break	4	15				8	2	
SK73	6/08			Undetermined	16	53				111	32	
SK82	13/58		Undetermined fragment	?Single break	1		2	2	WASR2	2		
SK83	6/20			?Rectangular		2	2	1	WASR6	4		
SK84	11/07		Floor panel	Undetermined								
SK86		11/10		Undetermined	2	1						
SK87	13/61		Floor panel	?Single break								
SK89	13/66		Upper right side panel	?Single break								
SK91	13/71		Head piece, upper left side panel	Single break								
N/A	6/23		Head piece, upper left side panel	Undetermined								
N/A	12/43		Undetermined fragment	Undetermined								

Bibliography

- Advisory Panel on the Archaeology of Burial in England, 2017 *Guidance for Best Practice for the Treatment of Human Remains Excavated from Christian Burial Grounds in England*.
- Aultman, J. and Grillo, K. 2003 *DAACS Cataloging Manual: Buttons*
- Bailey, G. 1993 *Detector Finds 2*. Greenlight Publishing, Witham
- Bailey, G. 2004 *Buttons & Fasteners 500BC-AD1840*. Greenlight Publishing, Witham
- Bashford, L. and Sibun, L. 2007, Excavations at the Quaker Burial Ground, Kingston-upon-Thames, London, in *Post-Medieval Archaeology* **41/1**:100-154
- Boston, C., Boyle, A. and Witkin, A. 2006, *In the vaults beneath – Archaeological Recording at St George's Church, Bloomsbury*. Oxford Archaeology
- Boston, C. 2008, *Rycote Chapel. Coffins in the Crypt*. *Archaeological Watching Brief Report*, Oxford Archaeology Report No. 3777
- Brickley, M, & McKinley, J I, 2004 *Guidelines to the Standard for Recording Human Remains*. Institute of Field Archaeologists Technical Paper 7, BABAO University of Southampton
- Clough, S. 2010 The coffins and coffin furniture, in McCarthy R, Clough S, Norton A, Excavations at the Baptist Chapel Burial Ground, Littlemore, Oxford. Archaeological excavation report
- Cox, M. 1996 *Life and Death in Spitalfields 1700–1850*, York: CBA
- Cox, M, 2001 *Crypt Archaeology: an approach*. Institute of Field Archaeologists Technical Paper 7. Reading
- Cox, A. 1996a Post-medieval dress accessories from recent urban excavations in Scotland, Tayside and Fife *Archaeological Journal*, vol. 2
- Ives, R. and Hogg, I. 2012 *St John's School, Peel Grove, Bethnal Green, London Borough of Tower Hamlets: A Post-Excavation Assessment Report*. AOC Archaeology Group
- Janaway, R. 1998 An introductory guide to textiles from 18th and 19th century burials, in Cox, M. (ed), *Grave Concerns: death and burial in England, 1700-1850*, CBA Research Report 113
- Litten, J. 1991 *The English way of death - the common funeral since 1450*, Robert Hale, London
- McCarthy, R., Clough, S. and Norton, A. 2012 The Baptist Chapel burial ground, Littlemore, Oxford. *Post-Medieval Archaeology* **46/2**

Miles, A. 2008 Coffins, in Cowie R, Bekvalac J and Kausmally T, Late 17th- to 19th-century burial and earlier occupation at All Saints, Chelsea Old Church, Royal Borough of Kensington and Chelsea. MOLAs Archaeology Studies Series 18

McKinley, J, & Roberts, C, 1993 *Excavation and post-excavation treatment of cremated and inhumed human remains*. Institute of Field Archaeologists Technical Paper 13

Reeve, J. and Adams, M. 1993, *The Spitalfields Project: Across the Styx. Volume 1: the archaeology*. CBA Research report 85. Council for British Archaeology
Richmond, M. 2007 The Coffin furniture, in Bashford, L, Sibun, L Excavations at the Quacker Burial Ground, Kingston-upon-Thames, London. *Post-Medieval Archaeology* **41/1**

Rugg, J. 1999 From reason to regulation: 1760-1850, in Jupp, P, and Gittings, C (eds) *Death in England- an illustrated history*, Manchester University Press

Seetah, K. 2009 *The importance of cut placement and implement signatures to butchery interpretation*
(http://www.alexandriaarchive.org/bonecommons/archive/files/archivefiles_download_seetah_textimages_204_7cd9b26908.pdf accessed 30/09/2015)

Webb, H. 2007 St Clement's churchyard, The Plain, Oxford. *Oxford Archaeology Report No. 3782*

APPENDIX 3: Coffins catalogue

Coffins catalogue

by *Simona Denis*

Rectangular coffins:

1. Coffin (1/07), SK1: wood stains from the left side panel, with fasteners and plate fragments.
2. Coffin (12/25), SK43: partially preserved wood from head piece and both upper side panels. Single grip and plate fragments recovered from head piece and right upper side panel, too corroded for the type to be identified.
3. Coffin (6/20), SK83 (L18th–E19th C): possibly rectangular, although no traces of decayed wood were observed. Two WASR6 and an additional grip of undetermined type recovered from head piece and both upper side panels. No fasteners were collected. The presence of 2 studs might be intrusive.
4. Coffin (8/04), SK62 (E-M19th C): partially preserved wood from left side panel. Five WARS2 grips were collected from the right side panel and from lower left side panel. 2 nails were found *in situ* in the right corner of the head piece.

Single break coffins:

1. Coffin (2/14) SK2 (18th-19thC): wood stains from lower right side panel. 3 nails and 10 fragments of plate recovered, as well as 10 upholstery studs, some of which preserved the original black laquer.
2. Coffin (10/07), SK4 (M-L19th C): wood stains from the floor panel, with 7 nails. A single grip WASR3 was recovered, with a single fragment of plate and one stud, possibly intrusive.
3. Coffin (1/10), SK5 (M-L19th C): moderately preserved coffin wood from lower side and floor panel; lid fragments collapsed on feet and left arm. Seven WASR5 (SF12) grip plates recovered, attached to wooden planks fragments ranging in size from 270x190mm to 590x230mm. Possibly held together by joinery or wooden pegs, as no fasteners were collected.
4. Coffin (2/13) SK6: wood stains from lower side panels and foot piece observed. Of the four nails recovered, 2 were found *in situ* along the lower left side panel, at the junction with the floor panel.
5. Coffin (2/23) SK15 (E-M19th C): no traces of coffin wood were observed, although 2 grip plates were found *in situ*, from the foot piece and the lower right side panel; the only recovered grip was of the WASR2 type, bearing traces of the original black laquer. 3 nails were also found, as well as 10 upholstery pins, 1 of which (SF3) was mate of copper alloy.
6. Coffin (2/26), SK20 (18th C): no traces of decayed wood were noted, although 6 nails were recovered, 5 of which *in situ* along the juncture of both lower side panels with the floor panel. 8 studs were also collected. 10 additional items were too corroded to be identified; these might represent additional nails or studs.
7. Coffin (1/13), SK24: wood stains from the floor panel were observed, and two small fragments of coffin wood, weighing 4.1g in total, were recovered from the grave fill (1/14). 7 nails were also found, as well as two plate fragments, possibly intrusive as no grip was recovered.
8. Coffin (12/17), SK29 (M-L19th C): lower side panels and foot piece partially preserved as wood stains. Four WASR3 grips recovered, including one example with partial grip plate, and a second example preserving traces of the original black laquer. A relatively large quantity of grip plate fragments (69,

- weighing 365g) could possibly indicate the presence of a breastplate or lid motifs, too corroded to be identified.
9. Coffin (12/20), SK30 (L18th-E19th C): left side panel partially visible as wood stains, and small fragments of coffin wood with fitted studs preserved. One WASR1 grip plate and an additional grip of undetermined type were found, as well as 2 nails. 24 copper alloy upholstery studs (SF6 and SF7), of two different sizes, were also recovered, partially *in situ* over the upper torso area and lower left side panel; no pattern was recognised.
 10. Coffin (9/11), SK36 (L18th-M19th C): wood not preserved. Extremely elaborated coffin furniture set, including 10 WASR4 grip plates (SF2, SF10, SF14) and 2 additional WASR2 grips, recovered from head and foot pieces, and both side panels. All of the grips preserved traces of the original black laquer. 83 fasteners (including 4 joiner's dogs) were also found, as well as 305 upholstery studs, a number of which were found lined along the lower right side panel, and included some examples with black laquer. A severely corroded breastplate of undetermined type, was also recorded; traces of degraded upholstery textile visible under breast plate fragments. 45 additional plate fragments could represent *escutcheons* or lid motifs. Two WASR1 grip plates were also found in the grave fill (9/10), but these were considered to be possibly intrusive.
 11. Coffin (13/17), SK37: wood not preserved; 5 fasteners, including one joiner's dog, were recovered, together with a single, possibly intrusive plate fragment.
 12. Coffin (13/07), SK38 (L18th-E19th C): coffin wood held together by joinery or wooden pegs, as no fasteners were recovered. However, the presence of the coffin is confirmed by 3 WASR1 grip plates found in situ, along the left side panel and the lower right side panel.
 13. Coffin (12/28), SK44 (18th-19thC): fragment of wood from lid recovered in the feet area; 9 nails and 18 upholstery pins were also found, indicating the coffin was originally covered in fabric.
 14. Coffin (12/34), SK50 (E-M19th C): no traces of coffin wood were observed. 2 WASR2 grips were found in the head piece area, one of which preserved fragments of its grip plate. One additional plate fragment was recovered, and a single nail. One iron stud was also found fused to the skeleton's left humerus.
 15. Coffin (13/28), SK55 (L18th-M19th C): wood not preserved. A single WASR1 grip was recovered (SF1), possibly from the head piece or the left side panel. Two nails and a single upholstery stud were also collected. An extremely oxidised, fragmentary plate with two fitting pins was tentatively identified as an *escutcheon* or lid motif.
 16. Coffin (13/27), SK58 (L18th-M19th C): no traces of coffin wood were observed. A single WASR1 grip plate from the lower left side panel was found; no fasteners were present. One iron and one copper alloy upholstery studs were also recovered.
 17. Coffin (13/45), SK64 (L18th-E19th C): lower left side panel partially preserved; wood stains from the floor panel were also recorded. One WASR6 grip was found in the upper left side panel area. A single stud fused to the skeletal remains was also observed.
 18. Coffin (13/41), SK68: represented exclusively by the wood stain from the floor panel. The absence of metalwork suggests a very simple coffin held together by joinery or wood pegs.

19. Coffin (13/36), SK70 (18th-19thC): wood stains from floor panel visible in the head area. A group of 14 copper alloy studs (SF15) was recovered from the head area as well, but no specific pattern was recognised.
20. Coffin (5/06), SK72 (18th-19thC): wood stains from lower side and floor panel recorded. 4 nails and 15 upholstery studs also present; the small quantity of plate fragments originated from the foot grip plate, but no associated grip was recovered.
21. Coffin (13/58), SK82 (E-M19th C): no traces of coffin wood were observed. Four WASR2 grips were recovered, of which 2 with partial grip plates, from both lower side panels. Two additional plate fragments and a single nail were also found.
22. Coffin (13/61), SK87: represented exclusively by the wood stain from the floor panel. The absence of metalwork suggests a very simple coffin held together by joinery or wood pegs.
23. Coffin (13/66), SK89: partially preserved head piece and upper right side panel. The lack of metalwork suggested this was a plain coffin, held together by joinery or wooden pegs.
24. Coffin (13/71), SK91: coffin wood from head piece and upper and left side panel preserved. No associated metalwork was recovered.

Coffins of undetermined type:

1. Coffin (3/07), SK3: no wood stains observed; 3 nails found in grave fill (3/08).
2. Coffin (3/11), SK7 (L18th-E19th C): wood stains from floor panel recorded. A single WASR1 grip plate was recovered, as well as two additional grips, too corroded for any observation. 9 nails were present, as well as single plate fragment.
3. Coffin (10/12), SK9: very limited wood stains from floor panel observed. 5 nails were recovered in situ, three of which along the juncture of the floor panel and the right side panel. The remaining 2 examples were found on the juncture of the left side and the floor panels.
4. SK16 (18th-19thC): no wood remains were recorded; however, grave fill (12/03) yielded a group of 10 iron upholstery studs, suggesting the presence of a decorated coffin.
5. SK17: no traces of coffin wood were observed. 4 nails were collected from grave fill (12/05).
6. Coffin (12/08), SK18 (E-M19th C): single coffin lid fragment observed. Three WASR2 grips were also recovered, as well as a small quantity of plate fragments. 14 fasteners, including a single joiner's dog, were also found. The coffin was originally covered in fabric, as confirmed by the presence of 45 upholstery pins.
7. Coffin (3/31), SK60 (E-M19th C): wood stains from floor panel present. Two WASR2 grips were recovered, along with a fairly large quantity of plate fragments, possibly from lid motifs or a breastplate, the presence of which was suggested by the rust residues observed on the skeleton's lumbar vertebrae. 3 upholstery studs and 4 fasteners, including one joiner's dog, were also found.
8. Coffin (9/14), SK61 (18th-19thC): no coffin wood preserved, although 2 nails and 5 upholstery studs, two of which painted with black laquer, were found. The nails and 2 of the studs were found in situ, at the junction between the floor and upper right side panels.

9. Coffin (9/17), SK63 (18th-19thC): 3 of the 7 recovered nails were found in situ, at the junction of the floor panel and the lower right panel and foot piece. A single stud was also collected, although no wood stains were observed.
10. Coffin (6/08), SK73 (18th-19thC): no wood stains were observed; however, the relatively large assemblage of metalwork recovered indicated the presence of a coffin. 16 nails, 53 upholstery studs, and 111 plate fragments were collected, although no grip was found.
11. Coffin (11/07), SK84: represented exclusively by the decayed floor panel.
12. Coffin (11/13), SK86 (18th-19thC): no wood stain detected. Two nails recovered from grave fill (11/10) suggested the presence of a coffin.
13. Coffin (6/23), unexcavated. Upper left side panel and head piece stains observed. No associated metalwork was recovered.
14. Coffin (12/43), unexcavated. Wood stain recorded.

Residual metalwork

1. SK67: a single nail and one additional, unidentified metal object were collected from grave fill (13/38). No traces of decayed wood were recorded. This burial was severely truncated, and the iron items might be residual.
2. SK81: a single nail was found in grave fill (13/55). As no traces of decayed wood were recorded, the material might be residual.

APPENDIX 4: Osteological Catalogue

Skeleton	Preservation	Completeness	Age (y)	Sex	Stature (any long bones)	Stature (femur only)	Activity-related Changes and build	Skeletal Pathology	Dental Pathology
1	2	3	50+	Male	169	169	Fairly gracile skeleton with moderate to marked muscle insertions	R hand PP fracture; R maxillary sinusitis; generalised slight DJD	AMTL ++; caries ++; periodontal disease +; DEH +; unerupted canine
2	1	1	>18	Adult			Fairly robust- tentatively male	R talus Shepherd's fracture; R calcaneus fracture; L & R tibia and fibula tertiary syphilis; generalised marginal OP	No teeth or jaws present
3	1	3	50-60	Male	177		Marked enthesal changes- boneformer	T7-9 vertebral crush fractures; L rib x 1 fracture; T7-11 probable DISH; SDJD & OA; Schmorl's nodes	AMTL +++; periapical abscess ++; edentulous
4	1	4	20-30	Female			Gracile build	R acromioclavicular joint slight DJD; Schmorl's nodes	Caries; DEH +; periodontal disease +; impacted M3
5	1	3	30-40	Probable female				L MT1 marginal cysts & erosion ? gout; Schmorl's nodes	No teeth or jaws present
6	1	1	>18	Possible male			Fairly robust with marked muscle attachments; enthesal change to distal fibula suggests ankle sprain	Minor generalised joint lipping (DJD)	No teeth or jaws present
7	1	4	40-50	Male	163	163	Marked muscle attachments to upper limbs; robust skeleton	L & R nasal bones, R MC3 & 5, rib x 1 fractures; L & R talus Shepherd's fractures; L acetabulum ? crush fracture; ectocranial orange peel porosity, L & R tibia & fibula periostitis ? scurvy; rib periostitis; ivory osteoma; sacroiliac ankylosis; Schmorl's nodes	AMTL ++; caries ++; calculus ++; periapical abscess ++
8	1	4	30-40	Female			Gracile but insertions in upper limb bones moderately defined	Pregnancy (older mother); L maxillary sinusitis; ectocranial orange peel porosity, orbital lesions ? scurvy; R temporal bone Eagle's syndrome; Schmorl's nodes	Marked dental disease; AMTL ++; caries +++; calculus ++; periapical abscess ++

Skeleton	Preservation	Completeness	Age (y)	Sex	Stature (any long bones)	Stature (femur only)	Activity-related Changes and build	Skeletal Pathology	Dental Pathology
9	2	4	60+	Male	174	174	Enteseal changes in upper limbs marked; lower limbs moderate; fairly robust	TV x 4 & LV x 1 wedge fracture; LV OA; widespread DJD; Schmorl's nodes	AMTL
10	1	3	45-60	Male			Marked enteseal changes to upper and lower limbs, especially proximal femora	R orbit lesion, ectocranial orange-peel porosity ?? healed scurvy; R MC3 fracture; multiple marked muscle attachments-boneformer; SDJD & ESDJD; Schmorl's nodes	AMTL & alveolar recession +++
12	2	1	>18	Adult			Not marked	R femoral condyle and patella eburnation +++ OA; R tibia healed periostitis	No teeth or jaws present
13	2	1	>18	Adult			Radial tuberosity shows moderate enteseal changes (Biceps brachii insertion); humeral & ulnar insertions not defined	Nil noted	No teeth or jaws present
13	1	1	>18	Adult			Not marked; moderate build	Nil noted	No teeth or jaws present
14	1	2	24-26 w fetus	Non-adult	0		Not defined- non-adult	Nil noted	No teeth or jaws present.
15	1	1	>18	Adult			Fairly gracile skeleton without marked muscle insertion sites- ?? female	Nil noted	No teeth or jaws present
16	1	1	>18	Adult			Not marked	R tibia & fibula slight rickets; R tibia & fibula well healed periostitis	No teeth or jaws present
17	1	2	5-7	Non-adult			Child- entheses not defined	L Rib x 2, R Rib 1 & R clavicle new bone & abscess probable active TB	Deciduous teeth caries ++; permanent teeth NAD
18	3	2	>45	Female			Gracile skeleton	R clavicle healing fracture; CV spondylosis, SDJD	AMTL+++; caries; alveolar recession ++
19	2	1	>16	Adult			Gracile elements- possibly female	R elbow & wrist slight marginal OP	No teeth or jaws noted
20	1	1	>16	Adult			Not marked, very gracile skeleton	L & R tibia healed periostitis	No teeth or jaws present

Skeleton	Preservation	Completeness	Age (y)	Sex	Stature (any long bones)	Stature (femur only)	Activity-related Changes and build	Skeletal Pathology	Dental Pathology
21	1	1	>18	Adult			Distal fibula showed marked enthesopathy and syndesmosis suggesting soft tissue tear/ ankle sprain	Nil noted	No teeth or jaws present
22	1	1	>18	Adult			Not marked, gracile	L tibia healed periostitis	No teeth or jaws present
23	1	1	>18	Adult			Moderate to robust build; muscle insertions not very marked	Nil noted	No teeth or jaws present
24	2	2	16-20	Adult			Too incomplete to assess; gracile skeleton ?? female	L & R tibia well healed periostitis	No teeth or jaws present
25	1	3	25-35	Male			R costoclavicular syndesmosis pronounced, but muscle insertion sites are not otherwise well defined	L & R os acromiale; extra sacral segment; Schmorl's nodes	Nil noted
26	1	3	35-45	Male			Not particularly marked; fairly robust	Unsided rib fractures x 2; L & R tibia & fibula healed periostitis; L & R tibia slight rickets; L foot MP & PP symphalangism; sacralisation; S5-Cx ankylosis; Schmorl's nodes	No teeth or jaws present
27	1	1	>16	Adult			Not marked muscle insertions, but skeleton very incomplete; moderate build but short stature	L & R tibia & fibula well healed periostitis	No teeth or jaws present
28	2	2	14-16	Female			Not marked; very gracile skeleton	R tibia & fibula healed periostitis	No teeth or jaws present
29	4	1	>16	Adult			Gracile but no enthesal changes noted	Nil noted	No teeth or jaws present
30	3	2	40-45	Male			Muscle insertion sites moderately defined; fairly robust	L acetabulum moderate OP DJD; Schmorl's nodes	No teeth or jaws present
31	4	2	40+	Female			Fairly gracile; enthesal changes not marked	Nil noted	AMTL

Skeleton	Preservation	Completeness	Age (y)	Sex	Stature (any long bones)	Stature (femur only)	Activity-related Changes and build	Skeletal Pathology	Dental Pathology
32	1	1	10	Non-adult			Not marked- non-adult	Nil noted	No teeth and jaws present
33	1	1	>18	Adult			Not marked	R patella healed fracture; R talus Shepherd's fracture; R tibia & fibula healed periostitis	No teeth or jaws present
34	1	3	40+	Male		180	Muscle insertions marked on arms, especially forearms; robust, tall	L acetabulum joint surface fractures; R acetabulum subchondral cysts & large supra-acetabular cyst ? labral tear; L hand PP2 & MP2 ankylosis; L5 crush fracture; SDJD & ESDJD; L & R ribs healed periostitis; Schmorl's nodes	No teeth or jaws present
35	2	1	>18	Adult			Too incomplete to assess; Soleal line moderately defined	R tibia and fibula healed periostitis	No teeth or jaws present
36	2	5	45-55	Female			Gracile skeleton but muscle attachments on the arm & hand phalanges very defined, & enthesal changes at the Achilles tendon insertion on calcaneus	R acetabulum massive erosive lesion ? septic arthritis/ TB/ neoplasm; L & R tibia, L femur healed periostitis; L tibial plateau abnormal morphology; Schmorl's nodes	AMTL; caries, calculus; periapical abscess; alveolar recession
37	1	2	50+	Probable male			Few landmarks available; robust individual	R Rib x 1 & unsided rib x 1 healed fractures; SDJD OP+++; T1-3 ? ligamentous damage to spinous processes; Schmorl's nodes	No teeth or jaws present
38	1	4	50+	Male			Robust individual with marked muscle insertions, especially of the upper limb	L & R ribs x 13 fractures; CV6, 7 & T1 spinous process fractures; T1 body fracture; L & R acetabulum fractures; R wrist & vertebrae OA; generalised DJD & SDJD; parietal & occipital bones ectocranial orange peel porosity; boneformer; Schmorl's nodes	AMTL with marked alveolar recession; no teeth present

Skeleton	Preservation	Completeness	Age (y)	Sex	Stature (any long bones)	Stature (femur only)	Activity-related Changes and build	Skeletal Pathology	Dental Pathology
39	2	2	35-45	Female			Moderate to marked enthesal changes	R femur possible healing shaft fracture; coccyx ankylosed to S5; Schmorl's nodes	No teeth or jaws present
40	1	3	9-11	Non-adult			Not possible to assess	Growth stunted (long bone age 7 years; dental age 9-11 y); Schmorl's nodes	Severe DEH; caries ++; periapical abscess
42	1	1	>21	Adult			Too incomplete to assess	TV OA; TV Schmorl's nodes	No teeth and jaws present
43	2	1	>18	Female			Too incomplete to assess	Nil noted	No teeth or jaws present
44	1	1	>18	Adult			Not marked	L talus Shepherd's fracture; L & R tibia healed periostitis	No teeth or jaws present
45	1	2	6-8	Non-adult			Not marked- non-adult	Schmorl's nodes	Permanent teeth: no pathology noted; deciduous teeth caries, calculus.
47	1	1	>18	Adult			Marked Soleal line but otherwise muscle insertions are not marked	R tibia well healed periostitis	No teeth or jaws present
48	1	2	25-35	Female			Gracile skeleton, muscle insertions not defined	Schmorl's nodes	No teeth or jaws present
50	1	3	45+	Male			Very pronounced muscle insertions & cartilage ossification	L parietal bone sharp force trauma; CV & TV & acromioclavicular joints OA; ESDJD; T6-8 fusion, boneformer, DISH; L & R rib healed periostitis; Schmorl's nodes	Caries ++; AMTL++; calculus ++
51	2	3	35-45	Male			Marked enthesal changes on lower limb long bones	L & R tibia, MTs healed periostitis; Schmorl's nodes	No teeth or jaws present
52	1	1	>18	Male			Too incomplete to assess	Nil noted	Pipe notch; extramasticatory wear; DEH ++
53	1	3	20-25	Female			The coronoid process of the clavicles pronounced; otherwise, muscle insertions not defined	L femur healed periostitis ; R tibia healed periostitis ?? scurvy; Schmorl's nodes	Periodontal disease ++; calculus +.






Skeleton	Preservation	Completeness	Age (y)	Sex	Stature (any long bones)	Stature (femur only)	Activity-related Changes and build	Skeletal Pathology	Dental Pathology
54	1	3	40-50	Male			R clavicle moderate soft tissue trauma; moderate to gracile build	L ilium Sprinter's avulsion fracture; L ilium probable soft tissue trauma; L & R acetabula subchondral cysts- ? labral tearing; R MC3 styloid fracture; L & R tibia & fibula & L ulna well healed periostitis; DJD; Schmorl's nodes	No teeth or jaws present
55	1	2	45+	Female			Gracile skeleton, but marked muscle and ligament insertions on the L clavicle & proximal humerus (including Supraspinatus enthesopathy ++)	L & R maxilla chronic sinusitis; ectocranial orange-peel porosity, posterior maxilla new bone probable healed scurvy; Schmorl's node; slight SDJD	AMTL; periapical abscess; calculus ++
56	3	2	25-35	Probable male			Fairly gracile skeleton, like several in TP10 (? family of gracile, short people)	L6 sacralisation	No teeth or jaws present
57	2	1	25-35	Female			Not marked; medium build	Nil noted	No teeth or jaws present
58	2	3	35-45	Probable male			Moderate to marked muscle attachments on upper limb and femur; medium build	Ossified bone spheres - probable calculi (e.g. gall, bladder or renal stones) or ossified soft tissue; Schmorl's nodes	No teeth or jaws present
59	2	5	60+	Female			Marked muscle attachments on multiple elements, especially humeri & iliac crests	L talus Shepherd's fracture; L & R femur, tibia & fibula healed periostitis, L orbit lesion, posterior maxilla new bone ? healed scurvy; frontal bone hyperostosis frontalis interna; Schmorl's nodes	Caries ++; AMTL ++; calculus ++; periapical abscesses ++; pipe notch
60	2	4	40-50	Probable male			Much more robust than other males from Wargrave; muscle attachments to upper limb marked	Extra sacral segment, LV x 5; tibia healed periostitis; T7 kissing spine; frontal bone ivory osteoma; LV & TV Schmorl's nodes; generalised DJD	Largely edentulous bar anterior mandibular sockets; AMTL++; no teeth present; marked alveolar recession.
61	1	1	>15	Adult			Not marked	Nil noted	No teeth or jaws present






Skeleton	Preservation	Completeness	Age (y)	Sex	Stature (any long bones)	Stature (femur only)	Activity-related Changes and build	Skeletal Pathology	Dental Pathology
62	2	4	25-35	Male			Muscle insertions on humeri marked, costoclavicular syndesmoses slight	R Rib 1 fracture; R MC3 fracture; R capitate fracture; L & R femur, R tibia periostitis, ectocranial orange peel porosity ? healed scurvy; Schmorl's nodes	Calculus ++, otherwise good dental health
64	1	3	25-30	Male			Very robust with moderate muscle definition	L femur & tibia osteochondritis dissecans of knee joint; L scapula os acromiale; L tibia & fibula healed periostitis; Schmorl's nodes	No teeth or jaws present
65	1	1	30-45	Probable male			Not marked; large dimensions	R acetabulum possible labral tear	No teeth or jaws present
66	2	2	60+	Male			Marked muscle insertions of Biceps brachii & on R femur & pelvis	L & R hip dysplasia & severe OA; L 4-S1 spondylosis; slight SDJD; Schmorl's nodes	No teeth or jaws present
67	1	2	>20	Possible male			Marked humeral muscle insertions with rotator cuff, flexor and extensor muscle insertion enthesal changes	R humerus osteondritis dissecans; R humeral transcolumar fracture; CV & TV OA and DJD; L acetabulum DJD; L scapula os acromiale; Schmorl's nodes	AMTL
68	1	4	5-7	Non-adult			Non-adult- not defined	Slightly growth stunted	Permanent teeth: nil noted; deciduous teeth: caries
69	1	2	>18	Adult			Moderately well defined muscle attachments; medium to robust build	Nil noted	No teeth or jaws present
70	2	3	40+	Male			Fairly well defined muscle insertion sites on upper limbs; moderate build	CV spondylosis & ankylosis of C4 & 5; TV & R acromioclavicular joint DJD	Very marked dental attrition- more typical of medieval or Saxon period/ extramasticatory wear
71	1	1	>18	Adult			Marked enthesal changes to deltoid tuberosity, medial & lateral condyles; marked hyperflexion of the elbow joint	L acromioclavicular & shoulder joint slight DJD	No teeth or jaws present





Skeleton	Preservation	Completeness	Age (y)	Sex	Stature (any long bones)	Stature (femur only)	Activity-related Changes and build	Skeletal Pathology	Dental Pathology
72	1	1	>18	Adult			Not marked	L & R tibia healed periostitis	No teeth or jaws present
73	1	3	60+	Male			Marked enthesal changes on multiple elements (? boneformer)	Rib fractures x 6; L MC3 styloid incomplete fracture; SDJD; ESDJD; boneformer; Schmorl's nodes	AMTL; periodontal disease; calculus; caries; periapical abscess ++
74	2	2	17-19	Possible male			Not marked- very young adult; gracile to medium build	Occiput endocranial new bone; rib periostitis x 1; Schmorl's nodes	Healthy teeth but worn for age- possibly medieval or Saxon date
75	1	2	60+	Male			Very robust skeleton with marked muscle insertions (bone former)	T7-10 ankylosis, boneformer- DISH; Schmorl's nodes	No teeth or jaws present
76	3	3	40-50	Possible male			Gracile skeleton with only slight muscle insertion definition.	Occiput healing endocranial new bone; Schmorl's nodes	Caries +++; periodontal disease +
77	1	4	25-35	Probable male			Moderate build with fairly defined muscle insertions	L femur, L & R tibia & fibula healed periostitis, ectocranial orange peel porosity, ? scurvy; Schmorl's nodes	No teeth or jaws present
78	2	2	25-30	Male			Medium build; muscle attachments are not very marked	Schmorl's nodes	No teeth or jaws present
79	1	2	16-25	Female			Medium build (quite large & tall for a female); muscle attachments not prominent	R femur, tibia & fibula healed periostitis; R fibula active periostitis; Schmorl's nodes	No teeth or jaws present
80	1	1	>18	Adult			Medium build; muscle insertion sites not very marked; L tibia possible anterior cruciate ligament syndesmosis	L tibia & fibula healed periostitis; L tibia active periostitis, ? abscess	No teeth or jaws present
81	1	4	30-35	Female			Gracile skeleton with very little muscle definition	R acromioclavicular joint , R lunate OA; Schmorl's nodes	Calculus; caries; pipe notch
82	3	4	60+	Probable male			Fairly defined muscle attachments; robust build	R femur intertrochanteric fracture; L & R tibia & L fibula healed periostitis; ectocranial lesion ?? caries sicca of syphilis; endocranial new bone; orbital lesions; frontal sinusitis; <u>possible</u> ankylosing spondylitis	AMTL with marked maxillary recession; caries; calculus






Skeleton	Preservation	Completeness	Age (y)	Sex	Stature (any long bones)	Stature (femur only)	Activity-related Changes and build	Skeletal Pathology	Dental Pathology
83	2	3	60+	Female			Gracile skeleton; moderate muscle insertions of upper limbs; elbow hyperflexion	T5 & T7 wedge fractures with associated OP (? osteoporosis); R elbow, R hip OA; R maxillary sinusitis; Schmorl's nodes	AMTL; calculus +++
84	1	2	40+	Female			Not marked, but skeleton is very incomplete	R maxilla sinusitis; CV, R acromioclavicular joint slight DJD	AMTL with marked alveolar recession; calculus
85	1	1	>18	Male			Too incomplete to assess	L & R nasal bones & R zygomatic arch fractures; R maxilla & L frontal bone sharp force trauma; ectocranial orange peel porosity possible scurvy	AMTL +++- edentulous
86	2	1	>18	Adult			Robust skeleton with moderately pronounced Soleal lines	Nil noted	No teeth or jaws present
87	1	2	>18	Male			Moderate build, fairly well defined muscle insertions	L ribs x 3 healed fractures; spinal DJD; Schmorl's nodes	AMTL; calculus +++; periodontal disease
88	1	1	>20	Adult			Too incomplete to assess; moderate build	L ribs healed periostitis; Schmorl's nodes	No teeth or jaws present
89	1	1	>18	Male			Too incomplete to assess	L concha bulbosa	AMTL ++++; calculus +++
90	2	2	>18	Adult			Moderate to marked enthesal changes to humeri; moderate build	Occipital and L parietal bones ectocranial orange-peel porosity; Schmorl's nodes	No teeth or jaws present
91	3	1	>18	Male			Too incomplete to assess	CV OA; L & R maxillary sinusitis	AMTL+++; periodontal disease +++; periapical abscesses
92	1	1	18	Adult			Moderate to gracile build; hyperflexion of the elbow joint	L ribs healed periostitis	No teeth or jaws present
93	1	1	>18	Adult			Moderate to gracile build; muscle insertions not marked	L ribs healed periostitis; acromioclavicular joint slight DJD	No teeth or jaws present
94	1	1	>18	Adult			Too incomplete to assess; fairly gracile skeleton	Nil noted	No teeth or jaws present






APPENDIX 5:
Burial Photographic Inventory






ID		Grave					Levels (m AOD)		Comments
Skeleton No.	Photo	Trench	Grave Cut	Grave Fill	Coffin	Cranium	Other		
SK1		1	1/04	1/05	1/06				
SK2		2	2/08	2/09	2/14				
SK3		3	3/06	3/08	3/07				
SK4		10	10/06	10/08	10/07				
SK5		1	1/08	1/09	1/10		Pelvis: 116.64 Tarsals: 116.66		






ID		Grave				Levels (m AOD)		
Skeleton No.	Photo	Trench	Grave Cut	Grave Fill	Coffin	Cranium	Other	Comments
SK6		2	2/12	2/10	2/13		Pelvis: 117.03	
SK7		3	3/10	3/12	3/11	117.65	Pelvis: 117.50 Tarsals: 117.49	
SK8		10	10/09	10/10	na	117.21	Pelvis: 117.16	
SK9		10	10/11	10/13	10/12	117.16	Pelvis: 117.19	With SK14
SK10		2	2/16	2/15 & 2/28?	na	117.05	Pelvis: 117.06	






ID			Grave			Levels (m AOD)		
Skeleton No.	Photo	Trench	Grave Cut	Grave Fill	Coffin	Cranium	Other	Comments
SK11	VOID	3	3/13	3/14	na		Left femur: 117.56	VOID Determined to be charnel in post-ex analysis
SK12		2	2/18	2/17	na		Patella: 116.97 Tarsals: 116.97	
SK13		2	2/20	2/19	na		Pelvis: 116.95 Tarsals: 116.97 Humerus: 116.98	
SK14		10	10/11	10/13	10/12			With SK9
SK15		2	2/21	2/22	2/23			





ID		Grave					Levels (m AOD)		
Skeleton No.	Photo	Trench	Grave Cut	Grave Fill	Coffin	Cranium	Other	Comments	
SK16		12	12/04	12/03	na		Tarsals: 117.01		
SK17		12	12/06	12/05	na	116.99			
SK18		12	12/09	12/07	12/08	117.02			
SK19		12	12/11	12/10	na		Ribs: 116.94		
SK20		2	2/25	2/24	2/26		Tarsals: 116.80 Tibia: 116.78		




ID		Grave				Levels (m AOD)		
Skeleton No.	Photo	Trench	Grave Cut	Grave Fill	Coffin	Cranium	Other	Comments
SK21		10	10/18	10/16	na		Tarsals: 117.13	
SK22		10	10/36	10/17	na		Tibia: 117.10 Tarsals : 117.10	
SK23		3	3/16	3/17	na		Radius/Ulna: 117.47	
SK24		1	1/12	1/14	1/13		Femur: 116.58 Tarsals: 116.59	
SK25		10	10/15	10/14	na		Clavicle: 117.06 Pelvis: 117.12 Patella: 117.12	






ID		Grave				Levels (m AOD)		
Skeleton No.	Photo	Trench	Grave Cut	Grave Fill	Coffin	Cranium	Other	Comments
SK26		3	3/19	3/20	3/27		Pelvis: 117.41 Tarsals: 117.40	
SK27		12	12/13	12/12	na		Tarsals: 116.79	
SK28		12	12/15	12/14	na		Tarsals: 116.87 Pelvis: 116.58	
SK29		12	12/18	12/16	12/17		Tarsals: 116.79	Left Foot and leg in shot, Right Foot under coffin plate.
SK30		12	12/21	12/19	12/20		Pelvis: 116.82 Patella: 116.77	






ID		Grave					Levels (m AOD)		
Skeleton No.	Photo	Trench	Grave Cut	Grave Fill	Coffin	Cranium	Other	Comments	
SK31		12	12/23	12/22	na	117.17	Pelvis: 117.17		
SK32		9	9/03	9/04	na		Scapula: 117.30 Pelvis: 117.29		
SK33		3	3/21	3/22	na		Patella: 117.59 Tarsals: 117.52		
SK34		3	3/23	3/24	na		Vertebrae: 117.41 Pelvis: 117.43 Patella: 117.43		
SK35		12	12/40	12/41	na				






ID		Grave					Levels (m AOD)		
Skeleton No.	Photo	Trench	Grave Cut	Grave Fill	Coffin	Cranium	Other	Comments	
SK36		9	9/05	9/10	9/11	117.06	Pelvis: 116.92 Tarsals: 116.89		
SK37		13	13/04	13/05	13/17	117.19	Pelvis: 117.02 Ribs: 117.01		
SK38		13	13/06	13/08	13/07	117.22	Pelvis: 117.15 Patella: 117.15		
SK39		13	13/09	13/10	na		Pelvis: 117.11		
SK40		13	13/11	13/12	na	117.20	Pelvis: 117.15		






ID		Grave				Levels (m AOD)		
Skeleton No.	Photo	Trench	Grave Cut	Grave Fill	Coffin	Cranium	Other	Comments
SK41	VOID	13	13/13	13/14	13/20			VOID – Determined that cut was likely from a mid 20 th century borehole.
SK42		13	13/15	13/16	na		Vertebrae: 117.2	Vertebrae
SK43		12	12/26	12/24	12/25	116.98		
SK44		12	12/29	12/27	12/28		Tarsals: 116.75	Post-exc shot of lower legs (both feet already removed)
SK45		10	10/20	10/19	na	117.10	Pelvis: 117.07	






ID			Grave			Levels (m AOD)		
Skeleton No.	Photo	Trench	Grave Cut	Grave Fill	Coffin	Craium	Other	Comments
SK46	VOID	10	10/32	10/31	na			VOID – Determined to be charnel in post-ex analysis, cut was likely from a mid 20 th century borehole.
SK47		10	10/34	10/38	na		Carpals: 117.15	Right leg
SK48		3	3/26	3/25	na		Vertebrae: 117.36 Pelvis: 117.35 Patella: 117.36	
SK49	VOID	12	12/32	12/31	na			VOID – Determined that cut was likely from a mid 20 th century borehole.
SK50		12	12/35	12/33	12/34	116.95	Clavicle: 116.83	






ID		Grave					Levels (m AOD)		
Skeleton No.	Photo	Trench	Grave Cut	Grave Fill	Coffin	Cranium	Other	Comments	
SK51		10	10/21	10/22	na		Pelvis: 117.01 Tarsals: 117.04		
SK52		10	10/23	10/24	na	117.14			
SK53		10	10/25	10/26	na	117.31	Pelvis: 117.24		
SK54		10	10/27	10/28	na		Pelvis: 117.14 Tarsals: 117.22		
SK55		13	13/19	13/18	13/28	117.16			






ID		Grave			Levels (m AOD)			
Skeleton No.	Photo	Trench	Grave Cut	Grave Fill	Coffin	Cranium	Other	Comments
SK56		10	10/29	10/30	na		Pelvis: 116.89 Tarsals: 116.90	
SK57		13	13/21	13/20	na		Pelvis: 117.08 Vertebrae: 117.08	
SK58		13	13/23	13/22	13/27		Pelvis: 117.86 Vertebrae: 117.07	
SK59		13	13/25	13/24	na	117.06	Pelvis: 116.97 Tarsals: 116.98	
SK60		3	3/29	3/30	3/31	117.17	Pelvis: 117.14 Patella: 117.14	





ID		Grave					Levels (m AOD)		
Skeleton No.	Photo	Trench	Grave Cut	Grave Fill	Coffin	Cranium	Other	Comments	
SK61		9	9/12	9/13	9/14		Carpals: 116.94		
SK62		8	8/05	8/03	8/04	117.08	Pelvis: 116.99 Patella: 117.00		
SK63		9	9/15	9/16	9/17		Tarsals: 117.07	Still missing as of 6.6.18	
SK64		13	13/29	13/30	13/45		Pelvis: 116.98 Tarsals: 116.95		
SK65		9	9/20	9/19	na		Pelvis: 117.02		






ID		Grave					Levels (m AOD)		
Skeleton No.	Photo	Trench	Grave Cut	Grave Fill	Coffin	Cranium	Other	Comments	
SK66		13	13/31	13/32	na		Pelvis: 117.04		
SK67		13	13/37	13/38	na		Vertebrae: 117.29		
SK68		13	13/39	13/40	13/41	117.21	Pelvis: 117.13		
SK69		13	13/43	13/44	na		Patella: 116.98		
SK70		13	13/35	13/42	13/36	116.84	Vertebrae: 116.80	Samples kept for RC dating	

ID			Grave			Levels (m AOD)		
Skeleton No.	Photo	Trench	Grave Cut	Grave Fill	Coffin	Cranium	Other	Comments
SK71		13	13/46	13/47	na		Scapula: 116.86	
SK72		5	5/05	5/04	5/06		Tarsals: 116.92	
SK73		6	6/07	6/09	6/08	117.23	Pelvis: 117.17	
SK74		13	13/50	13/51	na	116.93	Pelvis: 116.89	Samples kept for RC dating
SK75		13	13/52	13/53	na	116.89	Pelvis: 116.92	

ID		Grave					Levels (m AOD)		
Skeleton No.	Photo	Trench	Grave Cut	Grave Fill	Coffin	Cranium	Other	Comments	
SK76		6	6/10	6/11	na	117.31	Pelvis: 117.28		
SK77		6	6/12	6/13	na	117.25	Pelvis: 117.21		
SK78		6	6/14	6/15	na		Pelvis: 117.26 Femur: 117.22		
SK79		6	6/16	6/17	na		Pelvis: 117.31 Tarsals: 117.26		
SK80		11	11/04	11/03	na		Pelvis: 117.22 Tarsals: 117.24		

ID		Grave				Levels (m AOD)		
Skeleton No.	Photo	Trench	Grave Cut	Grave Fill	Coffin	Cranium	Other	Comments
SK81		13	13/54	13/55	na	116.83	Pelvis	
SK82		13	13/56	13/57	13/58	116.82	Pelvis: 116.74	
SK83		6	6/19	6/21	6/20	117.19	Pelvis: 117.07	
SK84		11	11/05	11/06	11/07	117.05		
SK85		11	11/08	11/09	na	117.09		

ID			Grave			Levels (m AOD)		
Skeleton No.	Photo	Trench	Grave Cut	Grave Fill	Coffin	Cranium	Other	Comments
SK86		11	11/11	11/10	na		Tarsals: 116.66 Femur: 116.65	
SK87		13	13/59	13/60	13/61	116.85		
SK88		13	13/62	13/63	na		Ribs: 116.9	
SK89		13	13/64	13/65	13/66	116.90		

ID		Grave					Levels (m AOD)		
Skeleton No.	Photo	Trench	Grave Cut	Grave Fill	Coffin	Cranium	Other	Comments	
SK90		13	13/67	13/68	na	116.90			
SK91		13	13/69	13/70	13/71	116.71			
SK92		13	13/72	13/73	na			Left ribs and arm	
SK93		13	13/74	13/75	na			Left ribs and arm	
SK94		13	13/78	13/79	na		Ribs: 116.96 Femur: 116.74	Left foot Initially numbered as SK102	